

**DATE**

1/24/22

PRESENTING CLINICAL SIGNS

History: p presented 12/27/21 for a decreased appetite. During the exam, a large cranial to mid abdominal mass was palpated. Patient has hyperthyroidism which is currently well controlled.

Current Medications: Methimazole 2.5 mg BID, Mirataz SID PRN.

Lab Results: Lab results 12/10/21 WNL. Attached separately.

Radiographs: Rad review attached.

Date of Previous IntraPet Ultrasound: No previous IntraPet scans.

Sedation: Not required to complete full diagnostic ultrasound.

Stat Report: Not requested.

Imaging Performed By: Rachel Brilhart, RDMS.

PATIENT

Earl Judge

SPECIES

Feline

BREED

Domestic Shorthair

SEX

Neutered male

AGE

8/15/05

WEIGHT

6.75 lbs

INTERPRETED BY

Eric Lindquist, DMV
DABVP, Cert. IVUSS

HOSPITAL NAME

Charm City VH

REFERRING VET

Dr. Eavers

INVOICE

95472

ULTRASONOGRAPHIC EXAMINATION OF THE ABDOMEN**Urinary System**

The **urinary bladder**, trigone, and pelvic urethra presented normal thicknesses and normal tone. The ureters were not visible which is normal. No uroliths or sediment were visualized and anechoic urine was present. No evidence of inflammatory or neoplastic changes was noted. Ureteral papillae were normal.

The **kidneys** revealed largely normal size and structure, corticomedullary definition and ratio (cortex 1/3 of medulla) were essentially maintained with some age-related loss of curvilinear patterns regarding the capsule and C/M junction. The cortices presented largely uniform texture with some increased echogenicity expected for this age patient. Medullary structure differed distinctly from that of the cortex and no evidence of pelvic dilation was present. The right kidney measured 3.63 cm.

Adrenal Glands

Both **adrenal glands** were visualized and recognized as having normal shape, size, position and echogenicity for this breed. The phrenic vasculature, glandular echogenicity and detail were unremarkable. Capsule, cortex, and medullary definition were normal for this age patient.

Spleen

The **spleen** presented a smooth homogeneous parenchyma hyperechoic to liver and renal cortical parenchyma. The capsule was smooth without noticeable expansion or deviation from within the spleen or adjacent pathology. The splenic vasculature demonstrated normal volume without signs of congestion or thrombosis. No sonographic evidence of acute or chronic inflammatory, neoplastic, or infarctual changes was noted.

Liver

The **liver** images submitted revealed subjectively normal liver size, contour, and structure. Parenchymal echogenicity was naturally coarse and hypoechoic to the spleen. Vascular and biliary tracts were of normal volume with no evidence of congestion. The gallbladder presented acceptably thin walls with primarily anechoic content. The cystic and common bile ducts were normal. No pathological hepatic lymphadenopathy was evident. No overt structural evidence of inflammatory, infiltrative or regenerative pathology was evident. Ring down artifact was noted through the diaphragmatic inlet.

Gastrointestinal

The **stomach** and upper gastrointestinal tract was empty and unremarkable. The ileocecal junction revealed a moderately complex mineralized and vascular mass measuring approximately 5.0 cm. The mass was deriving from the distal small intestine. The mass appeared to involve both the intestine and lymph nodes. The mass extended for at least 8.0+ cm as a grouping.

Pancreas

The base and limbs of the **pancreas** were observed to be largely isoechoic to surrounding omental fat. Pancreatic duct and capsular contour were acceptably normal and parenchyma respected normal curvilinear patterns. No overt evidence of active inflammatory or neoplastic disease was noted.

Free Abdomen

Trace amounts of free fluid were noted. Midabdominal enlargement was noted and measured 3.84 x 2.11 cm.

ULTRASONOGRAPHIC FINDINGS

Ileocecal junction mass combined of lymph nodes and intestine.

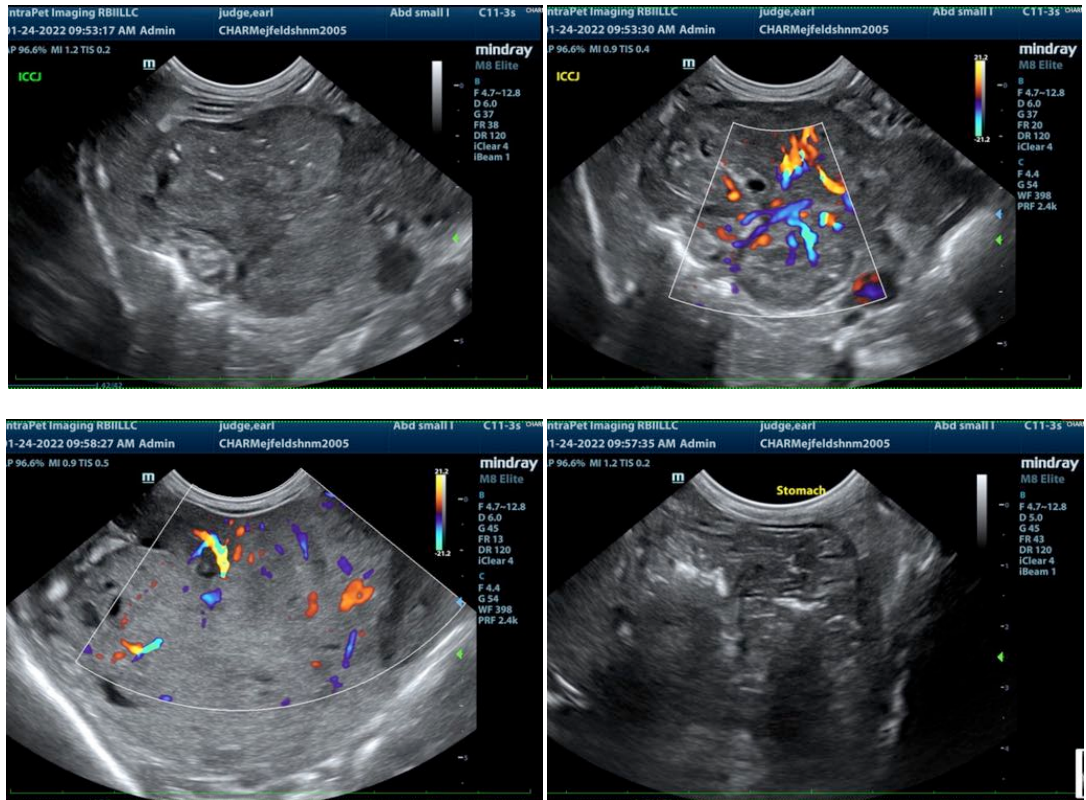
Otherwise, geriatric abdomen.

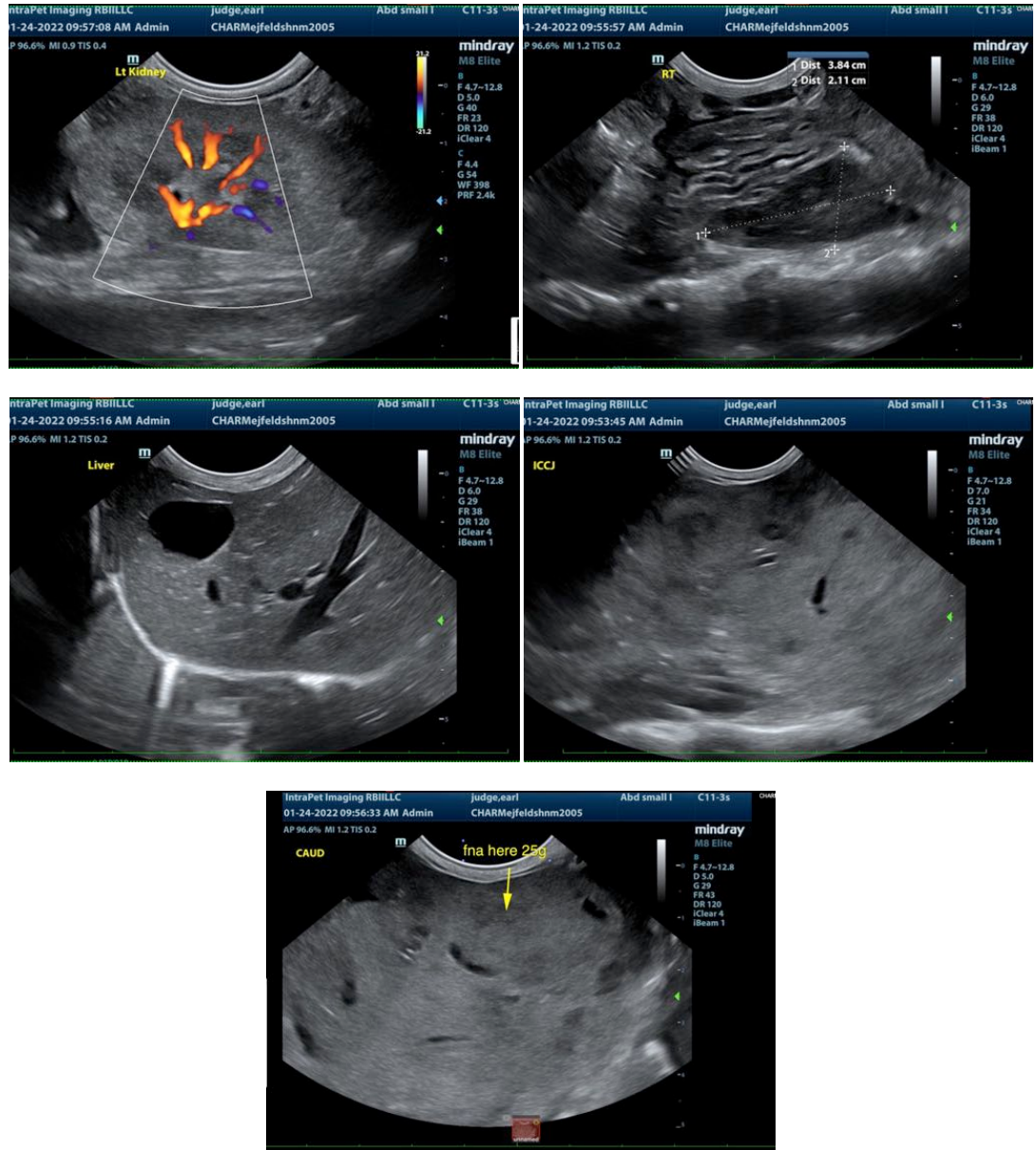
Free fluid owing to lymphatic congestion.

Ring down artifact in the chest.

INTERPRETATION OF THE FINDINGS & FURTHER RECOMMENDATIONS

FNA of the mass can be considered with hopes of chemoreduction. This is most likely lymphoma versus carcinoma. Chest radiographs are recommended to assess for metastatic disease.





The information and recommendations provided are based on the images presented by the referring veterinarian. No evaluation can be communicated regarding pathology that was not visible in the image/video clips provided.

Thank you for this referral. If the clinical or image interpretation does not parallel your findings or if I can be of any further assistance please contact me.

Eric Lindquist, DMV, DABVP, Cert. IVUSS, CEO of SonoPath.com
 Eric.Lindquist@SonoPath.com