



PATIENT

Zeena Faase

SPECIES

Canine

BREED

Pit x

SEX

Spayed Female

AGE

10

WEIGHT

57

INTERPRETED BY

Eric Lindquist, DMV,
DABVP (CFM), Cert.
IVUSS

IMAGING PERFORMED BY

Dr. Linda Grau

HOSPITAL NAME

Fredon Animal
Hospital

REFERRING VET

Dr. Linda Grau

INVOICE

72436

DATE

1/23/26

PRESENTING CLINICAL SIGNS

Poor appetite, sudden onset of lethargy

Abnormal PE/Chem/CBC/UA Results: Slightly pale mm, organomegaly on abd exam, mid abd mass on rad

ULTRASONOGRAPHIC EXAMINATION OF THE ABDOMEN

Urinary System

The **urinary bladder**, trigone, and pelvic urethra presented normal thicknesses and normal tone. The ureters were not visible which is normal. No uroliths or sediment were visualized and anechoic urine was present. No evidence of inflammatory or neoplastic changes were noted. Ureteral papillae were normal. The pelvic urethra was imaged 2.0 cm beyond the cystourethral junction.

The **kidneys** revealed normal size and structure, corticomedullary definition and ratio for this age. The cortices presented largely uniform texture with normal echogenic relationship to liver and spleen. Medullary structure differed distinctly from the cortex and no evidence of pelvic dilation was present. The capsules were acceptably uniform without significant irregularities. Left kidney measured 6.4 cm. Right kidney measured 5.7 cm.

Adrenal Glands

The **left adrenal gland** was visualized and recognized as having normal shape, size, position and echogenicity for this breed. The phrenic vasculature, glandular echogenicity and detail were unremarkable. Capsule, cortex, and medullary definition were normal for this age patient. Left adrenal gland measured 0.50 cm.

The **right adrenal gland** was not visualized.

Spleen

The **spleen** revealed a moderately complex parenchymal mass with surrounding free fluid, consistent with hemorrhage. The mass measured 11.0+ cm.

Liver

The **liver** images from right and left intercostal as well as subcostal views revealed subjectively normal liver size, contour, and structure. Some age-related parenchymal remodeling was noted but likely not clinically significant at this time. Vascular and biliary tracts were of normal volume and no evidence of congestion was noted. The gallbladder presented some dependent debris with essentially normal contour. The cystic and common bile ducts were normal. No overt evidence of active inflammatory, infiltrative or regenerative pathology was noted but should be paired with current or past LE elevations regarding any clinical significance to this presentation. The hepatic lymph nodes were unremarkable. No overt evidence of metastatic disease.

Gastrointestinal

There was some residual chyme and gas was noted in the **stomach**, yet not pathological. This is consistent with end post prandial presentation. Transit of chyme into the small intestine was normal. Curvilinear patterns were maintained throughout the GI tract. No evidence of pathology. Small and



PATIENT

Zeena Faase

SPECIES

Canine

BREED

Pit x

SEX

Spayed Female

AGE

10

WEIGHT

57

INTERPRETED BY

Eric Lindquist, DMV,
DABVP (CFM), Cert.
IUUSS

IMAGING PERFORMED BY

Dr. Linda Grau

HOSPITAL NAME

Fredon Animal
Hospital

REFERRING VET

Dr. Linda Grau

INVOICE

72436

DATE

1/23/26

large intestine demonstrated normal luminal chyme and stool consistency respectively. No obstructive or overt infiltrative disease was noted. No associated abnormal lymphatic activity was noted.

Pancreas

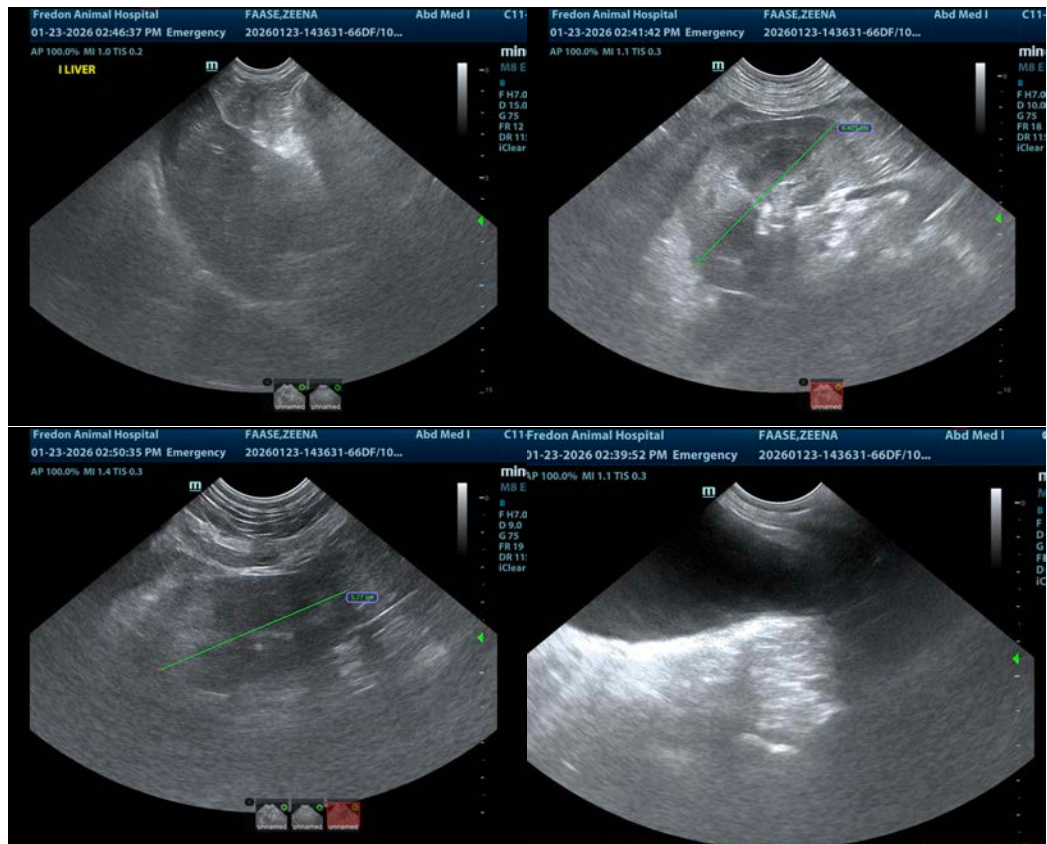
The base and limbs of the **pancreas** were observed to be largely isoechoic to surrounding omental fat. Pancreatic duct and capsular contour were acceptably normal and parenchyma respected normal curvilinear patterns. No overt evidence of active inflammatory or neoplastic disease was noted.

ULTRASONOGRAPHIC FINDINGS

- Splenic mass - Hemangiosarcoma likely, benign hepatoma with rupture possible. Round cell neoplasia unlikely.
- Age related hepatic changes.
- Partially full stomach.

INTERPRETATION OF THE FINDINGS & FURTHER RECOMMENDATIONS

Echocardiogram and chest radiographs warranted followed by exploratory splenectomy.





PATIENT

Zeena Faase

SPECIES

Canine

BREED

Pit x

SEX

Spayed Female

AGE

10

WEIGHT

57

INTERPRETED BY

Eric Lindquist, DMV,
DABVP (CFM), Cert.
IVUSS

IMAGING PERFORMED BY

Dr. Linda Grau

HOSPITAL NAME

Fredon Animal
Hospital

REFERRING VET

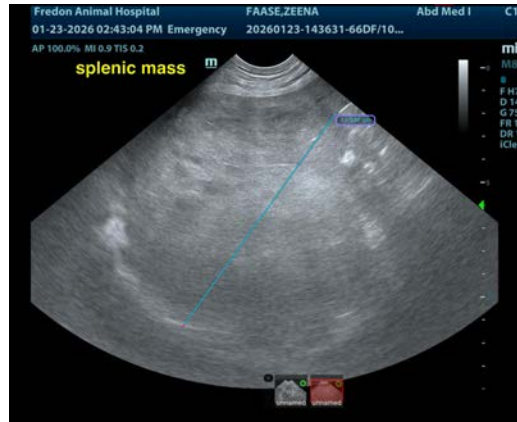
Dr. Linda Grau

INVOICE

72436

DATE

1/23/26



The information and recommendations provided are based on the images presented by the referring veterinarian/sonographer. No evaluation can be communicated regarding pathology that was not visible in the image/video clips provided.

Thank you for this referral. If the clinical or image interpretation does not parallel your findings or if I can be of any further assistance please contact me.

Eric Lindquist, DMV, DABVP(CFM), Cert. IVUSS,
CEO, Owner, Founder -- SonoPath.com
info@SonoPath.com