



## PATIENT

Dino Kentop

## SPECIES

Canine

## BREED

Yorkshire Terrier

## SEX

Male

## AGE

8 Years

## WEIGHT

6.3 lbs

## INTERPRETED BY

Eric Lindquist, DMV,  
DABVP (CFM), Cert.  
IVUS

## IMAGING PERFORMED BY

Dr. Kathleen Laux

## HOSPITAL NAME

Rondout Valley  
Veterinary Associates

## REFERRING VET

Dr. Kathleen Laux

## INVOICE

72432

## DATE

1/23/26

## PRESENTING CLINICAL SIGNS

Has a history of enlarged prostate and on and off prostatitis. Owner is now ready to neuter him, but now he is vomiting bile.

Abnormal PE/Chem/CBC/UA Results: Pending

## ULTRASONOGRAPHIC EXAMINATION OF THE ABDOMEN

### Urinary System

The **bladder** in this patient was mildly thickened with slight echogenic mural changes. No calculi or masses were noted. Slight micropolypoid changes were noted. This is a frequent finding in older animals and may be linked to a history of chronic urinary tract infection or active urinary tract infection. Urinalysis would be recommended with culture if any evidence of inflammatory sediment is present. The region of the trigone and visible pelvic urethra were normal.

The **prostate** was uniformly enlarged (2.2 cm) with lobar swelling appeared to impinge upon the urethra and mildly deviate the descending colon. The prostatic tissue was hyperechoic containing focal areas of decreased echogenicity. These changes are suggestive of either chronic inflammatory episodes, benign cystic pathology or both. Underlying neoplasia cannot be completely ruled-out but is lower on the differential list. This presentation is most consistent with benign prostatic hyperplasia with possible active prostatitis.

The **kidneys** revealed normal size and structure, corticomedullary definition and ratio for this age. The cortices presented largely uniform texture with normal echogenic relationship to liver and spleen. Medullary structure differed distinctly from the cortex and no evidence of pelvic dilation was present. The capsules were acceptably uniform without significant irregularities. Left kidney measured 3.8 cm. Right kidney measured 3.73 cm.

### Adrenal Glands

Both **adrenal glands** were visualized and recognized as having normal shape, size, position and echogenicity for this breed. The phrenic vasculature, glandular echogenicity and detail were unremarkable. Capsule, cortex, and medullary definition were normal for this age patient. Left measured 0.59 cm. Right measured 0.30 cm.

### Spleen

The **spleen** presented a smooth homogeneous parenchyma hyperechoic to liver and renal cortical parenchyma. The capsule was smooth without noticeable expansion or deviation from within the spleen or adjacent pathology. The splenic vasculature demonstrated normal volume without signs of congestion or thrombosis. No sonographic evidence of acute or chronic inflammatory, neoplastic, or infarctual changes were noted.

### Liver

The **liver** images submitted revealed subjectively normal liver size, contour, and structure. Parenchymal echogenicity was naturally coarse and hypoechoic to the spleen. Vascular and biliary tracts were of normal volume with no evidence of congestion. The gallbladder presented acceptably thin walls with primarily anechoic content. The cystic and common bile ducts were normal. No pathological hepatic



## PATIENT

Dino Kentop

## SPECIES

Canine

## BREED

Yorkshire Terrier

## SEX

Male

## AGE

8 Years

## WEIGHT

6.3 lbs

## INTERPRETED BY

Eric Lindquist, DMV,  
DABVP (CFM), Cert.  
IVUSS

## IMAGING PERFORMED BY

Dr. Kathleen Laux

## HOSPITAL NAME

Rondout Valley  
Veterinary Associates

## REFERRING VET

Dr. Kathleen Laux

## INVOICE

72432

## DATE

1/23/26

lymphadenopathy was evident. No overt structural evidence of inflammatory, infiltrative or regenerative pathology was evident.

### Gastrointestinal

The **stomach** presented mild hypertrophy, measuring 1.2 cm in wall thickness. No loss of mural detail. The small intestine and colon were unremarkable.

### Pancreas

Diffuse hyperechoic changes were present in the area of the **pancreas**. The pancreatic remodeling was evident with multifocal to diffuse hyperechoic changes. These changes are consistent with fibrosis, amyloid, saponification of fat and may contain areas of low-grade chronic active inflammation especially if pain on imaging (+ Murphy sign) was present +/- focal subxyphoid palpation reveals pain response. No overt masses were noted.

### ULTRASONOGRAPHIC FINDINGS

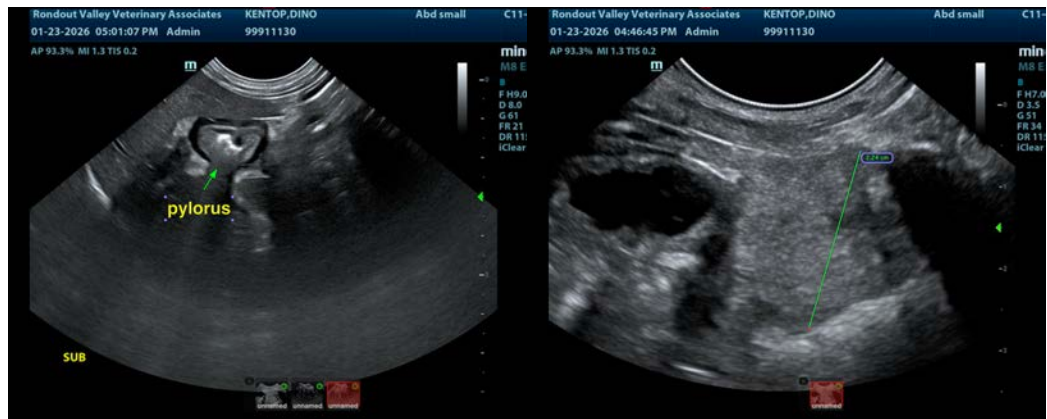
- BPH prostate, some level of prostatitis/cystitis possible.
- Polypoid bladder changes.
- Non-specific gastritis, no overt evidence of neoplasia.
- Pancreatic fibrosis.

### INTERPRETATION OF THE FINDINGS & FURTHER RECOMMENDATIONS

Neutering should prove effective in this patient. If neutering is not an option, off-label Finasteride (Propecia) (0.1-0.5 mg/kg Sid) treatment +/- FNA or prostatic wash cytology and culture. GI protectant protocol such as the following should be considered.

#### Helicobacter/Gastritis protocol

A clinical trial of **Zithromax** (Dogs: 5-10 mg/kg p.o. q24h. May increase dosing interval to q48h after 3-5 days of treatment), **Metronidazole** (10-20 mg/kg p.o. b.i.d.), **Pepcid** (0.5-1 mg/kg s.i.d.) and **Sucralfate** (0.5-2 g/dog PO) or **Omeprazole** (1 mg/kg p.o. s.i.d.) over the next 3 weeks along with a **novel-protein or hydrolyzed diet** with slurry feeding b.i.d./t.i.d. over the next 2-4 days and then increase to canned diet bid. Dry food should be avoided over the next 4 weeks. A recheck sonogram to assess GI improvement or progression would be ideal in 4 weeks.





## PATIENT

Dino Kentop

## SPECIES

Canine

## BREED

Yorkshire Terrier

## SEX

Male

## AGE

8 Years

## WEIGHT

6.3 lbs

## INTERPRETED BY

Eric Lindquist, DMV,  
DABVP (CFM), Cert.  
IVUSS

## IMAGING PERFORMED BY

Dr. Kathleen Laux

## HOSPITAL NAME

Rondout Valley  
Veterinary Associates

## REFERRING VET

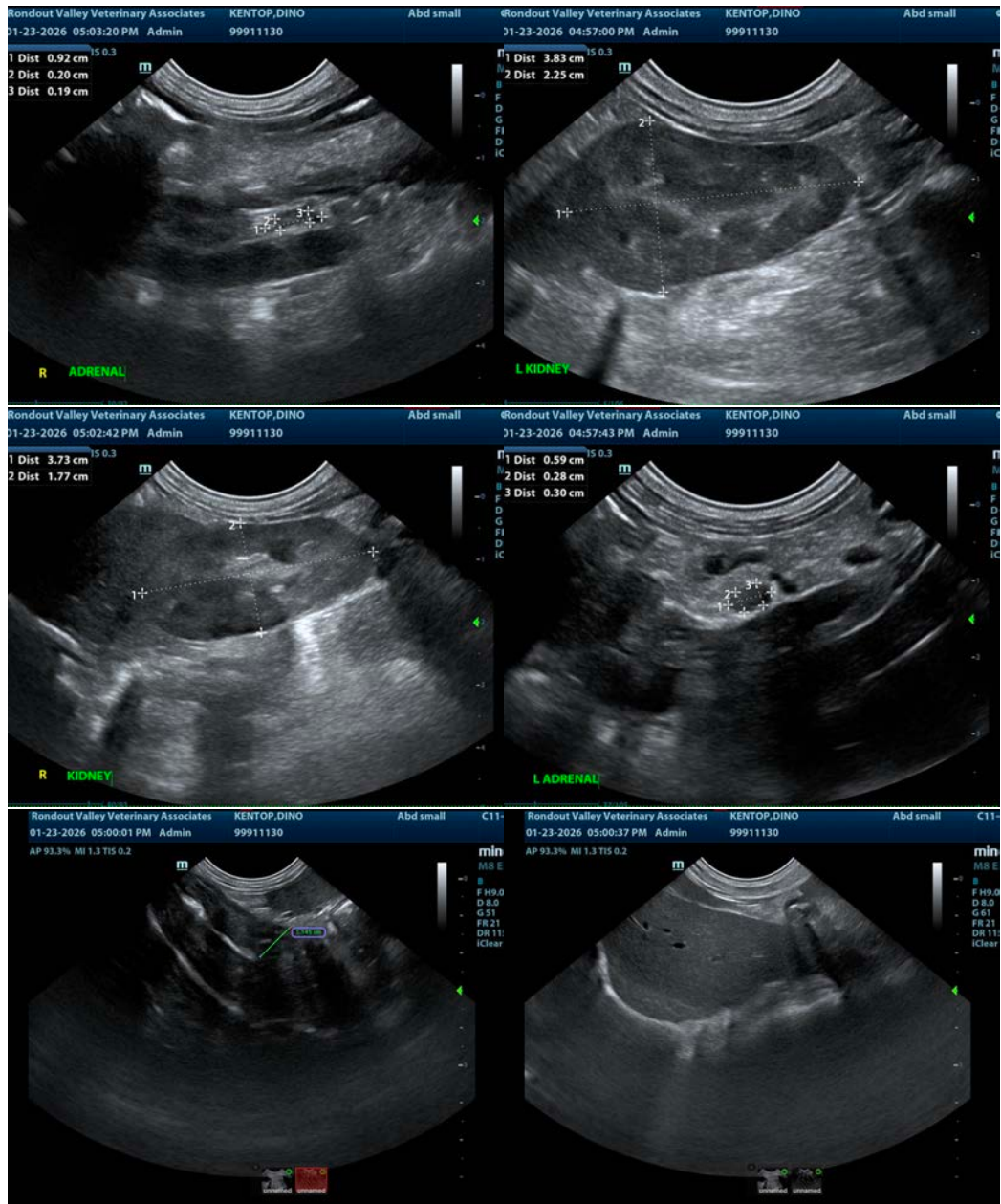
Dr. Kathleen Laux

## INVOICE

72432

## DATE

1/23/26





## PATIENT

Dino Kentop

## SPECIES

Canine

## BREED

Yorkshire Terrier

## SEX

Male

## AGE

8 Years

## WEIGHT

6.3 lbs

## INTERPRETED BY

Eric Lindquist, DMV,  
DABVP (CFM), Cert.  
IVUSS

## IMAGING PERFORMED BY

Dr. Kathleen Laux

## HOSPITAL NAME

Rondout Valley  
Veterinary Associates

## REFERRING VET

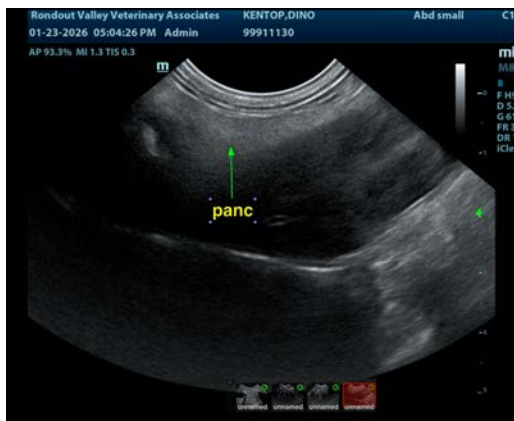Dr. Kathleen Laux

## INVOICE

72432

## DATE

1/23/26



The information and recommendations provided are based on the images presented by the referring veterinarian/sonographer. No evaluation can be communicated regarding pathology that was not visible in the image/video clips provided.

Thank you for this referral. If the clinical or image interpretation does not parallel your findings or if I can be of any further assistance please contact me.

**Eric Lindquist**, DMV, DABVP(CFM), Cert. IVUSS,  
CEO, Owner, Founder -- SonoPath.com  
[info@SonoPath.com](mailto:info@SonoPath.com)