



**PATIENT PRESENTING CLINICAL SIGNS**

**Zona Lee** P presented 12/19/22 with acute D and increased urinary accidents. P started on Metronidazole and D improved at that time but not full return of normal stool consistency. P started on Enrofloxacin for UTI. P returned 12/30/22 with return of D, decreased appetite, increased urinary accidents.

**SPECIES** Metronidazole restarted along with Cerenia and Mirtazapine. O called with updates 01/03/23 and 01/06/23 with no stools to diarrhea and no interest regular diet, Hill's I/D low fat, minimal interest in boiled chicken or scrambled eggs. Decreased dose of Enrofloxacin 136mg from 2tabs PO SID to 1.25tabs PO SID. Decreased dose improve appetite slightly.

**BREED** Abnormal PE/Chem/CBC/UA Results: 12/30/22 - SDMA 19, Cr 1.7, BUN 37, ALT 303, ALP 918 all increased values since last labs on 11/09/22. Current Medications Proin 75mg - 1tab PO BID, Galliprant 60mg - 1tab PO SID, Gabapentin 100mg - 2-3caps PO q8-12hrs.

**SEX**

**FS**

**AGE ULTRASONOGRAPHIC EXAMINATION OF THE ABDOMEN**

**Urinary System**

**13yr** The urinary bladder, trigone, and pelvic urethra presented normal thicknesses and normal tone. The ureters were not visible which is normal. No uroliths or sediment were visualized and anechoic urine was present. No evidence of inflammatory or neoplastic changes were noted. Ureteral papillae were normal.

**WEIGHT** 50lb

**INTERPRETED BY** Eric Lindquist, DMV DABVP, Cert. IVUSS

The kidneys revealed largely normal size and structure, corticomedullary definition and ratio (cortex 1/3 of medulla) were essentially maintained with some age-related loss of curvilinear patterns regarding the capsule and C/M junction. The cortices presented largely uniform texture with some increased echogenicity expected for his age patient. Medullary structure differed distinctly from that of the cortex with left kidney pelvic dilation present measuring 1.5 cm. The left kidney measured 6.0 cm in length. The right kidney measured 7.6 cm in length.

**Adrenal Glands**

**IMAGING PERFORMED BY**

Sara Hansen

The left adrenal gland was mildly irregular at the caudal pole. The phrenic vasculature, glandular echogenicity and detail were unremarkable. Capsule, cortex, and medullary definition were normal for this age patient. The left adrenal gland measured 2.3 cm in length by 1.3 cm caudal pole width. The right adrenal gland measured 2.49 cm in length by 0.63 cm caudal pole width by 1.38 cm cranial pole width.

**HOSPITAL NAME**

Creekside Veterinary Clinic

**Spleen**

The spleen was folded upon itself with uniform enlargement.

**REFERRING VET**

Dr. Eggert

**Liver**

**INVOICE**

12762ag

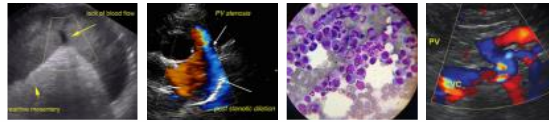
The liver revealed an extensive mixed hypoechoic mass deriving from the right cranial pole measuring ~ 10+ cm with regional inflammation. A separate mass deriving from the mid caudal liver was present extending into the cranial abdomen. A third mass was present likely of lymph node origin measuring 5.0 cm.

**DATE**

01/23/2023

**Gastrointestinal**

Examination of the gastrointestinal tract revealed a stomach and intestine free of stasis, of normal wall thickness, acceptable curvilinear mural detail, and peristaltic activity. Small and large intestine



**PATIENT**

Zona Lee

demonstrated normal luminal chyme and stool consistency respectively. No obstructive or overt infiltrative disease was noted. No associated abnormal lymphatic activity was noted.

**Pancreas**

**SPECIES**

Canine

The base and limbs of the pancreas were observed to be largely isoechoic to surrounding omental fat. Pancreatic duct and capsular contour were acceptably normal and parenchyma respected normal curvilinear patterns. No overt evidence of active inflammatory or neoplastic disease was noted.

**BREED**

Boxer Mix

**ULTRASONOGRAPHIC FINDINGS**

**SEX**

FS

- Multifocal hepatic neoplasia with regional lymphadenopathy
- Age related renal changes

**AGE**

13yr

**INTERPRETATION OF THE FINDINGS & FURTHER RECOMMENDATIONS**

A hepatic FNA could be considered for further definition and potential chemo reduction. The masses do not appear resectable.

**WEIGHT**

50lb

**INTERPRETED BY**

Eric Lindquist, DMV  
DABVP, Cert. IVUS

**IMAGING PERFORMED BY**

Sara Hansen

**HOSPITAL NAME**

Creekside Veterinary  
Clinic

**REFERRING VET**

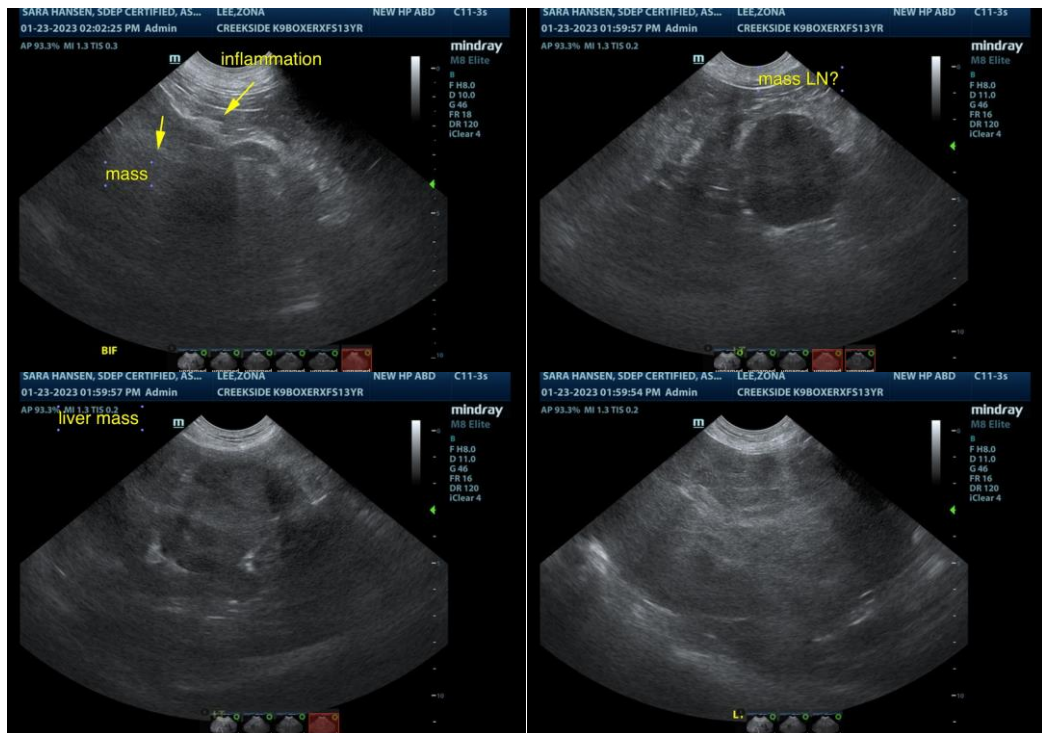
Dr. Eggert

**INVOICE**

12762ag

**DATE**

01/23/2023





**PATIENT**

Zona Lee

**SPECIES**

Canine

**BREED**

Boxer Mix

**SEX**

FS

**AGE**

13yr

**WEIGHT**

50lb

**INTERPRETED BY**

Eric Lindquist, DMV  
DABVP, Cert. IVUSS

**IMAGING PERFORMED BY**

Sara Hansen

**HOSPITAL NAME**

Creekside Veterinary  
Clinic

**REFERRING VET**

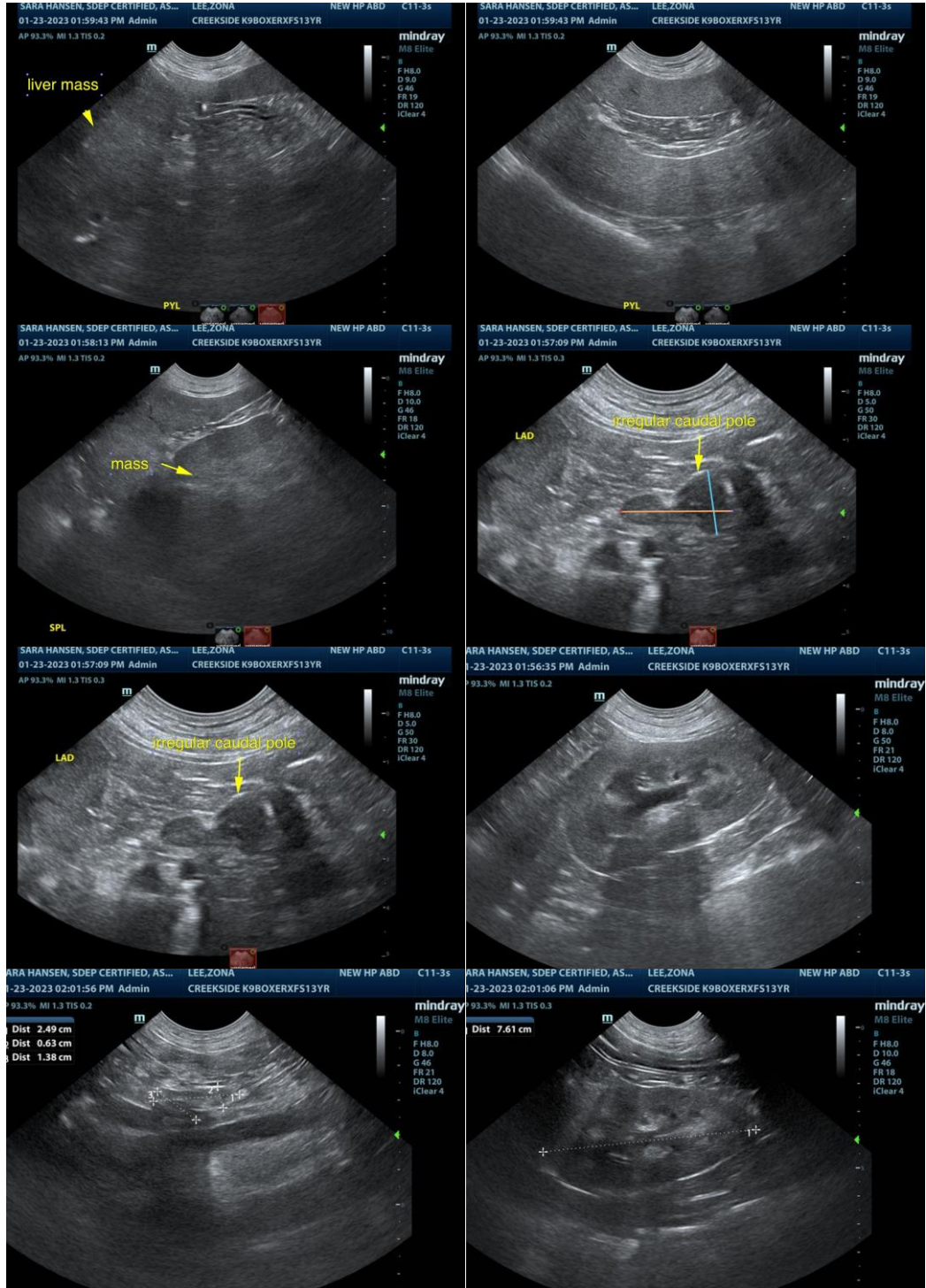
Dr. Eggert

**INVOICE**

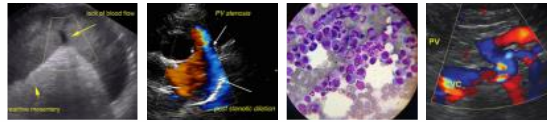
12762ag

**DATE**

01/23/2023



The information and recommendations provided are based on the images presented by the referring veterinarian. No evaluation can be communicated regarding pathology that was not visible in the



**PATIENT** image/video clips provided.

Zona Lee Thank you for this referral. If the clinical or image interpretation does not parallel your findings or if I can be of any further assistance please contact me.

**SPECIES**

Canine **Eric Lindquist, DMV, DABVP, Cert. IVUSS, CEO of SonoPath.com**  
[Eric.Lindquist@SonoPath.com](mailto:Eric.Lindquist@SonoPath.com)

**BREED**

Boxer Mix **Hepatic Masses, Biliary Adenoma, and Biliary Adenocarcinoma**

**SEX**

<http://www.sonopath.com/HepaticMasses>

**FS**

**Description:** Hepatocellular carcinoma typically manifests in the liver's left lateral lobes, yet may cross over to the right lobes should it derive from the hilus. These masses often present cavitating, necrotic cores that are difficult to distinguish from hepatic abscesses. Vascular channels may also be involved, and bile duct obstruction is often present. Older felines often present solitary or multiple fluid-filled cysts within the hepatic parenchyma. The latter are typically benign cystadenomas and should be differentiated from: cystic adenocarcinoma; hepatic lymphoma (usually diffusely hyperechoic +/- FIV/FelV association); metastatic neoplasia (diffuse hyper- to hypoechoic nodules secondary to mammary adenocarcinoma, splenic hemangiosarcoma, or pancreatic or intestinal adenocarcinoma); benign nodular hyperplasia (accompanied by minimal to no symptoms); hepatic cirrhosis (regenerative nodules); or rare carcinoids, fibrosarcomas, leiomyosarcomas, and osteosarcomas.

**AGE**

13yr

**WEIGHT**

50lb

**INTERPRETED BY**

Eric Lindquist, DMV  
DABVP, Cert. IVUSS

**Clinical Signs:** Possible clinical signs and physical exam findings include cranial abdominal organomegaly, sudden collapse associated with mass rupture, vomiting, ascites, jaundice (severe cases), and hypoglycemia secondary to a paraneoplastic syndrome. Sepsis and fever associated with secondary abscessation of the mass may also occur. Cats usually present with anorexia and lethargy.

**IMAGING PERFORMED BY**

Sara Hansen

**Diagnostics:** Routine biochemical analysis primarily shows liver enzyme elevation (i.e., ALT for cellular necrosis; SAP for hepatic congestion; elevated bilirubin for stasis/obstruction; bile acids > 75-100uM/L for significant function impairment). Staging of the disease with 3-view thoracic radiographs is essential, as is conducting a CBC, serum biochemistry, urinalysis, as well as abdominal and possibly also thoracic ultrasounds in order to provide the owner with adequate and well-informed options. Surgical and oncological referral is recommended after a coagulation panel has been assessed and ultrasound-guided biopsies of both normal and pathological tissue have been performed such that the disease is adequately characterized. In cases where surgical resection is impossible, direct chemoembolization of the tumor blood supply could be considered; however, this procedure is only performed at specific tertiary referral locations. Placement of palliative stents into the caudal vena cava (CVC) can be considered as well if compression by an unresectable tumor causes excessive ascitic fluid accumulation. Serum alpha-fetoprotein (AFP) has been shown to reemerge in dogs with malignant hepatobiliary adenocarcinoma. Ultrasound is important to localize the mass in relation to the portal hilus and gallbladder. The portal vein, CVC, aorta, gallbladder, and bile duct should all be identified with respect to the location of the mass to determine resectability. Ultrasound also allows for an examination of possible metastatic sites in the abdomen and, to some degree, in the thorax.

**HOSPITAL NAME**

Creekside Veterinary  
Clinic

**REFERRING VET**

Dr. Eggert

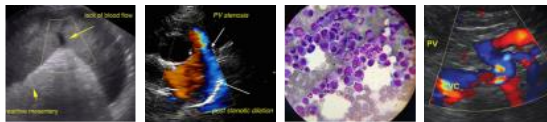
**INVOICE**

12762ag

**DATE**

01/23/2023

**Treatment:** Hepatic adenoma, hepatoma, and adenocarcinoma are usually amenable to surgical resection via hepatic lobectomy should the pathology be isolated to single-lobe progression. Multi-lobe presentation may be amenable to lobectomy and debulking; this will be determined further during surgical consultation. These tumors tend to displace unaffected parenchyma, allowing for relatively straightforward surgical resection. Up to 80% of the liver can be removed without long-term functional



**PATIENT**

Zona Lee

**SPECIES**

Canine

**BREED**

Boxer Mix

**SEX**

FS

**AGE**

13yr

**WEIGHT**

50lb

**INTERPRETED BY**

Eric Lindquist, DMV  
DABVP, Cert. IVUSS

**IMAGING PERFORMED BY**

Sara Hansen

**HOSPITAL NAME**

Creekside Veterinary  
Clinic

**REFERRING VET**

Dr. Eggert

**INVOICE**

12762ag

**DATE**

01/23/2023

deficits. Blood transfusions may be necessary during surgery. The development and implementation of the LDS™ stapler has helped to streamline the procedure. Most carcinomas have metastasized by the time of diagnosis yet tend to be slow-growing; thus, it may be possible for a certain quality of life to be attained via surgical resection. Hepatic hemangiosarcoma has usually metastasized at the time of diagnosis and carries a much poorer prognosis. Surgical resection and chemotherapy are recommended, but considered by many to be an “aggressive” approach.

Preliminary trials have shown that gemcitabine is well tolerated and yields good responses in cases of hepatic as well as pancreatic, colonic, and gastric carcinomas. Myelosuppression, however, remains the key issue. Doxorubicin, cyclophosphamide, and fluorouracil combinations have also proven fruitful.

Nonsteroidal anti-inflammatory drugs (NSAIDs) have been demonstrated to have an anti-neoplastic effect due to their inhibition of COX-2 in certain tumor cells. The end product of the cyclooxygenase cascade is prostaglandin E2, which, when expressed in tumor cell lines—and not expressed in normal cells of that particular cell line—results in inhibited apoptosis, immunosuppression, and increased angiogenesis, proliferation, and invasiveness. Inappropriate increases in COX-2 expression have been documented in certain neoplasias, including squamous cell carcinoma, mammary carcinomas, prostatic carcinoma, malignant melanoma, and transitional cell carcinoma.

Metronomic chemotherapy is currently being investigated and compared to traditional chemotherapy protocols; it is thought to be at least as effective as the latter with substantially less toxic side effects. Metronomic chemotherapy is the practice of uninterrupted administration of low-dose cytotoxic drugs at regular and frequent intervals, as opposed to high-dose, shorter-term protocols characteristic of traditional chemotherapeutic practices. The lower dose allows for long-term administration without toxic side effects, and has been postulated as providing longer remission intervals. Moreover, it has the benefit of minimizing the intervals between drug regimens—the period during which tumor cells may repopulate the area—as well as the chance of developing multi-drug resistant genes. Metronomic chemotherapy has been used successfully in human patients who have undergone previous chemotherapy administration. It is thought to destroy endothelial cells, thereby retarding angiogenesis and targeting regulatory T cells. To date, there have only been a few small clinical trials in veterinary patients, and these have focused on animals that have hemangiosarcoma and soft tissue sarcomas.

**Conclusion:** With respect to hepatic neoplasia, many surgical and chemotherapeutic options exist; however, it is best to consult with a local board certified oncologist who can help determine the best course of action.

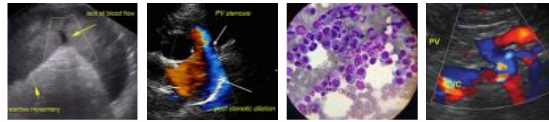
**References:**

Biller BJ. Teaching T cells to target tumors: towards the design of more effective cancer vaccines. Proceedings from the American College of Veterinary Internal Medicine Forum, Denver, CO, June 15-18, 2011.

Biller BJ, Guth A, Burton JH, Dow SW. Decreased ratio of CD8+ T cells to regulatory T cells associated with decreased survival in dogs with osteosarcoma. *J Vet Intern Med* 2010;24(5):1118-23.

Elmslie RE, Glawe P, Dow SW. Metronomic therapy with cyclophosphamide and piroxicam effectively delays tumor recurrence in dogs with incompletely resected soft tissue sarcomas. *J Vet Intern Med* 2008;22(6):1373-79.

Lana S, U'Ren L, Plaza S, et al. Continuous low-dose oral chemotherapy for adjuvant therapy of splenic hemangiosarcoma in dogs. *J Vet Intern Med* 2007;21(4):764-69.



**PATIENT**

Milner RJ. Do NSAIDs make a difference in cancer? Proceedings from the American College of Veterinary Internal Medicine Forum, Denver, CO, June 15-18, 2011.

Zona Lee

**SPECIES**

Canine

**BREED**

Boxer Mix

**SEX**

FS

**AGE**

13yr

**WEIGHT**

50lb

**INTERPRETED BY**

Eric Lindquist, DMV  
DABVP, Cert. IVUSS

**IMAGING  
PERFORMED BY**

Sara Hansen

**HOSPITAL NAME**

Creekside Veterinary  
Clinic

**REFERRING VET**

Dr. Eggert

**INVOICE**

12762ag

**DATE**

01/23/2023