

**PATIENT PRESENTING CLINICAL SIGNS**

Bobby Oliver Left A/G - 1/4 full, easy to express Right A/G - 1/4 full, easy to express, palpable mass associated with anal gland, does not appear attached to colon -smooth border to colon - approx 3 cm firm but not rock hard, non painful, well circumscribed area.

**SPECIES**

Canine

**BREED**

Lab Mix

**SEX**

MN

**AGE**

12yr

**WEIGHT**

32.6kg

**INTERPRETED BY**

Eric Lindquist, DMV  
DABVP, Cert. IVUSS

**IMAGING PERFORMED BY**

Kelly Reschny

**HOSPITAL NAME**

Aldershot AH

**REFERRING VET**

Wallace

**INVOICE**

12760ag

**DATE**

01/23/2023

**ULTRASONOGRAPHIC EXAMINATION OF THE ABDOMEN ADDENDUM**

**Anal Glands**

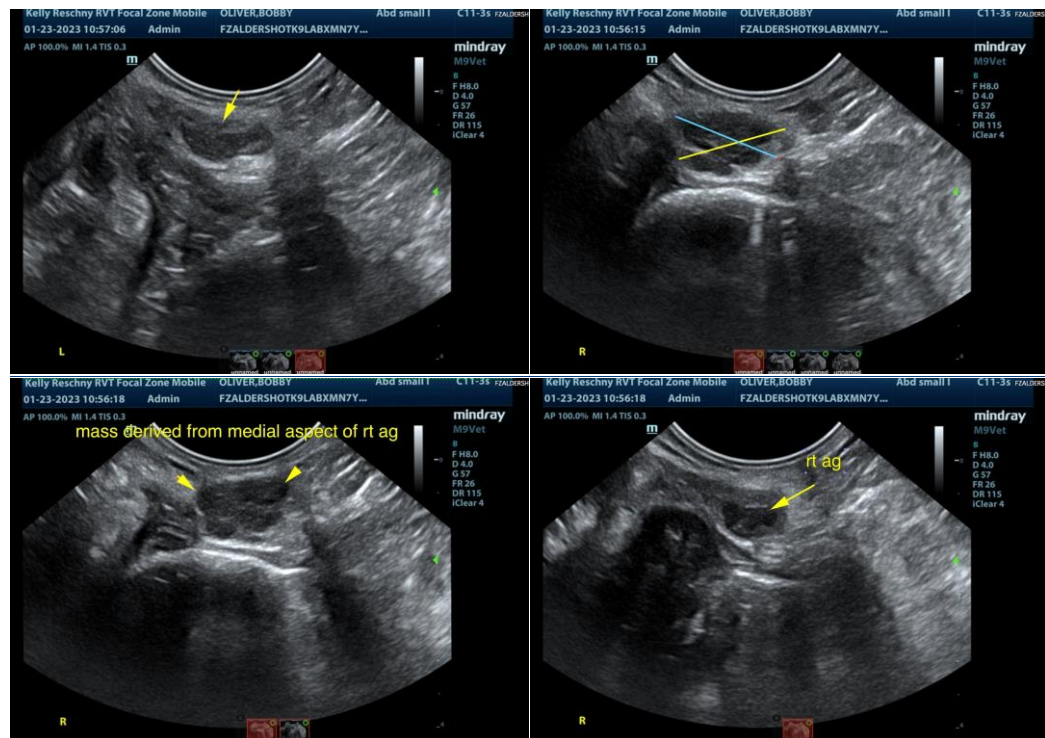
The right anal gland in this patient revealed a normal lumen, however the medial aspect of the gland expanded into an irregular hypoechoic 1.5 cm mass impinging upon the colorectum. The anal gland contour was irregular with early expansion present. This presentation is strongly consistent with carcinoma. The left anal gland was uniform with no evidence pathology and an empty lumen.

**ULTRASONOGRAPHIC FINDINGS**

- Irregular right adrenal gland-strong concern for early carcinoma

**INTERPRETATION OF THE FINDINGS & FURTHER RECOMMENDATIONS**

Strong concern for early right adrenal gland carcinoma. The left adrenal gland appeared fairly normal and encapsulated with slight irregular tissue. Bilateral surgical resection is recommended.



The information and recommendations provided are based on the images presented by the referring veterinarian. No evaluation can be communicated regarding pathology that was not visible in the image/video clips provided.

Thank you for this referral. If the clinical or image interpretation does not parallel your findings or if I



**PATIENT**

can be of any further assistance please contact me.

Bobby Oliver

**Eric Lindquist**, DMV, DABVP, Cert. IVUSS, CEO of SonoPath.com  
Eric.Lindquist@SonoPath.com

**SPECIES**

Canine

**BREED**

Lab Mix

**SEX**

MN

**AGE**

12yr

**WEIGHT**

32.6kg

**INTERPRETED BY**

Eric Lindquist, DMV  
DABVP, Cert. IVUSS

**IMAGING  
PERFORMED BY**

Kelly Reschny

**HOSPITAL NAME**

Aldershot AH

**REFERRING VET**

Wallace

**INVOICE**

12760ag

**DATE**

01/23/2023