



PATIENT

Ulysse Courmier

SPECIES

Feline

BREED

Siberian

SEX

Neutered Male

AGE

2 Years 8 Months

WEIGHT

16 lbs

INTERPRETED BY

Eric Lindquist, DMV,
DABVP (CFM), Cert.
IVUSS

IMAGING PERFORMED BY

Rebecca Hamilton

HOSPITAL NAME

All Creatures Great &
Small (Denville)

REFERRING VET

Dr. Ashmore

INVOICE

72388

DATE

1/22/26

PRESENTING CLINICAL SIGNS

Inc. ALT and CA + on BW. no Pu/Pd, no c/s/v/d. CA+ profile/ maldigestion profile pending.

Meds: Alendronate

Abnormal PE/Chem/CBC/UA Results: Inc. ALT 267 (HN 100) Inc. Ca - 12.7 (HN 10.8)

ULTRASONOGRAPHIC EXAMINATION OF THE HEART & ABDOMEN

FELINE CARDIAC PARAMETERS	BODY WEIGHT (lbs)	HR (BPM)	IVSd (cm)	LVIDd (cm)	LVWd (cm)	FS (%)	EF (%)
NORMAL PARAMETER	-----	150-240	0.3-0.6	1.0-2.1	0.25-0.6	35-67	80-100
PATIENT	16	180	0.39	1.46	0.4	39	74
FELINE CARDIAC PARAMETERS	LA/AO (M-mode)	LA/AO HEART BASE (Sisson)	LAD LA MAX 4 Chamber		LVOT VEL. (m/s)	RVOT VEL. (m/s)	IVRT (m/)
NORMAL PARAMETER	<1.5	1.6	0.7-1.7		<1.6	<1.3	40-60
PATIENT	1.0	1.3	1.3		1.0	0.5	NM
Adapted from June Boon, Veterinary Echocardiography, 1998 Sisson D et al. JVIM 1991; 5: 232, Jacobs et al. Am J Vet Res 1985; 46:1705							

E-wave velocity = 0.5. EPSS = 0.1

Cardiac Presentation

The echocardiogram in this patient demonstrated normal **left atrial** size based on 3 separate LA measurements. The cranial and caudal **mitral** valve leaflets presented normal linear structure and kinetics.. The **left ventricle** presented normal thicknesses with linear contour and was not dilated nor restricted. The **myocardium** presented normal echogenicity without subjective evidence of significant fibrotic or ischemic disease. **Contractility** of the ventricular walls was adequate and in normal range for this patient evidenced by the fractional shortening measurement and subjective evaluation of the different regions and angles of the myocardium. The **left ventricular outflow** tract demonstrated normal laminar flow and subjective structural integrity. The **right atrium** and auricle revealed normal size, structure and content. No evidence of masses was noted or chamber overload. **Tricuspid** valvular assessment demonstrated adequate linear morphology and kinetics. The **right ventricle** was of normal size (1/3 diameter of LV), chordae structure, myocardial echogenicity and thickness. **Pulmonic** tract assessment revealed normal valve structure, laminar flow, and diameter (approx.1:1 pa/ao ratio). No visible **pericardial** or free pleura fluid was noted or extra cardiac pathology in the visible planes. The cranial **mediastinum and pericardial regions** were free of masses in the visible window.



PATIENT

Ulysse Courmier

SPECIES

Feline

BREED

Siberian

SEX

Neutered Male

AGE

2 Years 8 Months

WEIGHT

16 lbs

INTERPRETED BY

Eric Lindquist, DMV,
DABVP (CFM), Cert.
IVUSS

IMAGING PERFORMED BY

Rebecca Hamilton

HOSPITAL NAME

All Creatures Great &
Small (Denville)

REFERRING VET

Dr. Ashmore

INVOICE

72388

DATE

1/22/26

Urinary System

The **urinary bladder** revealed a small amount of calculi/sand, a grouping of which measured 0.90 cm. Otherwise, the urinary bladder was unremarkable. The pelvic urethra was imaged 3.0 cm beyond the cystourethral junction.

The **kidneys** revealed normal size and structure, corticomedullary definition and ratio for this age. The cortices presented largely uniform texture with normal echogenic relationship to liver and spleen. Medullary structure differed distinctly from the cortex and no evidence of pelvic dilation was present. The capsules were acceptably uniform without significant irregularities. Right kidney measured 4.13 cm. Left kidney measured 4.04 cm.

Adrenal Glands

Both **adrenal glands** were visualized and recognized as having normal shape, size, position and echogenicity for this breed. The phrenic vasculature, glandular echogenicity and detail were unremarkable. Capsule, cortex, and medullary definition were normal for this age patient. Right measured 0.27 cm. Left measured 0.26 cm.

Spleen

The **spleen** was mildly to moderately enlarged at 1.4 cm with slight scalloping contour.

Liver

The **liver** images submitted revealed subjectively normal liver size, contour, and structure. Parenchymal echogenicity was naturally coarse and hypoechoic to the spleen. Vascular and biliary tracts were of normal volume with no evidence of congestion. The gallbladder presented acceptably thin walls with primarily anechoic content. The cystic and common bile ducts were normal. No pathological hepatic lymphadenopathy was evident. No overt structural evidence of inflammatory, infiltrative or regenerative pathology was evident. Portal vein measured 0.40 cm with normal branching. No evidence of intrahepatic or extrahepatic shunting.

Gastrointestinal

Examination of the **gastrointestinal tract** revealed a stomach and intestine free of stasis, of normal wall thickness, acceptable curvilinear mural detail, and peristaltic activity. Small and large intestine demonstrated normal luminal chyme and stool consistency respectively. No obstructive or overt infiltrative disease was noted. No associated abnormal lymphatic activity was noted.

Pancreas

The base and limbs of the **pancreas** were observed to be largely isoechoic to surrounding omental fat. Pancreatic duct and capsular contour were acceptably normal and parenchyma respected normal curvilinear patterns. No overt evidence of active inflammatory or neoplastic disease was noted.

ULTRASONOGRAPHIC FINDINGS

- Enlarged spleen with scalloping contour.
- Minor amount of bladder sand.
- Structurally normal liver, no evidence of portosystemic shunting.



PATIENT

Ulysse Courmier

SPECIES

Feline

BREED

Siberian

SEX

Neutered Male

AGE

2 Years 8 Months

WEIGHT

16 lbs

INTERPRETED BY

Eric Lindquist, DMV,
DABVP (CFM), Cert.
IVUSS

IMAGING PERFORMED BY

Rebecca Hamilton

HOSPITAL NAME

All Creatures Great &
Small (Denville)

REFERRING VET

Dr. Ashmore

INVOICE

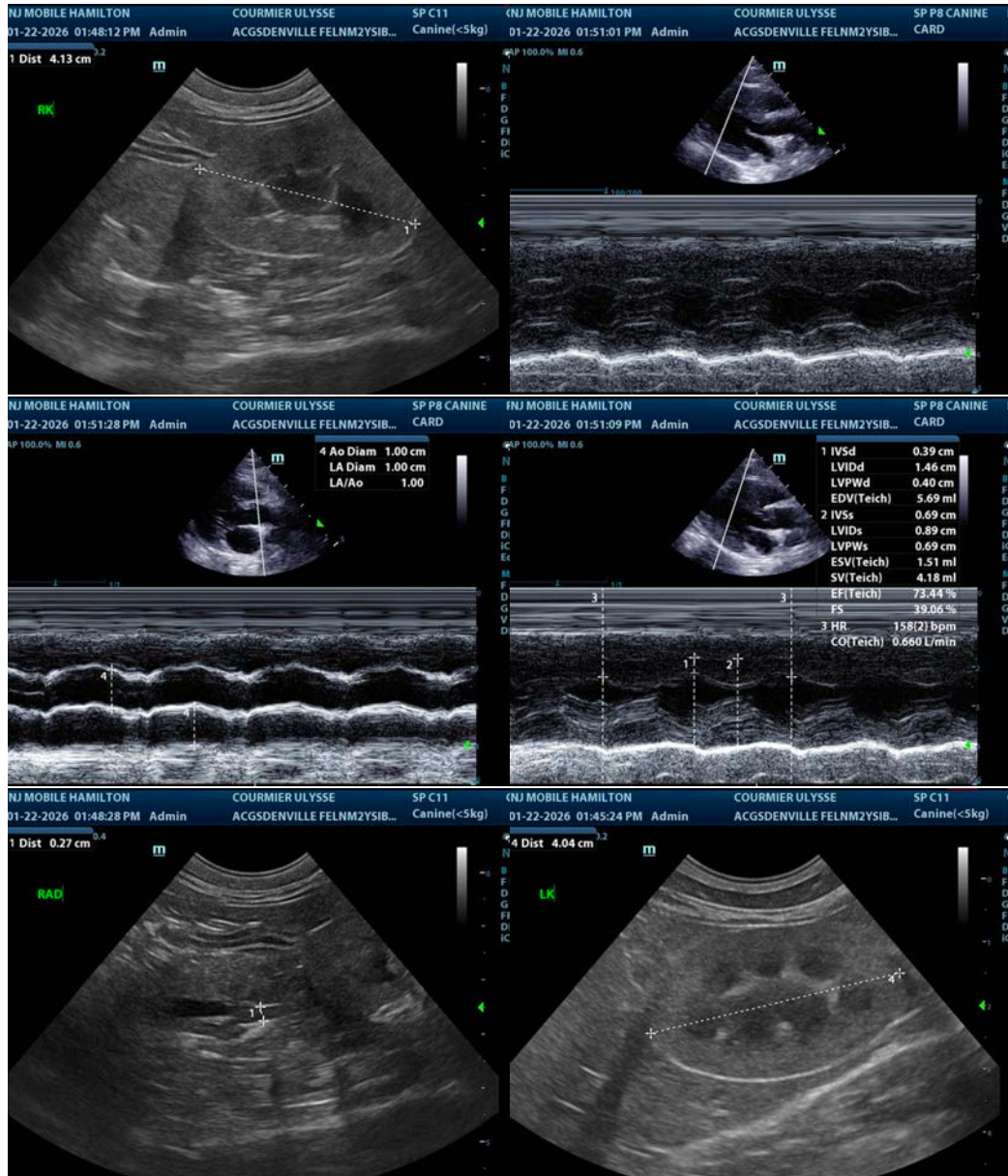
72388

DATE

1/22/26

INTERPRETATION OF THE FINDINGS & FURTHER RECOMMENDATIONS

FNA of the spleen indicated to ensure this is a reactive spleen versus emerging round cell neoplasia.





PATIENT

Ulysse Courmier

SPECIES

Feline

BREED

Siberian

SEX

Neutered Male

AGE

2 Years 8 Months

WEIGHT

16 lbs

INTERPRETED BY

Eric Lindquist, DMV,
 DABVP (CFM), Cert.
 IVUSS

IMAGING PERFORMED BY

Rebecca Hamilton

HOSPITAL NAME

All Creatures Great &
 Small (Denville)

REFERRING VET

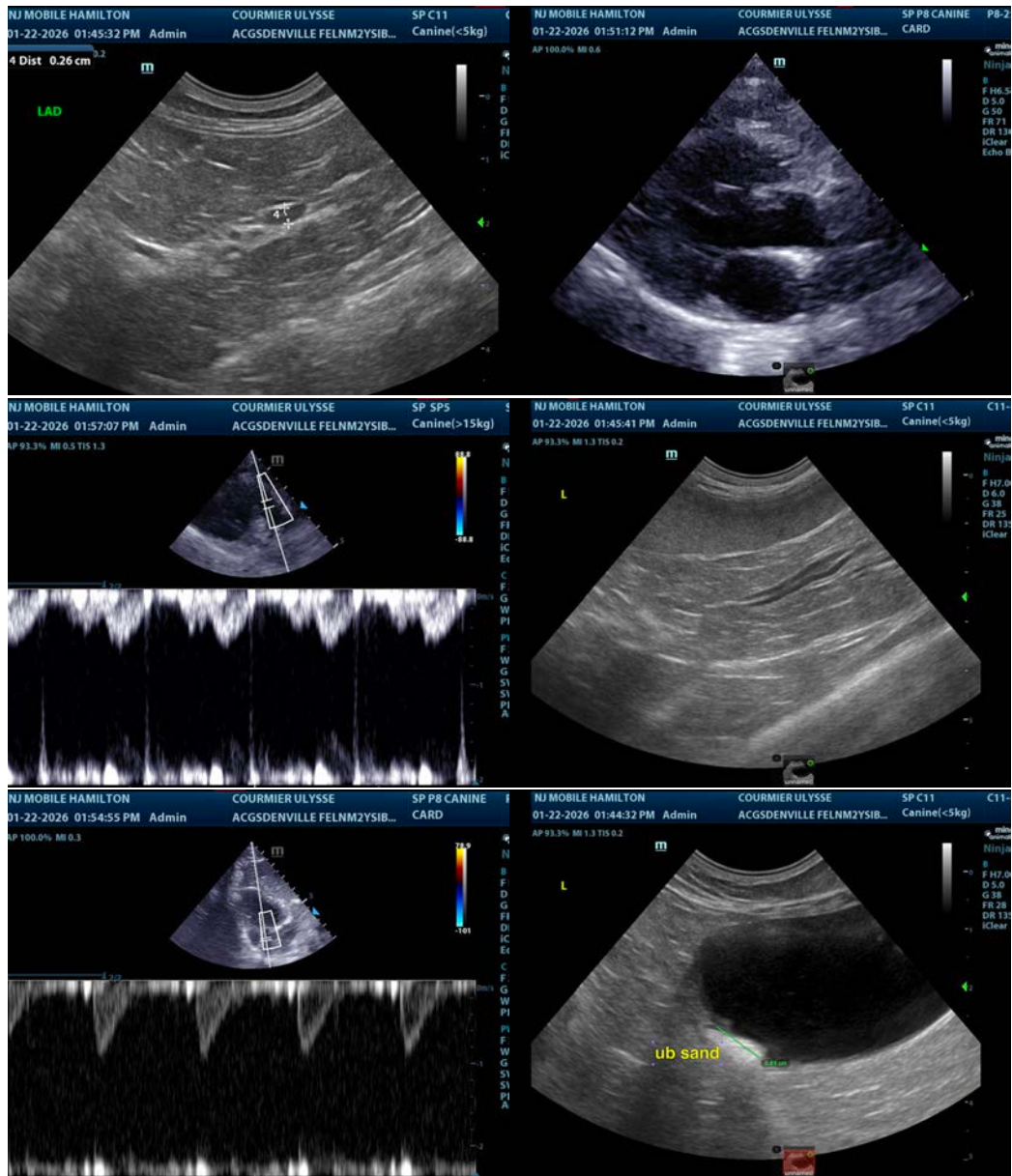
Dr. Ashmore

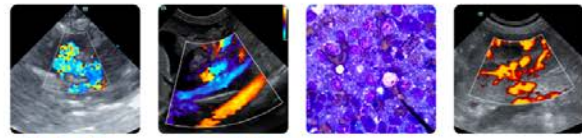
INVOICE

72388

DATE

1/22/26





PATIENT

Ulysse Courmier

SPECIES

Feline

BREED

Siberian

SEX

Neutered Male

AGE

2 Years 8 Months

WEIGHT

16 lbs

INTERPRETED BY

Eric Lindquist, DMV,
DABVP (CFM), Cert.
IVUSS

IMAGING PERFORMED BY

Rebecca Hamilton

HOSPITAL NAME

All Creatures Great &
Small (Denville)

REFERRING VET

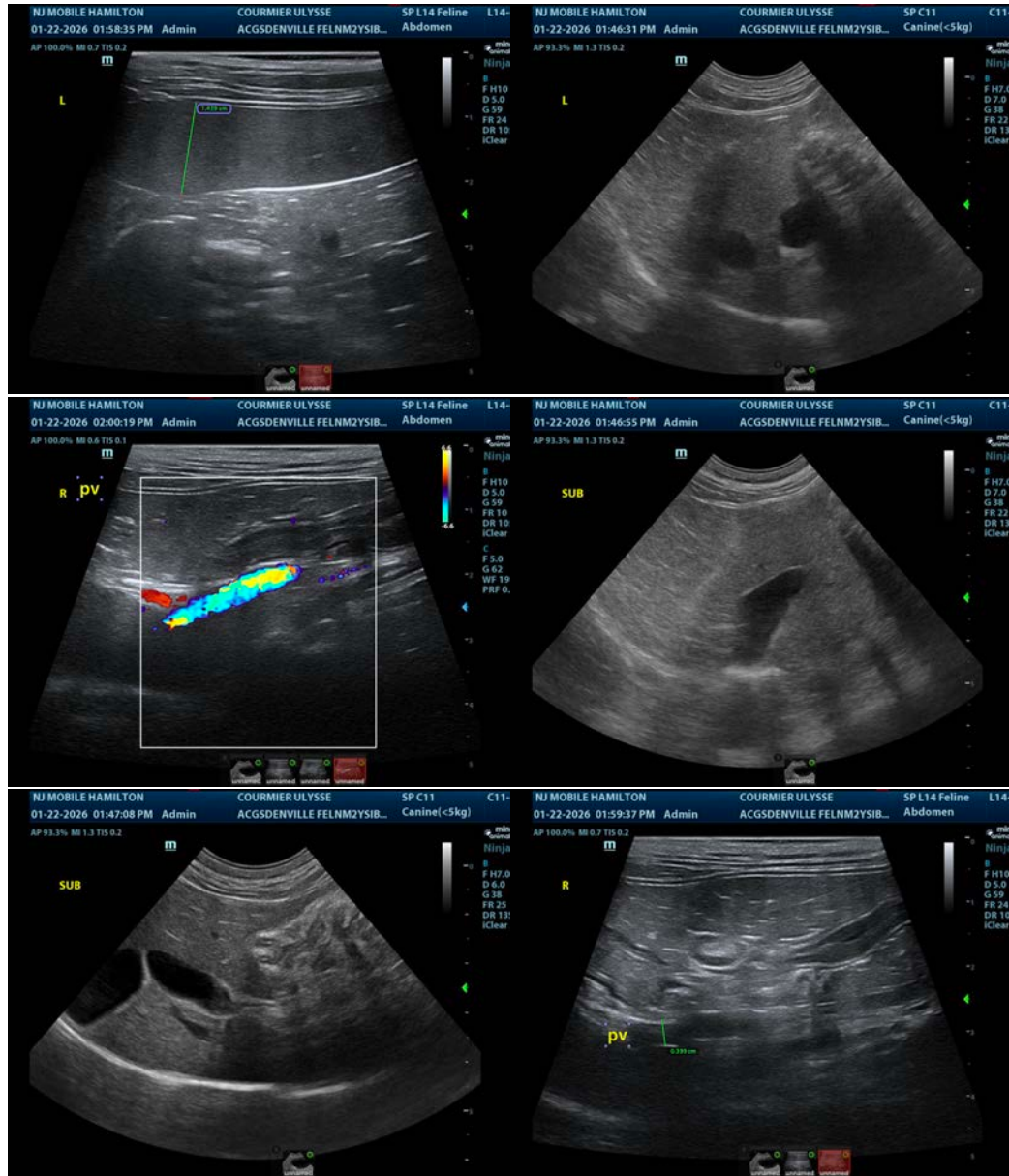
Dr. Ashmore

INVOICE

72388

DATE

1/22/26



The information and recommendations provided are based on the images presented by the referring veterinarian/sonographer. No evaluation can be communicated regarding pathology that was not visible in the image/video clips provided.

Thank you for this referral. If the clinical or image interpretation does not parallel your findings or if I can be of any further assistance please contact me.

Eric Lindquist, DMV, DABVP(CFM), Cert. IVUSS,
CEO, Owner, Founder -- SonoPath.com
info@SonoPath.com