



## PATIENT

Raffi Smith

## SPECIES

Canine

## BREED

Cavalier King Charles  
Spaniel

## SEX

Female

## AGE

10 years

## WEIGHT

25.9 lbs

## INTERPRETED BY

Eric Lindquist, DMV  
DABVP, Cert. IVUSS

## IMAGING PERFORMED BY

Danielle Shemanski,  
DVM, MA

## HOSPITAL NAME

Western New York VS

## REFERRING VET

Dr. Hauschildt

## INVOICE

70903

## DATE

1/22/26

## PRESENTING CLINICAL SIGNS

- RDVM REASON FOR REFERRAL: Raffealla "Raffi" Smith, a 10-year-old Cavalier King Charles Spaniel, was referred for a suspected lung tumor after a growth on her forepaw and labored breathing prompted chest radiographs. The radiographs showed a 3x4 cm opacity in the left caudal lung lobe, with aspiration pneumonia/infectious bronchopneumonia also considered. Abnormal blood work included elevated neutrophils and white cell count.
- A plan was established to perform an echocardiogram and a thoracic ultrasound, followed by an ultrasound-guided fine needle aspirate (FNA) of the lung mass.
- Monocytosis: 0.54 K/uL (mild) - Neutrophils: 17.2 K/uL (elevated) - White cell count: 20.7 K/uL (elevated)

## ULTRASONOGRAPHIC EXAMINATION

Rapid view of the stomach, liver and spleen revealed no evidence of pathology. A 5.5 x 6.0 cm mineralized lung mass was noted in the left thorax with slight peripheral B lines and air entrapment. This confirms that this is of lung origin. No pleural effusion was noted at the time of the sonogram. The mass may be isolated. The visible planes of the right thorax were unremarkable.

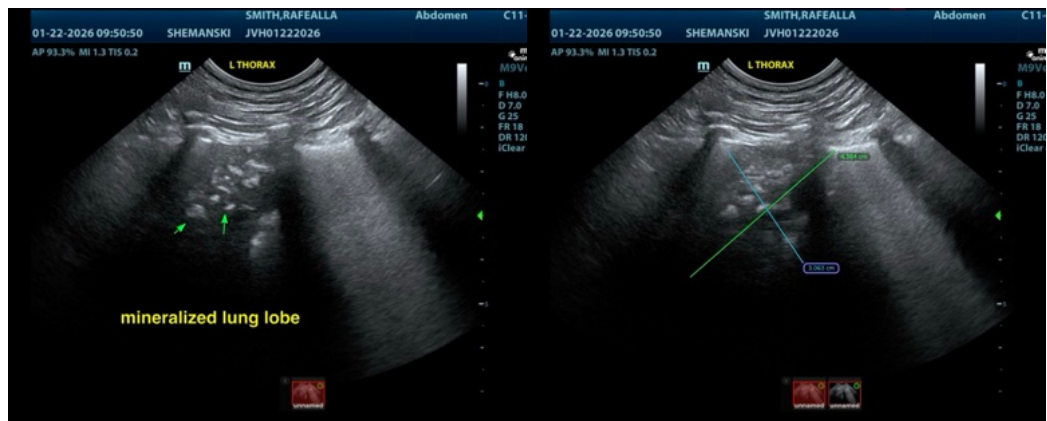
Rapid view of the heart revealed no evidence of volume overload or primary pathology.

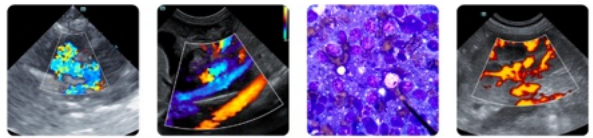
## ULTRASONOGRAPHIC FINDINGS

Left lung mass, mineralizing. Suggestive of carcinoma. Lung necrosis with mineralization is possible, yet less likely. Lung lobe torsion is unlikely as there is a mild amount of vascular presence on color Doppler assessment.

## INTERPRETATION OF THE FINDINGS & FURTHER RECOMMENDATIONS

Ultrasound-guided FNA was performed without complication. CT evaluation for potential surgical planning is indicated.





## PATIENT

Raffi Smith

## SPECIES

Canine

## BREED

Cavalier King Charles  
Spaniel

## SEX

Female

## AGE

10 years

## WEIGHT

25.9 lbs

## INTERPRETED BY

Eric Lindquist, DMV  
DABVP, Cert. IVUSS

## IMAGING PERFORMED BY

Danielle Shemanski,  
DVM, MA

## HOSPITAL NAME

Western New York VS

## REFERRING VET

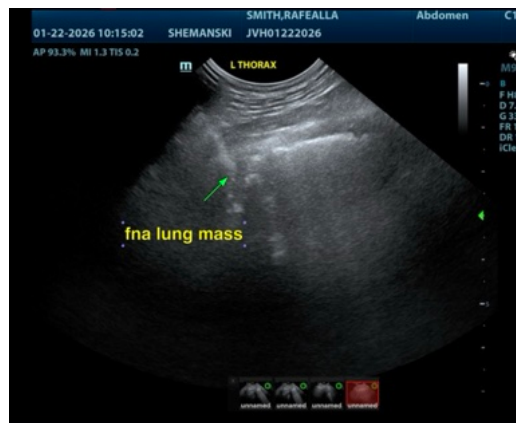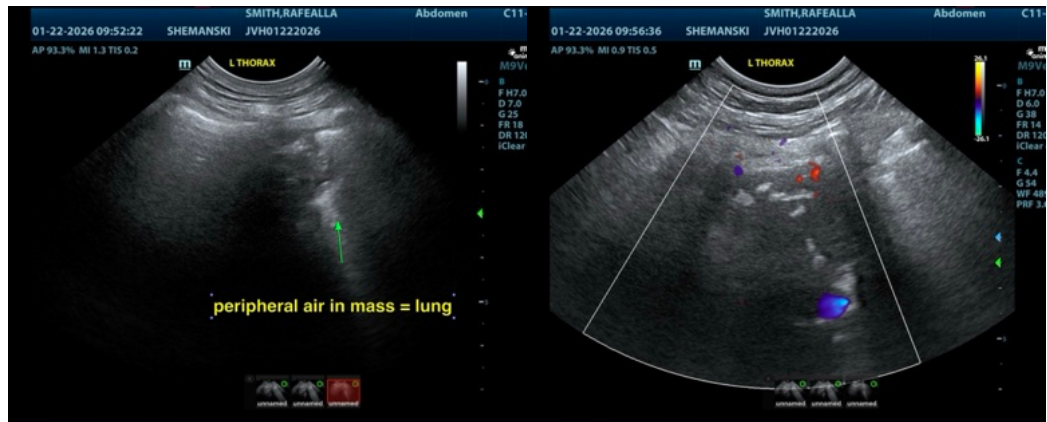
Dr. Hauschildt

## INVOICE

70903

## DATE

1/22/26



The information and recommendations provided are based on the images presented by the referring veterinarian/sonographer. No evaluation can be communicated regarding pathology that was not visible in the image/video clips provided.

Thank you for this referral. If the clinical or image interpretation does not parallel your findings or if I can be of any further assistance please contact me.

Eric Lindquist, DMV, DABVP (CFM), Cert. IVUSS, CEO of SonoPath.com

[info@SonoPath.com](mailto:info@SonoPath.com)