



PATIENT

Luna McDonald

SPECIES

Canine

BREED

Beagle

SEX

Spayed Female

AGE

13 Years

WEIGHT

31 lbs

INTERPRETED BY

Eric Lindquist, DMV,
 DABVP (CFM), Cert.
 IVUSS

IMAGING PERFORMED BY

Dr. Ken Leal

HOSPITAL NAME

Heart & Paw

REFERRING VET

Dr. Caitlin Verhalen

INVOICE

72387

DATE

1/22/26

PRESENTING CLINICAL SIGNS

History of elevated liver enzymes, changes to the spleen and adrenal glands on last ultrasound. History of Grade 3/6 heart murmur. Occasional coughing. Recent breathing seems more labored

Medications: Movoflex, usolyx

Abnormal PE/Chem/CBC/UA Results: 11/18/25: ALT = 136, AlkPhos = 1404, Triglycerides 367. creatinine = 0.47 Remainder NSF.

ULTRASONOGRAPHIC EXAMINATION OF THE HEART & ABDOMEN

CANINE CARDIAC PARAMETERS	MR VMAX (m/s)	TR VMAX (m/s)	LA/AO (M-Mode)	LA/AO (Heart Base; Swe)	FS (%)	EF (%)	EPSS (cm)
NORMAL PARAMETER	4.5-5.5	<2.7	1.3	Up to 1.6	28-40	40-100	<0.6
PATIENT	5.14	--	1.3	1.6	40	71	NM
CANINE CARDIAC PARAMETERS	HR (BPM)	AV VMAX (m/s)	PV MAX (m/s)	BODY WEIGHT (lbs)	LAD LA MAX 4 Chamber	LVIDd Avg; 2D and m-mode short axis (cm)	LVIDs Avg; 2D and m-mode short axis (cm)
NORMAL PARAMETER	50-100	0.7-1.7	0.7-1.6				
PATIENT	90	1.4	1.0	31	3.35	3.4	--

Cardiac Presentation

The echocardiogram in this patient demonstrated normal **left atrial** size based on 3 different LA measurement methods. Chamber volumes and echogenicity were normal. The cranial and caudal **mitral** valve leaflets presented vegetative thickening consistent with endocardiosis. Doppler indicated measurable insufficiency. The **left ventricle** presented thicknesses with linear contour and was not dilated nor restricted. The **myocardium** presented normal echogenicity without subjective evidence of significant fibrotic or ischemic disease. **Contractility** of the ventricular walls was adequate and in normal range for this patient evidenced by the fractional shortening measurement and subjective evaluation of the different regions of the myocardium. The **left ventricular outflow** tract demonstrated normal laminar flow and subjective structural integrity. The **right atrium** and auricle revealed normal size, structure and content. No evidence of masses was noted or chamber overload. **Tricuspid** valvular assessment demonstrated adequate linear morphology. The **right ventricle** was of normal size (1/3 diameter of LV), chordae structure, myocardial echogenicity and thickness. **Pulmonic** tract assessment revealed normal valve structure, laminar flow, and diameter (approx.1:1 pa/ao ratio). No visible **pericardial** or free pleura fluid was noted. No echographically detectable evidence of infiltrative disease was visible. The cranial **mediastinum** and **pericardial** regions were free of masses in the visible window.



PATIENT

Luna McDonald

SPECIES

Canine

BREED

Beagle

SEX

Spayed Female

AGE

13 Years

WEIGHT

31 lbs

INTERPRETED BY

Eric Lindquist, DMV,
DABVP (CFM), Cert.
IVUSS

IMAGING PERFORMED BY

Dr. Ken Leal

HOSPITAL NAME

Heart & Paw

REFERRING VET

Dr. Caitlin Verhalen

INVOICE

72387

DATE

1/22/26

Urinary System

The **urinary bladder**, trigone, and pelvic urethra presented normal thicknesses and normal tone. The ureters were not visible which is normal. No uroliths or sediment were visualized and anechoic urine was present. No evidence of inflammatory or neoplastic changes were noted. Ureteral papillae were normal. The pelvic urethra was imaged 3.0 cm beyond the cystourethral junction.

The **kidneys** revealed largely normal size and structure, corticomedullary definition and ratio (cortex 1/3 of medulla) were essentially maintained with some age-related loss of curvilinear patterns regarding the capsule and C/M junction. The cortices presented largely uniform texture with some increased echogenicity expected for his age patient. Medullary structure differed distinctly from that of the cortex and no evidence of pelvic dilation was present. Slight pinpoint mineralizations noted, non-obstructive. Left kidney measured 5.5 cm. Right kidney measured 6.4 cm.

Adrenal Glands

The **right adrenal gland** presented minor heterogeneous parenchymal changes and slight swollen contour, measuring 1.15 cm at the cranial pole and 0.70 cm at the caudal pole.

The **left adrenal gland** was prominent and presented persistent mineralization at the caudal pole, measuring 2.3 cm in length x 0.74 cm at the caudal pole and 0.57 cm at the cranial pole.

Spleen

The **spleen** presented mild heterogeneous changes, similar to the prior sonogram. No evidence of progression. Hyperechoic nodules noted were most consistent with lipid plaques. Normal splenic size, contour and vascularity.

Liver

The **liver** images from right and left intercostal as well as subcostal views revealed subjectively normal liver size, contour, and structure. Some age-related parenchymal remodeling was noted but likely not clinically significant at this time. Vascular and biliary tracts were of normal volume and no evidence of congestion was noted. The gallbladder presented some dependent debris with essentially normal contour. The cystic and common bile ducts were normal. No overt evidence of active inflammatory, infiltrative or regenerative pathology was noted but should be paired with current or past LE elevations regarding any clinical significance to this presentation. The hepatic lymph nodes were unremarkable.

Gastrointestinal

The **stomach** revealed fluid filled gastric lumen. A slight shadowing structure was noted in the pylorus measuring 1.7 cm. This may be a dissolving medication. Oral medication history should be evaluated. The small intestine and colon were unremarkable.

Pancreas

The base and limbs of the **pancreas** were observed to be largely isoechoic to surrounding omental fat. Some parenchymal remodeling, however, with mild deviation from curvilinear normalcy was observed. Pancreatic duct and capsular irregularities were present consistent with age related changes. If pain upon imaging (+ Murphy sign) was present or if the patient is focally painful in subxyphoid palpation then low-grade smoldering chronic pancreatitis should be suspected.



PATIENT

Luna McDonald

SPECIES

Canine

BREED

Beagle

SEX

Spayed Female

AGE

13 Years

WEIGHT

31 lbs

INTERPRETED BY

Eric Lindquist, DMV,
DABVP (CFM), Cert.
IVUSS

IMAGING PERFORMED BY

Dr. Ken Leal

HOSPITAL NAME

Heart & Paw

REFERRING VET

Dr. Caitlin Verhalen

INVOICE

72387

DATE

1/22/26

ULTRASONOGRAPHIC FINDINGS

- Stage B1 valvular disease, compensated.
- Prominent, upper limits of normal to slightly enlarged adrenal glands – potential emerging PDH.
- Fluid filled gastric lumen with slight shadowing structure in the pylorus, possible medication.
- Benign hepatopathy.
- Mildly heterogeneous spleen.
- Age related renal changes.
- Age related pancreatic remodeling.

INTERPRETATION OF THE FINDINGS & FURTHER RECOMMENDATIONS

The cough is non-cardiogenic in this patient. The cardiac presentation is compensated. The heart is stable without clinical disease. No overt contraindication for anesthesia of brief to moderate duration. I suggest Torbutrol premed, Propofol induction, Isoflor maintenance or similar protocol if anesthesia is desired. Blood pressure, EKG and chest radiographs are recommended if not already performed. Target white coat negative systolic pressure of < 160 mmHg. If higher than this ACE-inhibitor is suggested to reach this level. Recheck echocardiogram is recommended in 6 months, earlier if murmur grade increases or clinical signs initiate.

If the patient appears cushingoid and USG is < 1.020 persistently, then the following workup for Cushing's would be appropriate.

Efficient & Accurate Cushing's Work up-Lindquist

Notes regarding Cushing's Clinical Presentations:

Nearly all Cushing's dogs have SAP elevations and true PU/PD (USG < 1.025) and most are polyphagic. Cushing's dogs are > 6 years and usually > 9 years old, usually have poor skin coats, body scores > 3/5, and are usually sedentary animals.

Its important to remember that Cushing's dogs usually look and play the part and other diseases cause false + stress related cortisol spikes. On rare occasion a Cushing's dog will not follow the rules but this is truly an exception.

Potential Cushing's patient workups can be costly and frustrating if not definitive and, in my experience, the non-definitive patient usually has something else going on that may be contributing to some of the clinical signs a Cushing's dog will have, especially SAP elevations or PU/PD. Based on this prelude of information I came up with the following algorithm in the spirit of diagnostic efficiency.

The following suggested protocol is based on current available literature on Cushing's disease and extensive clinical-sonographic experience evaluation + Cushing's and False + LDDST & ACTH stim. cases in order to maximize the efficiency of a Cushing's workup in practice.

Screen first, workup second

1) **UA:** Repeatable (2-3 urine samples) Urine specific gravity & urine cortisol/creatinine ratio (UCCR): If **repeatable USG < 10.20 and + UCCR** move to next step 2.

Note: UA is inexpensive and easy to obtain and if UA criteria is not met for Cushing's then resources can be spent into other more pertinent diagnostics or left on hold until the UA criteria is met in emerging Cushing's cases.

2) **Sonogram:** Does the patient **have concurrent disease** clinically or sonographically as non-Cushing's illness will influence the potential false + LDDST or even ACTH stim. The sonogram gives a global



PATIENT

Luna McDonald

SPECIES

Canine

BREED

Beagle

SEX

Spayed Female

AGE

13 Years

WEIGHT

31 lbs

INTERPRETED BY

Eric Lindquist, DMV,
DABVP (CFM), Cert.
IVUSS

IMAGING PERFORMED BY

Dr. Ken Leal

HOSPITAL NAME

Heart & Paw

REFERRING VET

Dr. Caitlin Verhalen

INVOICE

72387

DATE

1/22/26

perspective of the internal health of the patient to be considered in the Cushing's workup as an assessment of concurrent disease. Is there a concurrent neoplastic process, UTI pancreatitis, mucocele...? Are the adrenals enlarged (Cushing's-PDH, stress, age related or breed variant), or atrophied (iatrogenic Cushing's or adrenal burnout), have asymmetric enlargement (Adrenal tumor, hyperplasia, adenoma, age related variant), or is there vascular invasion (Invasive pheo with false + UA criteria or adenocarcinoma or phrenic thrombosis)? The sonogram answers these questions proactively.

3) **LDDST** (0.01 D-Sodium phosphate mg/kg IV) (Better screening test but plagued with false +) Use if there is potential early Cushing's or if adrenal asymmetry present on sonogram suspecting tumor. Use LDDST in cats at a higher dose (0.1 mg/kg IV).

OR

4) **ACTH stim.** (Better confirming test but can have false +) Use if the patient "looks" Cushingoid or if bilateral adrenal enlargement is present, or high normal width on sonogram, or if iatrogenic Cushing's suspected (Cortisone Tx in past).

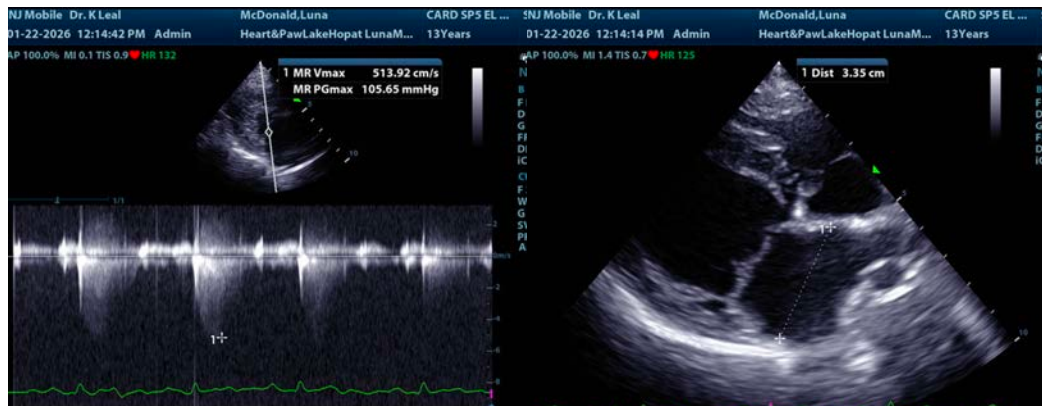
5) If **diabetic** then run both LDDST & ACTH stim.

5) Run a **serial blood pressure** in a BP friendly non "white coat effect" atmosphere. Run at least 3 at different times over a few hours or when eating as the patient tends to be calm when eating or give Torbutrol when entering the facility.

6) **Perform CT** of the pituitary to identify macro adenoma expansion if any lethargy or dullness or other central clinical CNS signs are minimally present.

Suggested reading:

Behrend EN, Kooistra HS, Nelson R, et al. Diagnosis of Spontaneous Canine Hyperadrenocorticism: 2012 ACVIM Consensus Statement (Small Animal). J Vet Intern Med 2013;27:1292-1304.





PATIENT

Luna McDonald

SPECIES

Canine

BREED

Beagle

SEX

Spayed Female

AGE

13 Years

WEIGHT

31 lbs

INTERPRETED BY

Eric Lindquist, DMV,
 DABVP (CFM), Cert.
 IVUSS

IMAGING PERFORMED BY

Dr. Ken Leal

HOSPITAL NAME

Heart & Paw

REFERRING VET

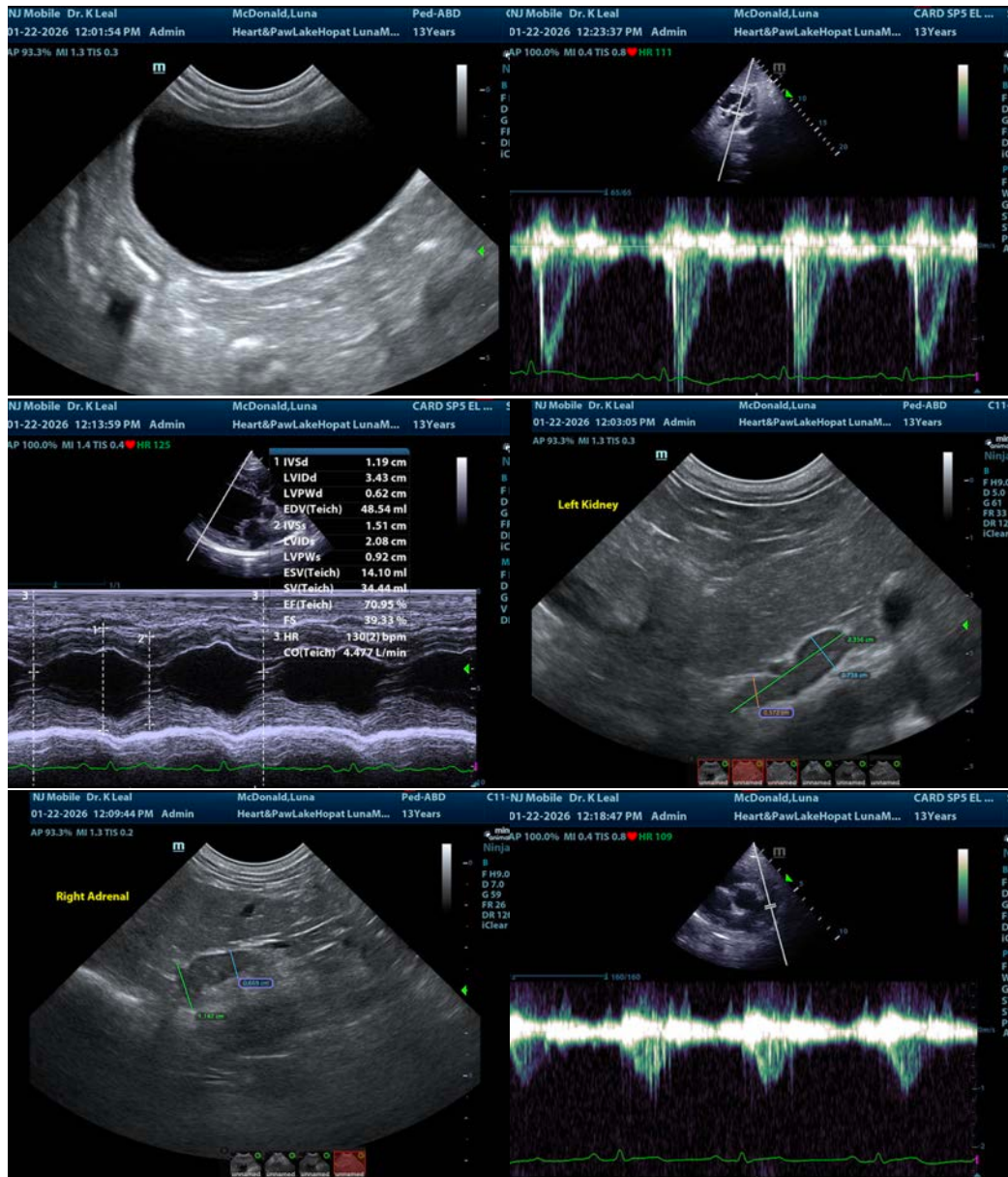
Dr. Caitlin Verhalen

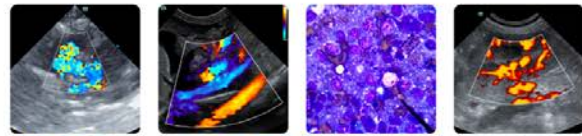
INVOICE

72387

DATE

1/22/26





PATIENT

Luna McDonald

SPECIES

Canine

BREED

Beagle

SEX

Spayed Female

AGE

13 Years

WEIGHT

31 lbs

INTERPRETED BY

Eric Lindquist, DMV,
 DABVP (CFM), Cert.
 IVUSS

IMAGING PERFORMED BY

Dr. Ken Leal

HOSPITAL NAME

Heart & Paw

REFERRING VET

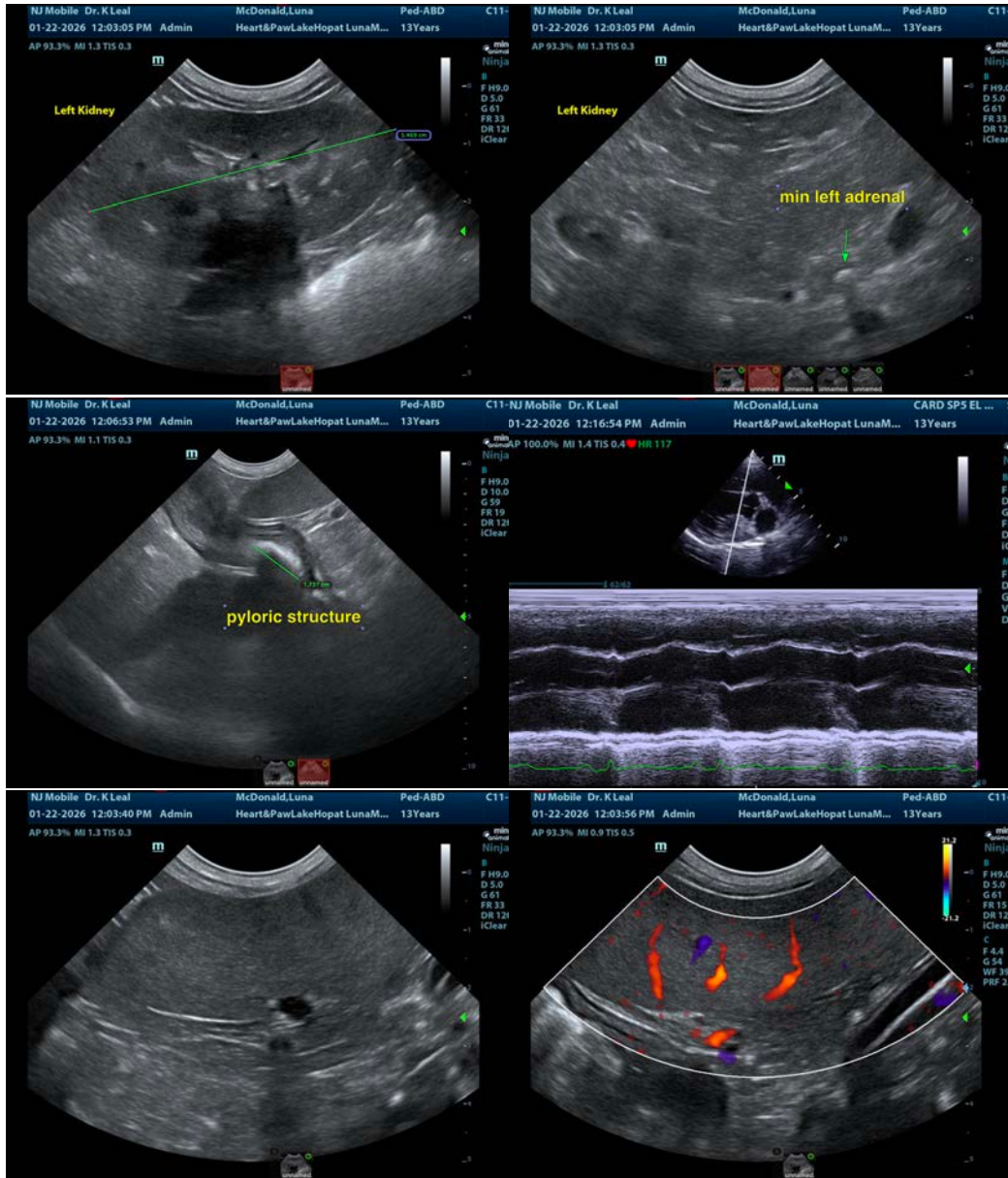
Dr. Caitlin Verhalen

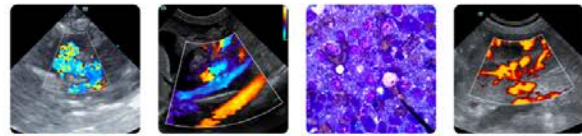
INVOICE

72387

DATE

1/22/26





PATIENT

Luna McDonald

SPECIES

Canine

BREED

Beagle

SEX

Spayed Female

AGE

13 Years

WEIGHT

31 lbs

INTERPRETED BY

Eric Lindquist, DMV,
DABVP (CFM), Cert.
IVUSS

IMAGING PERFORMED BY

Dr. Ken Leal

HOSPITAL NAME

Heart & Paw

REFERRING VET

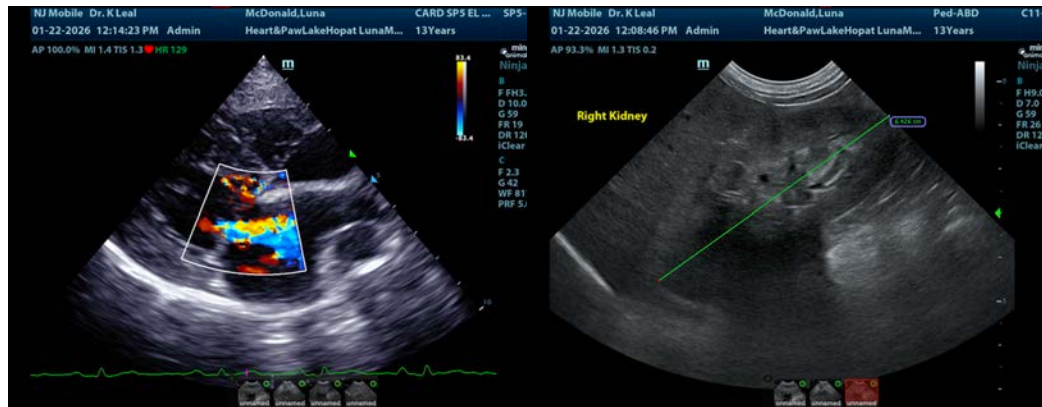
Dr. Caitlin Verhalen

INVOICE

72387

DATE

1/22/26



The information and recommendations provided are based on the images presented by the referring veterinarian/sonographer. No evaluation can be communicated regarding pathology that was not visible in the image/video clips provided.

Thank you for this referral. If the clinical or image interpretation does not parallel your findings or if I can be of any further assistance please contact me.

Eric Lindquist, DMV, DABVP(CFM), Cert. IVUSS,
CEO, Owner, Founder -- SonoPath.com
info@SonoPath.com