



PATIENT

Arlo Breslin

SPECIES

Canine

BREED

Brittany Spaniel

SEX

Neutered male

AGE

12 years

WEIGHT

32 lbs

INTERPRETED BY

Eric Lindquist, DMV
DABVP, Cert. IVUSS

IMAGING PERFORMED BY

Susan Lincoski, VMD

HOSPITAL NAME

Univeristy Drive VH

REFERRING VET

Dr. Lincoski

INVOICE

70893

DATE

1/22/26

PRESENTING CLINICAL SIGNS

- Seen and treated for pneumonia at ER a few weeks ago, noted mild enlarged heart on those radiographs. Cough has resolved, recheck rads taken today-pending. On follow-up exam, owner noted concerns of dog shaking and sometimes collapsing when at rest or minimally active, but he runs and jumps normally. I noted arrhythmia on exam, sinus arrhythmia suspected but given signs could be other issue and related. He is a hunting dog and is highly conditioned. Full orthopedic exam reveals no obvious abnormalities, and no obvious neurologic deficits noted. Admitted today for ecg, echo (and follow up radiographs to ensure pneumonia resolved). A fasted blood glucose was normal, and all labwork at the er visit was normal as well. Other pertinent info: this dog was long ago diagnosed with Diabetes Insipidus, used to get DDAVP but no longer does.
- 2nd degree av block noted on ECG. Got report back mid-echo and administered atropine IV as directed. There are noted repeat view following the heart rate increase.
- Mildly hypotensive 97/47 average but had sedation on board due to disposition so may not be "real"

ULTRASONOGRAPHIC EXAMINATION OF THE HEART

The echocardiogram in this patient demonstrated normal **left atrial** size based on 3 separate methods of LA evaluation. The cranial and caudal **mitral** valve leaflets presented normal linear structure, extension in systole, and union in diastole with normal kinesis. The **left ventricle** presented thicknesses with linear contour and was not dilated nor restricted. The **myocardium** presented normal echogenicity without subjective evidence of significant fibrotic or ischemic disease. **Contractility** of the ventricular walls was adequate and in normal range for this patient evidenced by the fractional shortening measurement and subjective evaluation of the different regions of the myocardium. The **left ventricular outflow** tract demonstrated normal laminar flow and subjective structural integrity. The **right atrium** and auricle revealed normal size, structure and content. No evidence of masses was noted. **Tricuspid** valvular assessment demonstrated adequate linear morphology and kinesis. The **right ventricle** was of normal size (1/3 diameter of LV), chordae structure, myocardial echogenicity and thickness. **Pulmonary outflow** tract assessment revealed normal valve structure, laminar flow, and diameter (approx.1:1 pa/ao ratio). No visible **pericardial** or free pleura fluid was noted. The cranial **mediastinum and pericardial and extra-cardiac regions** were free of masses in the visible window.



PATIENT

Arlo Breslin

SPECIES

Canine

BREED

Brittany Spaniel

SEX

Neutered male

AGE

12 years

WEIGHT

32 lbs

INTERPRETED BY

Eric Lindquist, DMV
DABVP, Cert. IVUSS

IMAGING PERFORMED BY

Susan Lincoski, VMD

HOSPITAL NAME

Univeristy Drive VH

REFERRING VET

Dr. Lincoski

INVOICE

70893

DATE

1/22/26

CANINE CARDIAC PARAMETERS	MR VMAX (m/s)	TR VMAX (m/s)	LA/AO	LA/AO (Heart Base)	FS (%)	EF (%)	EPSS (cm)
NORMAL PARAMETER	4.5-5.5	<2.7	1.3	<1.6	28-40	40-100	<0.6
PATIENT	-	-	NM	NM	45	90	0.3
CANINE CARDIAC PARAMETERS	HR (BPM)	AV VMAX (m/s)	PV MAX (m/s)	BODY WEIGHT	LA 2D short axis Base view (cm)	LVIDd Avg; 2D and m-mode short axis (cm)	LVIDs Avg; 2D and m-mode short axis (cm)
NORMAL PARAMETER	50-100	0.7-1.7	0.7-1.6	BELOW	BELOW	BELOW	BELOW
PATIENT	70	-	0.9	32 lbs	3.7	2.3	

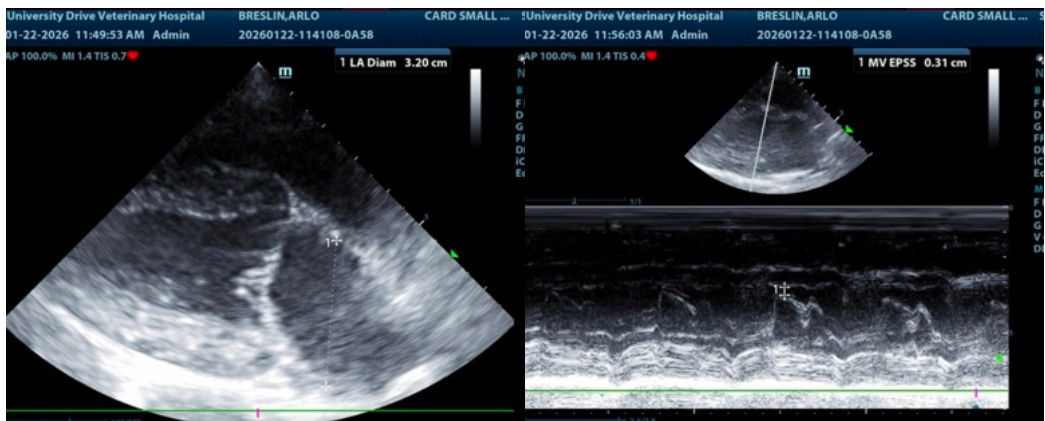
ULTRASONOGRAPHIC FINDINGS

Essentially normal echocardiogram, no evidence of pathology.

Heart has normal volume, structure and function.

INTERPRETATION OF THE FINDINGS & FURTHER RECOMMENDATIONS

The clinical signs are not related to the heart unless paroxysmal arrhythmia is an issue. Holter monitor would be necessary to assess that potential.





PATIENT

Arlo Breslin

SPECIES

Canine

BREED

Brittany Spaniel

SEX

Neutered male

AGE

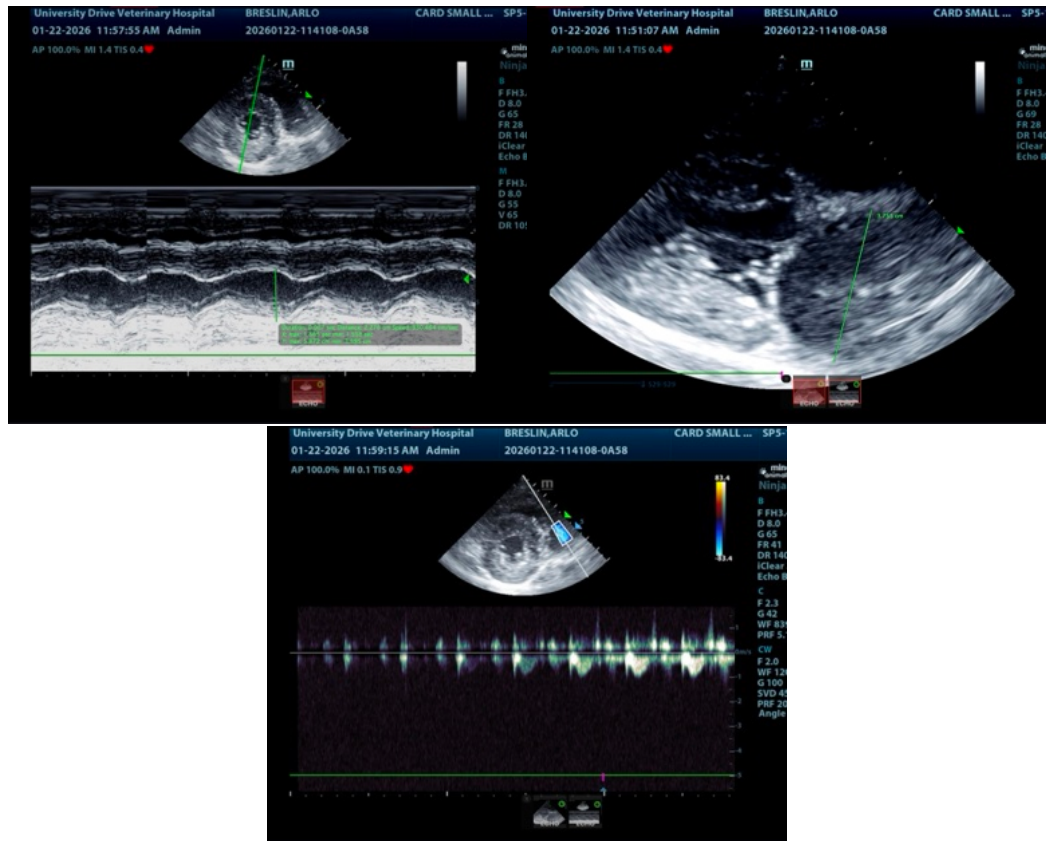
12 years

WEIGHT

32 lbs

INTERPRETED BY

Eric Lindquist, DMV
DABVP, Cert. IVUSS



IMAGING PERFORMED BY

Susan Lincoski, VMD

HOSPITAL NAME

Univeristy Drive VH

REFERRING VET

Dr. Lincoski

INVOICE

70893

DATE

1/22/26

The information and recommendations provided are based on the images presented by the referring veterinarian/sonographer. No evaluation can be communicated regarding pathology that was not visible in the image/video clips provided.

Thank you for this referral. If the clinical or image interpretation does not parallel your findings or if I can be of any further assistance please contact me.

Eric Lindquist, DMV, DABVP (CFM), Cert. IVUSS, CEO of SonoPath.com

info@SonoPath.com