



## PATIENT

Mufasa Smith

## SPECIES

Feline

## BREED

Domestic Shorthair

## SEX

Intact male

## AGE

9 months

## WEIGHT

11.5 lbs

## INTERPRETED BY

Eric Lindquist, DMV  
DABVP, Cert. IVUSS

## IMAGING PERFORMED BY

Dr. Leal

## HOSPITAL NAME

Wellesley AH

## REFERRING VET

Dr. Dean

## INVOICE

70833

## DATE

1/21/26

## PRESENTING CLINICAL SIGNS

- Pt presents for pre-anesthetic screen prior to neuter. No murmur ausculted on exam but pt had an elevated ProBNP on labwork.
- PE: BCS 6/9, two testicles, no murmurs, NSR CBC: NSF Chem: Alb 4.0, Glob 2.8 ProBNP 178 UA: NSF (USG 1.049 T4: 1.8 HW/FIV/FelV: negative

## PRE-ANESTHETIC ECHOCARDIOGRAM

8 efficiency video clips from SDEP protocol provided.

All four chambers revealed normal volumes and contractility. No pericardial or pleural effusion noted. No gross abnormalities that would preclude anesthesia.

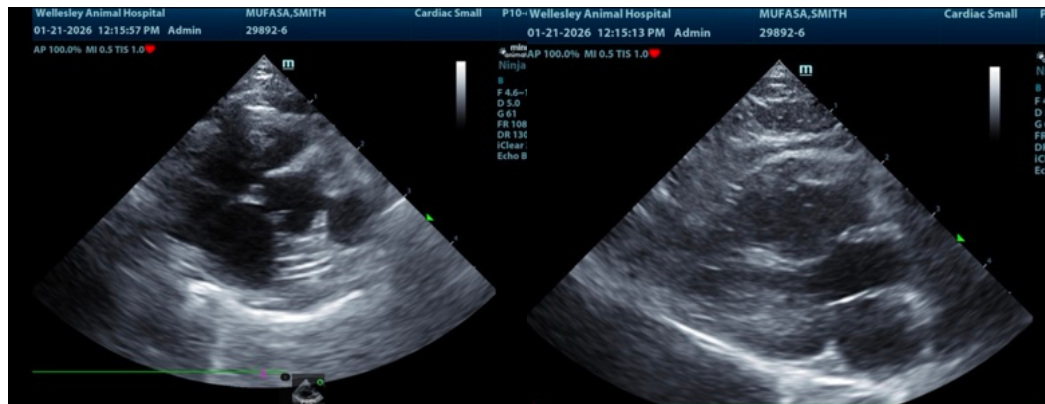
## INTERPRETATION OF THE FINDINGS & FURTHER RECOMMENDATIONS

**Category 1:** Anesthetic risk is considered normal to mild. No gross abnormalities noted on

SDEP Screening Echo to contraindicate anesthesia. Minimal to no left atrial enlargement noted on images presented.

- However, judicious fluid administration is advised with careful RR/RE monitoring to screen for fluid overload.
- Monitoring of blood pressure, SpO<sub>2</sub>, CO<sub>2</sub>, and auscultation of heart and lungs during anesthesia should be done during every procedure.

Note excessive fat was noted around the heart. This may appear as cardiomegaly on radiographs but chamber sizes are normal





## PATIENT

Mufasa Smith

## SPECIES

Feline

## BREED

Domestic Shorthair

## SEX

Intact male

## AGE

9 months

## WEIGHT

11.5 lbs

## INTERPRETED BY

Eric Lindquist, DMV  
DABVP, Cert. IVUSS

## IMAGING PERFORMED BY

Dr. Leal

## HOSPITAL NAME

Wellesley AH

## REFERRING VET

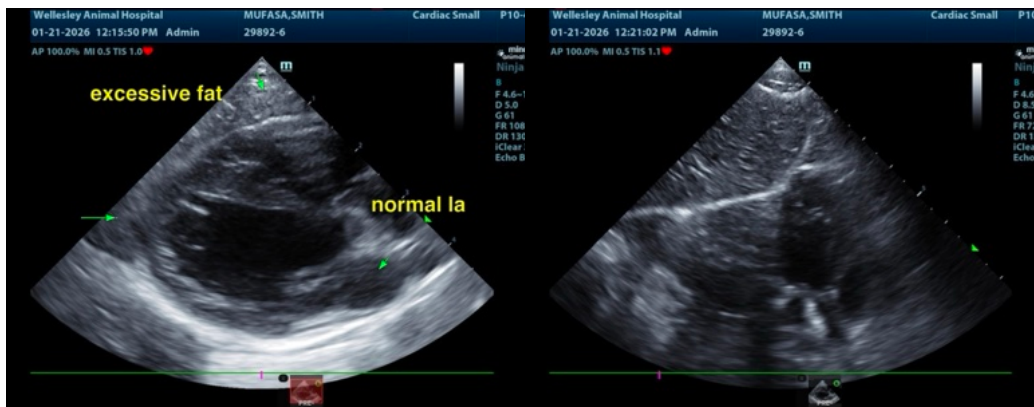
Dr. Dean

## INVOICE

70833

## DATE

1/21/26



The information and recommendations provided are based on the images presented by the referring veterinarian/sonographer. No evaluation can be communicated regarding pathology that was not visible in the image/video clips provided.

Thank you for this referral. If the clinical or image interpretation does not parallel your findings or if I can be of any further assistance please contact me.

Eric Lindquist, DMV, DABVP (CFM), Cert. IVUSS, CEO of SonoPath.com

[info@SonoPath.com](mailto:info@SonoPath.com)