



PATIENT

Max Felsing

SPECIES

Canine

BREED

Labrador

SEX

Neutered male

AGE

11 years

WEIGHT

85 lbs

INTERPRETED BY

Eric Lindquist, DMV
DABVP, Cert. IVUSS

IMAGING PERFORMED BY

Dr. Brenner

HOSPITAL NAME

Riverside Animal Clinic

REFERRING VET

Dr. Brenner

INVOICE

70838

DATE

1/21/26

PRESENTING CLINICAL SIGNS

- Historically normal liver values until Feb 2025, then normal liver when fasted April 2025.
- Clinically normal, stable weight.
- History bilateral TPLO surgeries.
- January 2026 ALT 156 (10-125) history 184, 132. AST 51 (0-50) history 59-54. ALKP 225 (23-212) history normal.

ULTRASONOGRAPHIC EXAMINATION OF THE ABDOMEN

Urinary System

The **urinary bladder**, trigone, and pelvic urethra presented normal thicknesses and normal tone. The pelvic urethra was imaged 2.0 cm beyond the cystourethral junction and appeared normal. The ureters were not visible which is normal. No uroliths or sediment were visualized and anechoic urine was present. No evidence of inflammatory or neoplastic changes was noted. Ureteral papillae were normal.

The **kidneys** revealed normal size and structure, corticomedullary definition and ratio for this age. The cortices presented largely uniform texture with normal echogenic relationship to liver and spleen. Medullary structure differed distinctly from the cortex and no evidence of pelvic dilation was present. The capsules were acceptably uniform without significant irregularities. The right kidney measured 7.47 cm. The left kidney measured 6.09 cm.

Adrenal Glands

Both **adrenal glands** were visualized and recognized as having normal shape, size, position and echogenicity for this breed. The phrenic vasculature, glandular echogenicity and detail were unremarkable. Capsule, cortex, and medullary definition were normal for this age patient. The left adrenal gland measured 2.52 x 0.56 cm at the cranial pole and 0.67 cm at the caudal pole. The right adrenal gland measured 2.09 x 0.53 cm at the cranial pole and 0.46 cm at the caudal pole.

Spleen

The **spleen** was largely smooth with subtle heterogeneous parenchymal changes while maintaining normal echogenic relationship to the liver and kidney. These changes are consistent with normal age-related alteration. The capsule was smooth without noticeable impingement from within the spleen or from pathology in the adjacent abdomen. The splenic vasculature demonstrated normal volume without signs of congestion or significant contraction. No evidence of active acute or chronic inflammatory, neoplastic, or infarctual changes was noted.



PATIENT

Max Felsing

SPECIES

Canine

BREED

Labrador

SEX

Neutered male

AGE

11 years

WEIGHT

85 lbs

INTERPRETED BY

Eric Lindquist, DMV
DABVP, Cert. IVUSS

IMAGING PERFORMED BY

Dr. Brenner

HOSPITAL NAME

Riverside Animal Clinic

REFERRING VET

Dr. Brenner

INVOICE

70838

DATE

1/21/26

Liver

The **liver** images from right and left intercostal as well as subcostal views revealed subjectively normal liver size, contour, and structure. Some age-related parenchymal remodeling was noted but likely not clinically significant at this time. Vascular and biliary tracts were of normal volume and no evidence of congestion was noted. The gallbladder presented some dependent debris with essentially normal contour. The cystic and common bile ducts were normal. No overt evidence of active inflammatory, infiltrative or regenerative pathology was noted but should be paired with current or past LE elevations regarding any clinical significance to this presentation. The hepatic lymph nodes were unremarkable.

Gastrointestinal

Examination of the **gastrointestinal tract** revealed a stomach and intestine free of stasis, of normal wall thickness, acceptable curvilinear mural detail, and peristaltic activity. Small and large intestine demonstrated normal luminal chyme and stool consistency respectively. No obstructive or overt infiltrative disease was noted. No associated abnormal lymphatic activity was noted.

Pancreas

The base and limbs of the **pancreas** were observed to be largely isoechoic to surrounding omental fat. Pancreatic duct and capsular contour were acceptably normal and parenchyma respected normal curvilinear patterns. No overt evidence of active inflammatory or neoplastic disease was noted.

ULTRASONOGRAPHIC FINDINGS

Structurally unremarkable abdomen.

Expected age related changes for this breed.

INTERPRETATION OF THE FINDINGS & FURTHER RECOMMENDATIONS

There was no evidence of significant disease.



PATIENT

Max Felsing

SPECIES

Canine

BREED

Labrador

SEX

Neutered male

AGE

11 years

WEIGHT

85 lbs

INTERPRETED BY

Eric Lindquist, DMV
DABVP, Cert. IVUSS

IMAGING PERFORMED BY

Dr. Brenner

HOSPITAL NAME

Riverside Animal Clinic

REFERRING VET

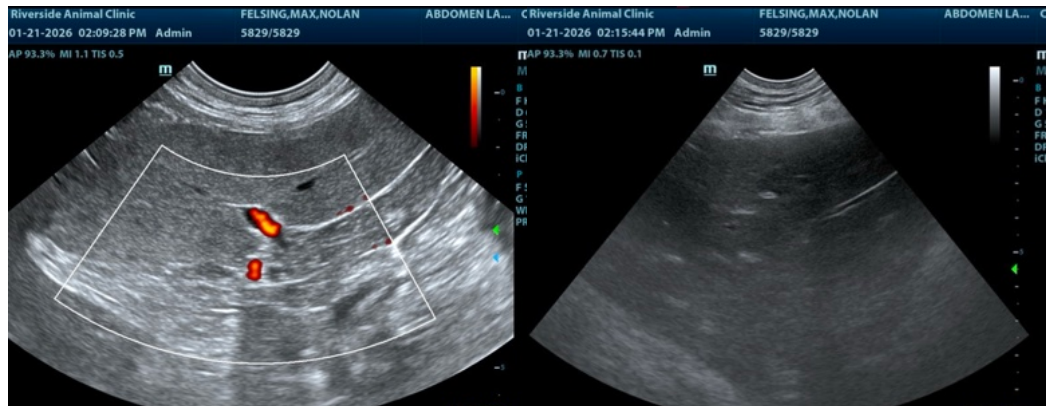
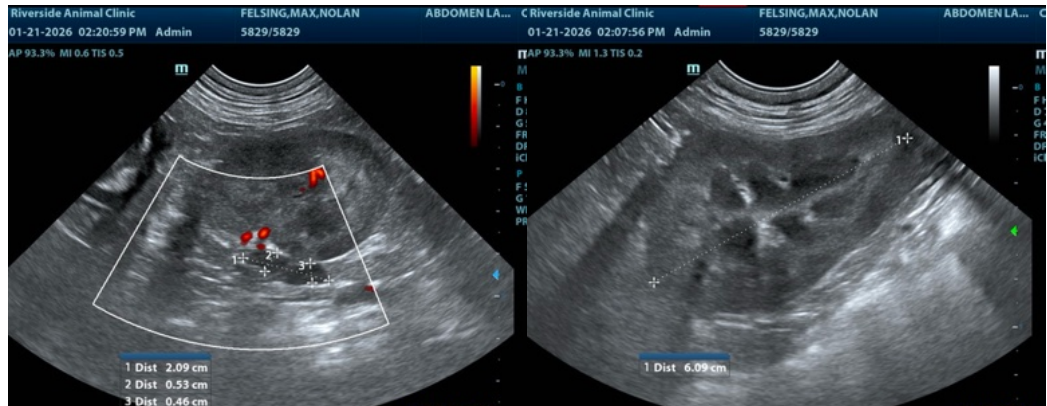
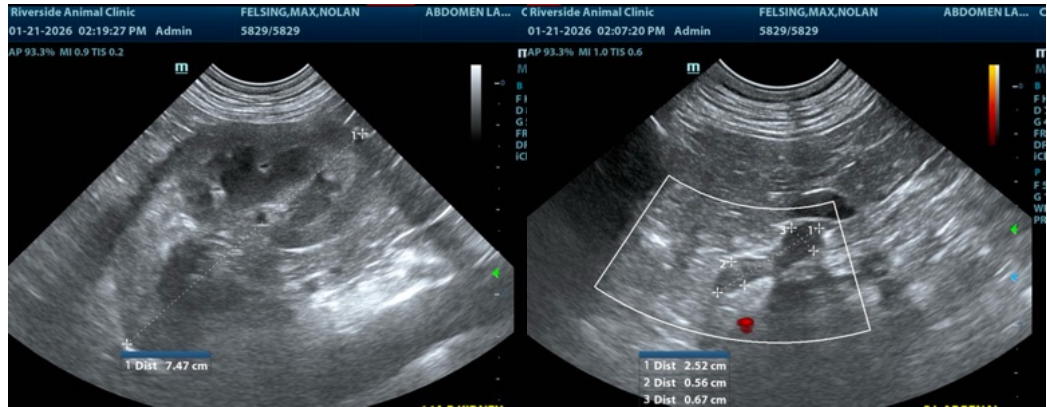
Dr. Brenner

INVOICE

70838

DATE

1/21/26





PATIENT

Max Felsing

SPECIES

Canine

BREED

Labrador

SEX

Neutered male

AGE

11 years

WEIGHT

85 lbs

INTERPRETED BY

Eric Lindquist, DMV
DABVP, Cert. IVUSS

IMAGING PERFORMED BY

Dr. Brenner

HOSPITAL NAME

Riverside Animal Clinic

REFERRING VET

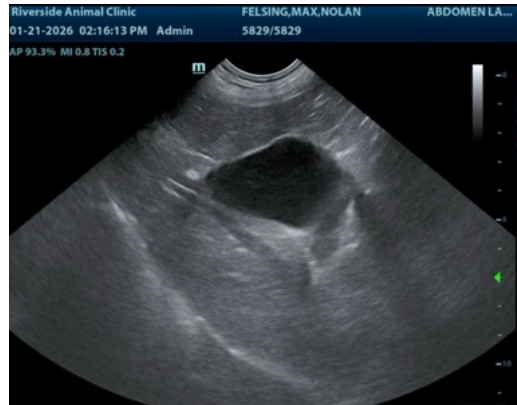Dr. Brenner

INVOICE

70838

DATE

1/21/26



The information and recommendations provided are based on the images presented by the referring veterinarian/sonographer. No evaluation can be communicated regarding pathology that was not visible in the image/video clips provided.

Thank you for this referral. If the clinical or image interpretation does not parallel your findings or if I can be of any further assistance please contact me.

Eric Lindquist, DMV, DABVP (CFM), Cert. IVUSS, CEO of SonoPath.com

info@SonoPath.com