



## PATIENT

Jaspurr Weatherless

## SPECIES

Feline

## BREED

Domestic Shorthair

## SEX

Neutered male

## AGE

10 years

## WEIGHT

22.8 lbs

## INTERPRETED BY

Eric Lindquist, DMV  
DABVP, Cert. IVUSS

## IMAGING PERFORMED BY

Ian Anderson

## HOSPITAL NAME

Chester AC

## REFERRING VET

Dr. Anderson

## INVOICE

70832

## DATE

1/21/26

## PRESENTING CLINICAL SIGNS

- Chronic history of difficult to control diabetes. Currently on prozinc at a dose of 7u BID with the nadir measured at 230 and PU/PD noted at home. Screening for comorbidities complicating diabetic control.
- BCS of 7, unremarkable exam otherwise

## ULTRASONOGRAPHIC EXAMINATION OF THE ABDOMEN

### *Urinary System*

The **urinary bladder**, trigone, and pelvic urethra presented normal thicknesses and normal tone. The ureters were not visible which is normal. No uroliths or sediment were visualized and anechoic urine was present. No evidence of inflammatory or neoplastic changes was noted. Ureteral papillae were normal.

The **kidneys** revealed largely normal structure, corticomedullary definition and ratio (cortex 1/3 of medulla) were essentially maintained with some age-related loss of curvilinear patterns regarding the capsule and C/M junction. The cortices presented largely uniform texture with some increased echogenicity expected for this age patient. Medullary structure differed distinctly from that of the cortex and no evidence of pelvic dilation was present. The kidneys are slightly enlarged in size, which is typical for a diabetic patient. The left kidney measured 5.4 cm. The right kidney measured 5.1 cm.

### *Adrenal Glands*

The left **adrenal gland** was visualized and recognized as having normal shape, size, position and echogenicity for this breed. The phrenic vasculature, glandular echogenicity and detail were unremarkable. Capsule, cortex, and medullary definition were normal for this age patient. The left adrenal gland measured 0.5 cm. The region of the right adrenal gland was imaged with no evidence of pathology.

### *Spleen*

The **spleen** presented a smooth homogeneous parenchyma hyperechoic to liver and renal cortical parenchyma. The capsule was smooth without noticeable expansion or deviation from within the spleen or adjacent pathology. The splenic vasculature demonstrated normal volume without signs of congestion or thrombosis. No sonographic evidence of acute or chronic inflammatory, neoplastic, or infarctual changes was noted.

### *Liver*

The **liver** revealed mild uniform enlargement. The hepatic parenchyma was unremarkable. The gallbladder was unremarkable with no evidence of pathology. This type of hepatic enlargement of this type is common in diabetic patients.



## PATIENT

Jaspurr Weatherless

## SPECIES

Feline

## BREED

Domestic Shorthair

## SEX

Neutered male

## AGE

10 years

## WEIGHT

22.8 lbs

## INTERPRETED BY

Eric Lindquist, DMV  
DABVP, Cert. IVUSS

## IMAGING PERFORMED BY

Ian Anderson

## HOSPITAL NAME

Chester AC

## REFERRING VET

Dr. Anderson

## INVOICE

70832

## DATE

1/21/26

## *Gastrointestinal*

Examination of the **gastrointestinal tract** revealed a stomach and intestine free of stasis, of normal wall thickness, acceptable curvilinear mural detail, and peristaltic activity. Small and large intestine demonstrated normal luminal chyme and stool consistency respectively. No obstructive or overt infiltrative disease was noted. No associated abnormal lymphatic activity was noted.

## *Pancreas*

The base and limbs of the **pancreas** were observed to be largely isoechoic to surrounding omental fat. Pancreatic duct and capsular contour were acceptably normal and parenchyma respected normal curvilinear patterns. No overt evidence of active inflammatory or neoplastic disease was noted.

## ULTRASONOGRAPHIC FINDINGS

Structurally unremarkable abdomen.

Diabetic nephropathy.

Diabetic hepatopathy.

## INTERPRETATION OF THE FINDINGS & FURTHER RECOMMENDATIONS

There was no overt cause of the clinical syndrome.

## Potential Causes of Diabetic Dysregulation

This is a suggestive checkoff list when faced with an unregulated diabetic patient:

UTI

Dietary indiscretion/intolerance

Pancreatitis

Hyperthyroidism/hypothyroidism

Exogenous steroids (including topical eye meds)

Cushing's

Acromegaly

Owner compliance

Insulin quality issues

Antibodies to insulin



## PATIENT

Underlying Neoplasia

Jaspuur Weatherless

Diffuse liver disease

## SPECIES

Feline

Internal medicine consult can be utilized through SonoPath.com. You can select the internal medicine drop down at <http://spa.sonopath.com/>.

## BREED

Domestic Shorthair

One of the world's top internists & SonoPath associate Dr. Remo Lobetti BVSc, MMedVet, PhD, DECVIM can evaluate your case through SonoPath. <https://sonopath.com/resources/sonopath-services/internal-medicine-teleconsultation-services>

## SEX

Neutered male

## AGE

10 years

## WEIGHT

22.8 lbs

## INTERPRETED BY

Eric Lindquist, DMV  
DABVP, Cert. IVUSS

## IMAGING PERFORMED BY

Ian Anderson

## HOSPITAL NAME

Chester AC

## REFERRING VET

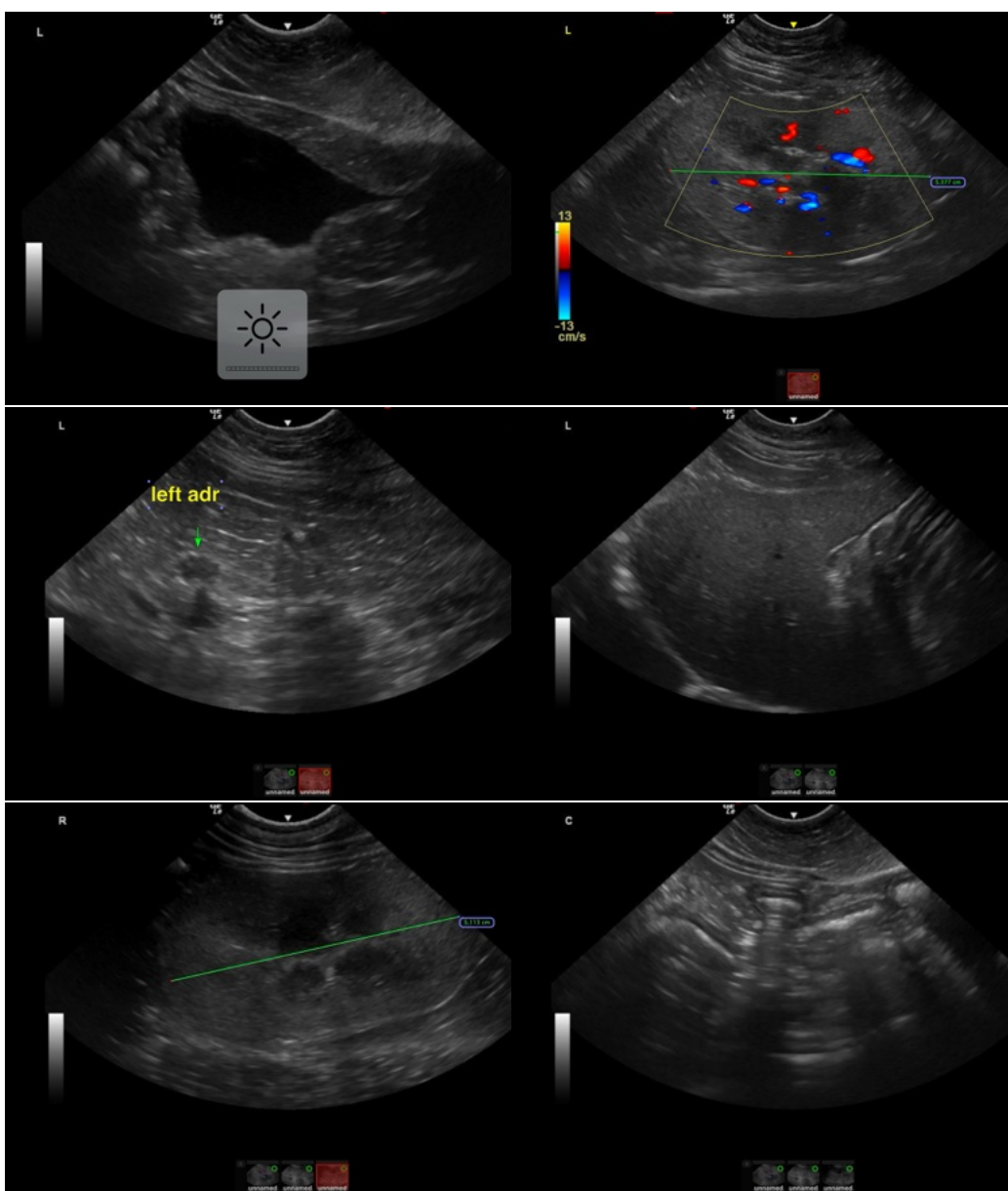
Dr. Anderson

## INVOICE

70832

## DATE

1/21/26





## PATIENT

Jaspurr Weatherless

## SPECIES

Feline

## BREED

Domestic Shorthair

## SEX

Neutered male

## AGE

10 years

## WEIGHT

22.8 lbs

## INTERPRETED BY

Eric Lindquist, DMV  
DABVP, Cert. IVUSS

## IMAGING PERFORMED BY

Ian Anderson

## HOSPITAL NAME

Chester AC

## REFERRING VET

Dr. Anderson

## INVOICE

70832

## DATE

1/21/26

The information and recommendations provided are based on the images presented by the referring veterinarian/sonographer. No evaluation can be communicated regarding pathology that was not visible in the image/video clips provided.

Thank you for this referral. If the clinical or image interpretation does not parallel your findings or if I can be of any further assistance please contact me.

Eric Lindquist, DMV, DABVP (CFM), Cert. IVUSS, CEO of SonoPath.com

[info@SonoPath.com](mailto:info@SonoPath.com)