

**DATE PRESENTING CLINICAL SIGNS**

1/21/22

History: Dog has been exhibiting bouts of sudden voiding large volumes of urine while resting or without any warning. These episodes occur without any type of sequence or patterns but occur at least 2-4 times per week. No visible blood has been seen and dog is not exhibiting any signs of PU/PD. Dog will void normally on a regular basis. The episodes have only developed since her OVH at 6 months of age. Dog had normal OVH without any complications. Dog otherwise acting normal. U/A 10/15/2021 and 12/23/2021 both WNL.

PATIENT

Willow Blahus

SPECIES

Canine

Date of Previous IntraPet Ultrasound: No previous IntraPet scans.

Sedation: Torb.

Stat Report: Not requested.

BREED

Mixed

LIMITED ULTRASONOGRAPHIC EXAMINATION

The urinary bladder was displaced caudally. No evidence of adhesions. However, the pelvic urethra was dilated, suggestive for poor tone. No evidence of ectopic ureters.

SEX

Spayed Female

The kidneys revealed normal size and structure, corticomedullary definition and ratio for this age. The cortices presented largely uniform texture with normal echogenic relationship to liver and spleen. Medullary structure differed distinctly from the cortex and no evidence of pelvic dilation was present. The capsules were acceptably uniform without significant irregularities. The right kidney measured 7.07 cm. The left kidney measured 6.85 cm.

AGE

2/6/21

The uterine stump was unremarkable at 8.0 mm.

WEIGHT

58 Pounds

The descending colon was unremarkable.

INTERPRETED BYEric Lindquist, DMV
DABVP, Cert. IVUSS**ULTRASONOGRAPHIC FINDINGS**

- Poor urethral tone, normal urinary tract otherwise
- Unremarkable uterine stump

IMAGING PERFORMED BY

Andi Parkinson RDMS

INTERPRETATION OF THE FINDINGS & FURTHER RECOMMENDATIONS

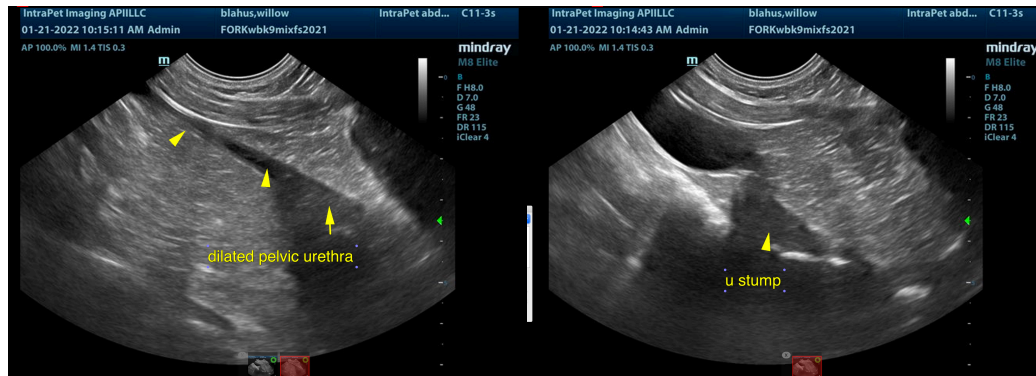
No evidence of ectopic ureters. Likely pelvic bladder and primary incontinence. CT with contrast of the region could also be considered for further definition. However, structurally it appears unremarkable from a sonographic standpoint.

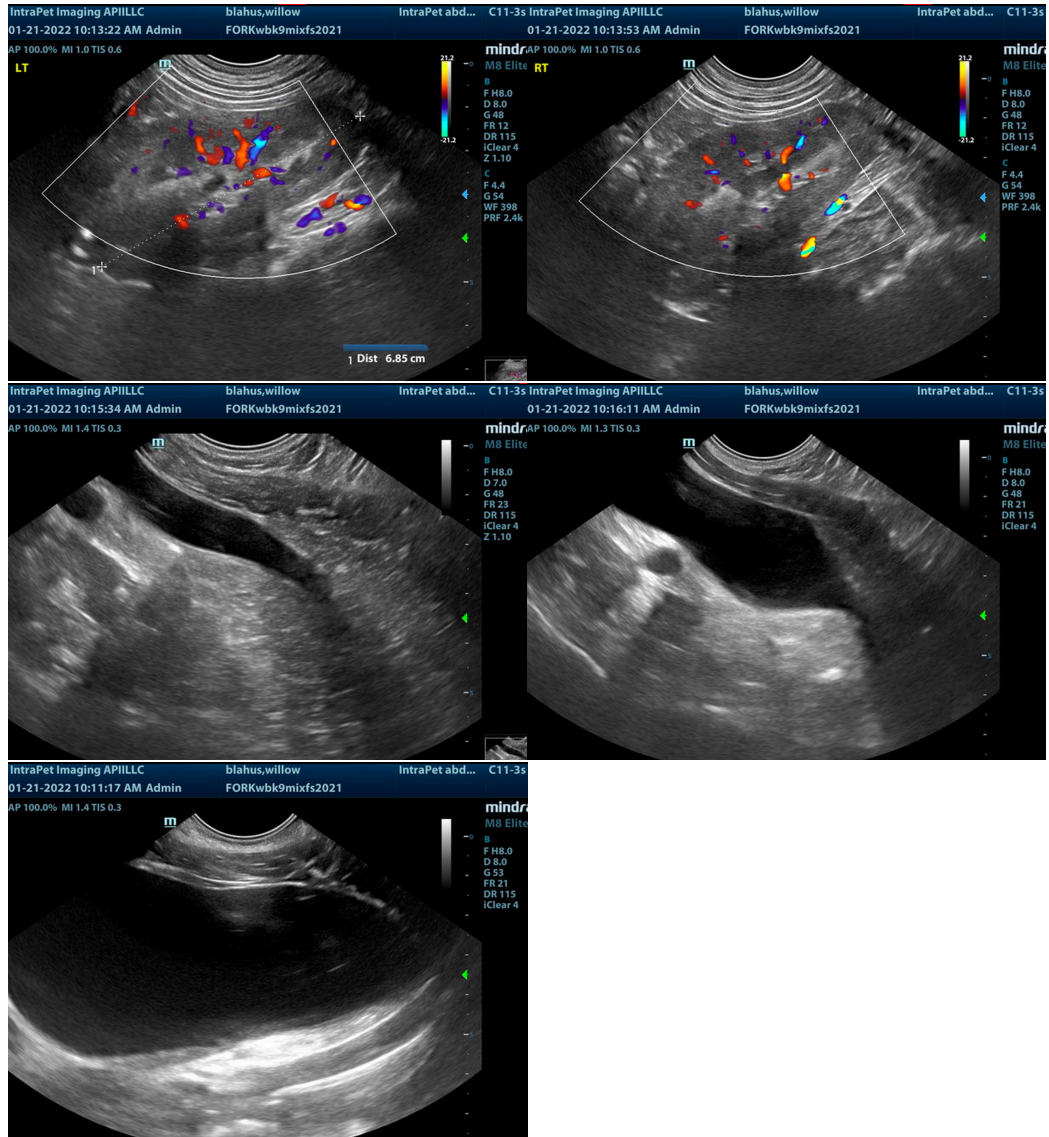
HOSPITAL NAMEFork Veterinary
Hospital**REFERRING VET**

Dr. Doherty

INVOICE

35025





The information and recommendations provided are based on the images presented by the referring veterinarian. No evaluation can be communicated regarding pathology that was not visible in the image/video clips provided.

Thank you for this referral. If the clinical or image interpretation does not parallel your findings or if I can be of any further assistance please contact me.

Eric Lindquist, DMV, DABVP, Cert. IVUSS, CEO of SonoPath.com
info@SonoPath.com