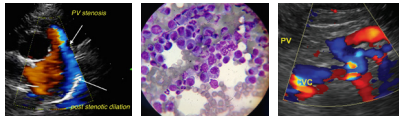


IMAGING PERFORMED BY

IntraPet.com



Clinical Sonography & Telecytology

EDUCATIONAL TELECONSULTATION SERVICES™

1-800-838-4268 info@sonopath.com SonoPath.com

**DATE PRESENTING CLINICAL SIGNS**

1/21/22 History: Dog in good general health, no issues. Cryptorchid male and owner agreed to utilize U/S to determine location of retained testicle.

**PATIENT**

Toby Hollingsworth Date of Previous IntraPet Ultrasound: No previous IntraPet scans.  
Sedation: Not required to complete full diagnostic ultrasound.  
Stat Report: Not requested.

**SPECIES LIMITED ULTRASONOGRAPHIC EXAMINATION**

Canine The urinary bladder, trigone, and pelvic urethra presented normal thicknesses and normal tone. The ureters were not visible which is normal. No uroliths or sediment were visualized and anechoic urine was present. No evidence of inflammatory or neoplastic changes were noted. Ureteral papillae were normal.

**BREED**

Poodle The kidneys revealed normal size and structure, corticomedullary definition and ratio for this age. The cortices presented largely uniform texture with normal echogenic relationship to liver and spleen. Medullary structure differed distinctly from the cortex and no evidence of pelvic dilation was present. The capsules were acceptably uniform without significant irregularities. The right kidney measured 6.04 cm. The left kidney measured 6.95 cm.

**SEX**

Intact Male

**AGE**

8/20/20 The right testicle was retained intraabdominally, measuring 2.04 cm, adjacent to the body wall, approximately 1.0 cm cranial to the urinary bladder at moderate repletion. The left testicle was descended, normal size and contour at 3.33 cm.

**WEIGHT**

48.5 Pounds

**ULTRASONOGRAPHIC FINDINGS**

- Retained right testicle

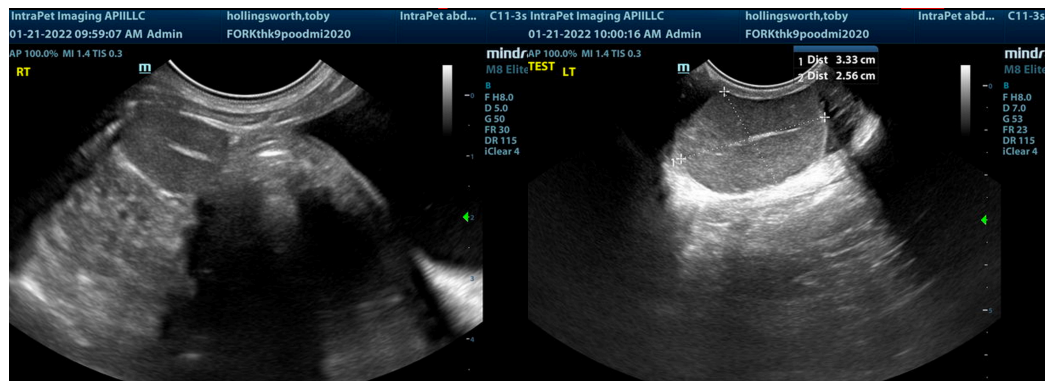
**INTERPRETED BY**

Eric Lindquist, DMV  
DABVP, Cert. IVUSS

**INTERPRETATION OF THE FINDINGS & FURTHER RECOMMENDATIONS**

Surgical removal recommended.

**IMAGING PERFORMED BY**



Andi Parkinson RDMS

**HOSPITAL NAME**

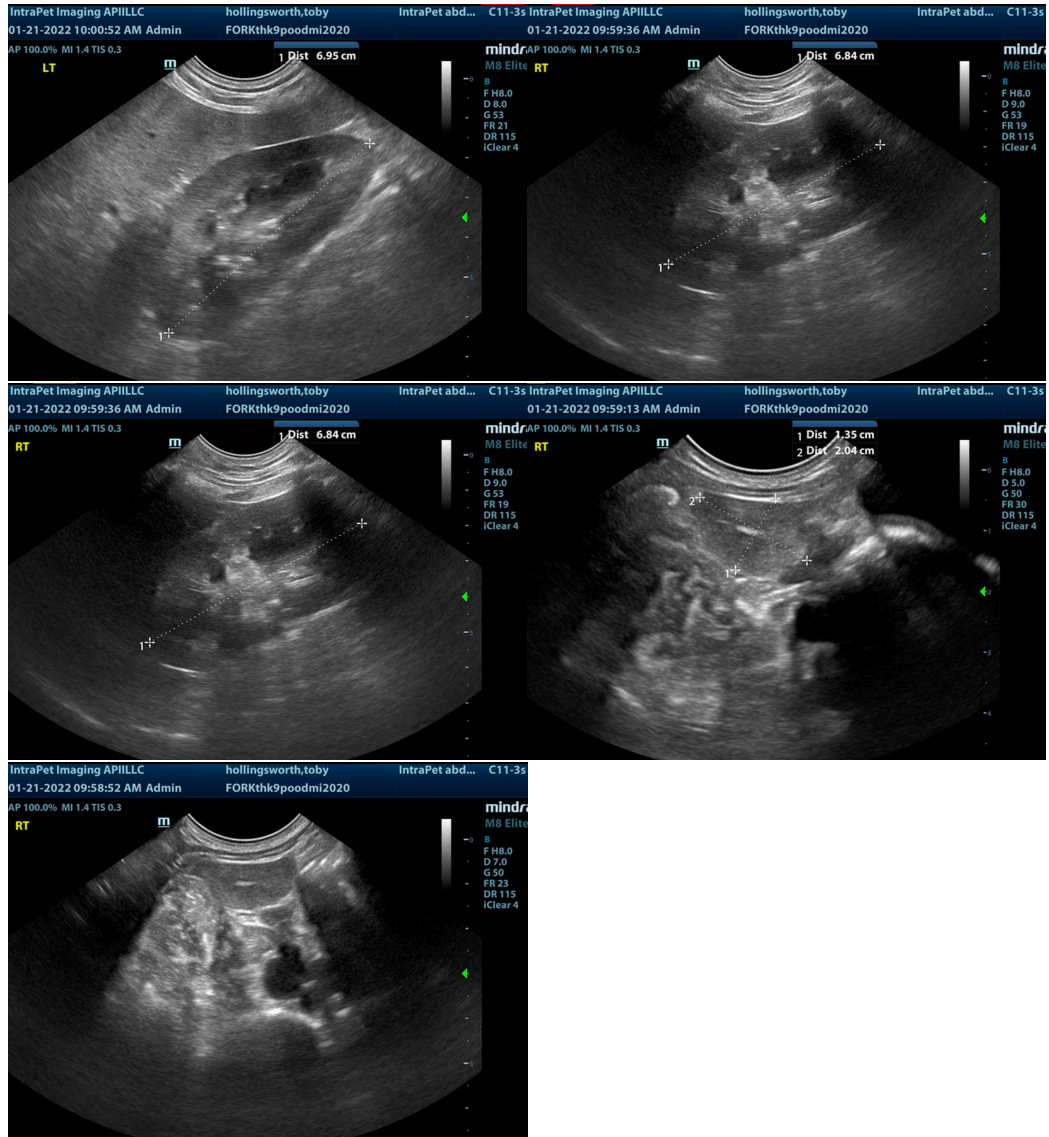
Fork Vet Hospital

**REFERRING VET**

Dr. Doherty

**INVOICE**

35024



The information and recommendations provided are based on the images presented by the referring veterinarian. No evaluation can be communicated regarding pathology that was not visible in the image/video clips provided.

Thank you for this referral. If the clinical or image interpretation does not parallel your findings or if I can be of any further assistance please contact me.

Eric Lindquist, DMV, DABVP, Cert. IVUSS, CEO of SonoPath.com  
[info@SonoPath.com](mailto:info@SonoPath.com)