



PATIENT PRESENTING CLINICAL SIGNS

Teddie Pedrazzi History: recheck for PDA confirmation

SPECIES ULTRASONOGRAPHIC EXAMINATION OF THE HEART

Canine

BREED

German Shepherd

SEX

Intact Male

AGE

1 Year

WEIGHT

99 Lbs.

CANINE CARDIAC PARAMETERS	MR VMAX (m/s)	TR VMAX (m/s)	LA/AO (Boon method)	LA/AO (Heart Base; Swe)	FS (%)	EF (%)	EPSS (cm)
NORMAL PARAMETER	4.5-5.5	<2.7	1.3	<1.6	28-40	40-100	<0.6
PATIENT			1.25	1.21	31	59	0.1
CANINE CARDIAC PARAMETERS	HR (BPM)	AV VMAX (m/s)	PV MAX (m/s)	BODY WEIGHT (kg)	LA 2D short axis Base view (cm)	LVIDd Avg; 2D and m-mode short axis (cm)	LVIDs Avg; 2D and m-mode short axis (cm)
NORMAL PARAMETER	50-100	0.7-1.7	0.7-1.6	BELOW	BELOW	BELOW	BELOW
PATIENT	153	3.56		--	4.73	5.18	--

Cardiac Presentation

The echocardiogram in this patient demonstrated normal **left atrial** size based on 3 separate methods of LA evaluation. Trivial mitral insufficiency noted, not clinically significant. The **left ventricle** presented thicknesses with linear contour and was not dilated nor restricted. Aortic outflow velocity was excessive at 3.56 m/s with secondary aortic insufficiency at 4.10 m/s. Systolic turbulence noted in the aortic outflow with secondary aortic insufficiency consistent with subaortic stenosis, however, some of the excessive velocity may be compensatory owing to the PDA. The **myocardium** presented normal echogenicity without subjective evidence of significant fibrotic or ischemic disease. **Contractility** of the ventricular walls was adequate and in normal range for this patient evidenced by the fractional shortening measurement and subjective evaluation of the different regions of the myocardium. The **left ventricular outflow** tract demonstrated normal laminar flow and subjective structural integrity. The **right atrium** and auricle revealed normal size, structure and content. No evidence of masses was noted. **Tricuspid** valvular assessment demonstrated adequate linear morphology and kinesis. The **right ventricle** was of normal size (1/3 diameter of LV), chordae structure, myocardial echogenicity and thickness. No visible **pericardial** or free pleura fluid was noted. The cranial **mediastinum and pericardial and extra-cardiac regions** were free of masses in the visible window. Deep pulmonary artery revealed holosystolic jet. Holosystolic flow noted both on spectral and color flow doppler in the deep pulmonary artery, consistent with patent ductus arteriosus. Minor pulmonic insufficiency noted.

ULTRASONOGRAPHIC FINDINGS

- Patent ductus arteriosus with mild to moderate subaortic stenosis or compensatory elevated outflow velocity owing to PDA

INTERPRETED BY

Eric Lindquist, DMV DABVP, Cert. IVUSS

IMAGING PERFORMED BY

Diane McFadden

HOSPITAL NAME

Rockaway AH

REFERRING VET

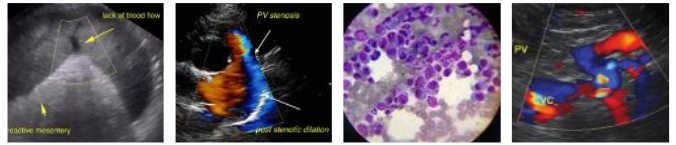
Dr. Maniar

INVOICE

13545

DATE

1/21/22



PATIENT

Teddie Pedrazzi

INTERPRETATION OF THE FINDINGS & FURTHER RECOMMENDATIONS

Referral for cardiologist intervention.

SPECIES

Canine

BREED

German Shepherd

SEX

Intact Male

AGE

1 Year

WEIGHT

99 Lbs.

INTERPRETED BY

Eric Lindquist, DMV
DABVP, Cert. IVUSS

IMAGING PERFORMED BY

Diane McFadden

HOSPITAL NAME

Rockaway AH

REFERRING VET

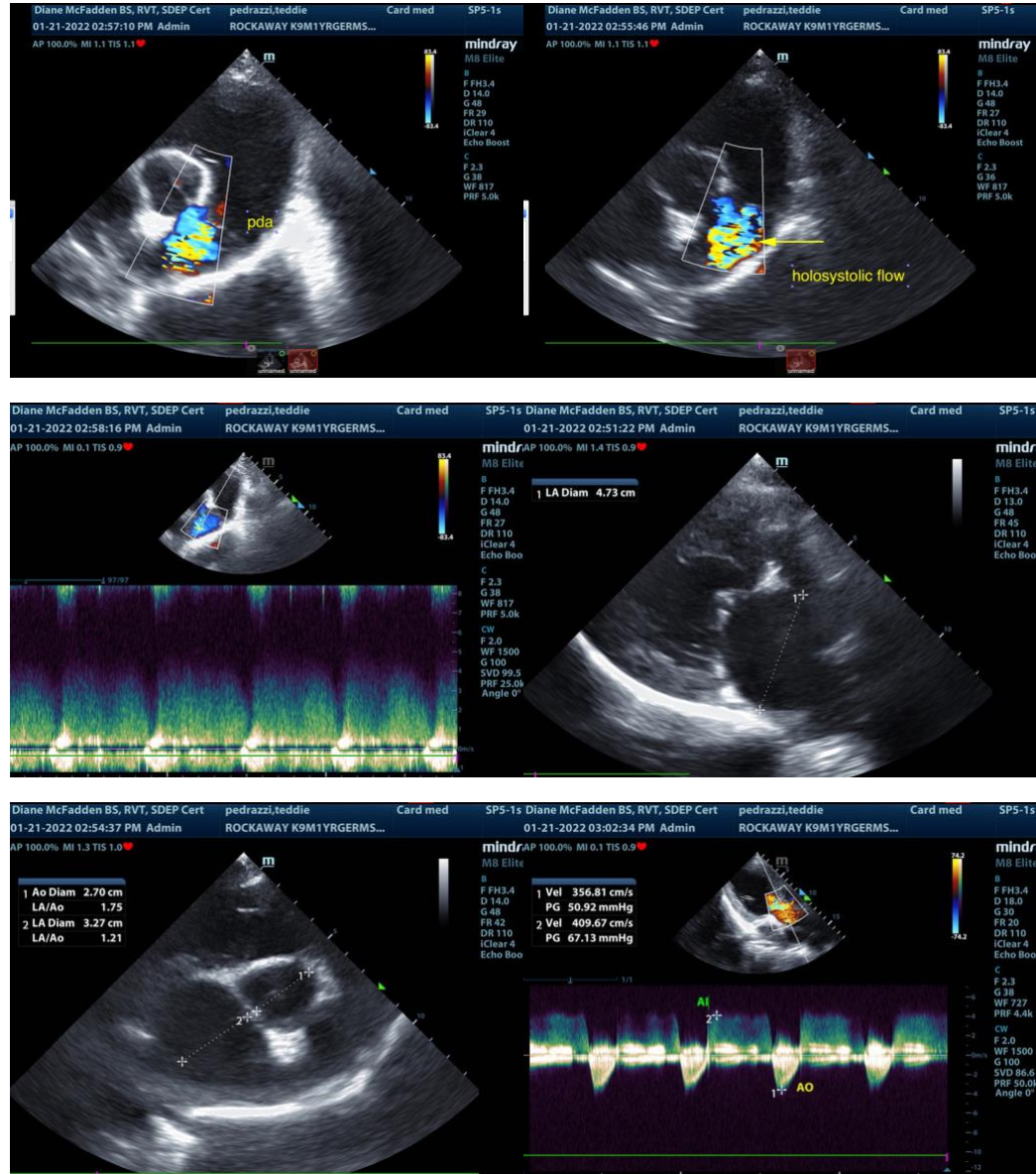
Dr. Maniar

INVOICE

13545

DATE

1/21/22





PATIENT

Teddie Pedrazzi

SPECIES

Canine

BREED

German Shepherd

SEX

Intact Male

AGE

1 Year

WEIGHT

99 Lbs.

INTERPRETED BY

Eric Lindquist, DMV
DABVP, Cert. IVUSS

IMAGING PERFORMED BY

Diane McFadden

HOSPITAL NAME

Rockaway AH

REFERRING VET

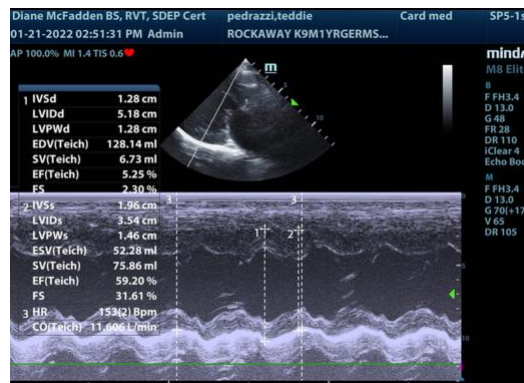
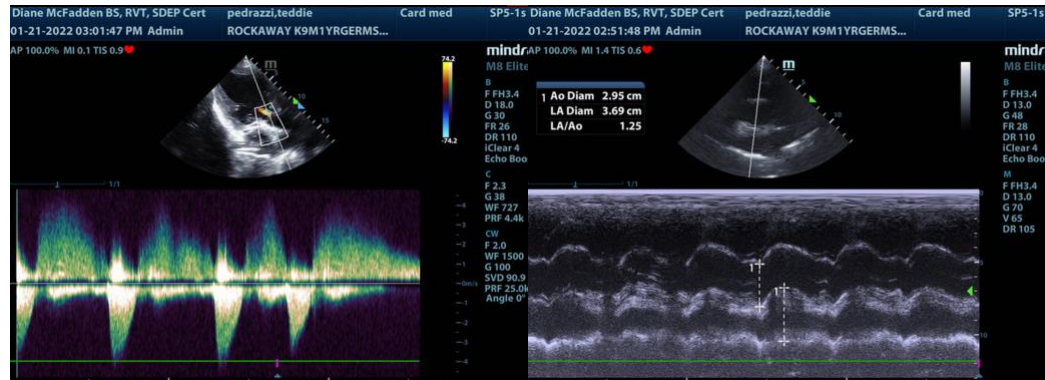
Dr. Maniar

INVOICE

13545

DATE

1/21/22



The information and recommendations provided are based on the images presented by the referring veterinarian. No evaluation can be communicated regarding pathology that was not visible in the image/video clips provided.

Thank you for this referral. If the clinical or image interpretation does not parallel your findings or if I can be of any further assistance please contact me.

Eric Lindquist, DMV, DABVP, Cert. IVUSS, CEO of SonoPath.com
info@SonoPath.com

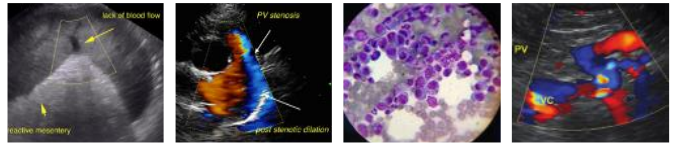
Patent Ductus Arteriosus

<http://www.sonopath.com/PDA>

<http://www.sonopath.com/PDAReversal>

<http://www.sonopath.com/EchoModler>

Description: Patent ductus arteriosus (PDA) is a common congenital heart defect in dogs and most commonly affects toy breeds. The PDA is graded on a scale of 1 to 6 based on the degree of asymmetric



PATIENT

Teddie Pedrazzi

SPECIES

Canine

BREED

German Shepherd

SEX

Intact Male

AGE

1 Year

WEIGHT

99 Lbs.

INTERPRETED BY

Eric Lindquist, DMV
DABVP, Cert. IVUSS

**IMAGING
PERFORMED BY**

Diane McFadden

HOSPITAL NAME

Rockaway AH

REFERRING VET

Dr. Maniar

INVOICE

13545

DATE

1/21/22

distribution of the smooth muscle architecture, which varies from funnel to tube-like structures. The more the smooth muscle architecture of the duct resembles the aortic wall, the higher the pathological grade. The physiologic closure of the ductus arteriosus is dictated by the cessation of prostaglandin negative feedback during partus, together with an increased oxygen tension. If the negative feedback and increased oxygen tension are prevented from occurring, the ductus arteriosus will remain open, resulting in a PDA.

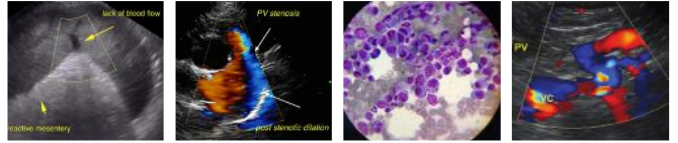
Clinical Signs: A continuous machinery murmur located at the heart base and heard at the left 3rd intercostal space is typical for a PDA. The intensity of the murmur depends on the grade of the PDA, with a grade 6 PDA exhibiting a lower grade murmur than a grade 1 PDA. Additional signs include a mitral systolic murmur, bounding hyperkinetic femoral pulses, and a precordial thrill, which is palpated on the thoracic wall at the level of the heart base. Secondary pulmonary hypertension can develop, which can result in the murmur becoming more faint as right-to-left shunting occurs. Right-to-left reversal of the shunt results in exercise intolerance, caudal mucosal cyanosis, and polycythemia.

Diagnostics: Radiography may show cardiomegaly, which can stem from an enlarged pulmonary artery, left atrium, or left ventricle, and a prominent aortic arch. In some cases of PDA, the main pulmonary artery is distended and an increased vascular pattern is present. In other cases, radiographic changes may be undetectable, especially if the defect is small or volume overload is absent. In advanced stages, pulmonary edema due to congestive heart failure (CHF) can be present.

ECG findings include tall R waves consistent with left ventricular enlargement and occasionally wide P waves. In advanced cases, atrial fibrillation may be evident. NT-proBNP levels may also be elevated. One study showed a median value of 742 pmol/L in dogs with PDA compared to a median value of 333 pmol/L in healthy dogs.

Echocardiography is the best way of diagnosing a PDA, which typically shows high velocity turbulence and continuous flow in the deep pulmonary artery prior to its bifurcation on color flow and continuous wave Doppler. Occasionally, severe pulmonary hypertension results in the reversal of flow to a right-to-left shunt. If a right-to-left PDA is suspected, a bubble study of the heart and abdominal aorta can be performed. If bubbles are seen in the abdominal aorta, then a reverse PDA would be confirmed.

Treatment: Treatment options include surgical ligation or a less invasive procedure—fluoroscopy-guided occlusion with a coil or a duct occluder. Possible negative consequences of the former include a rupture of the duct, whereas the latter carries the risk of coil migration and embolization in the pulmonary artery. Early repair is essential for long-term survival even though some dogs will survive for years with medical management alone. Closure of the defect is the optimal and most effective solution. The best surgical survival rates are found in younger dogs before significant morphological cardiac changes occur and prior to the development of major arrhythmogenic activity. Medical management is best determined by echocardiographic and clinical findings. In the future, a new technique may become available that would allow for the closure of the duct via thoracoscopy.



PATIENT

Teddie Pedrazzi

SPECIES

Canine

BREED

German Shepherd

SEX

Intact Male

AGE

1 Year

WEIGHT

99 Lbs.

INTERPRETED BY

Eric Lindquist, DMV
DABVP, Cert. IVUSS

**IMAGING
PERFORMED BY**

Diane McFadden

HOSPITAL NAME

Rockaway AH

REFERRING VET

Dr. Maniar

INVOICE

13545

DATE

1/21/22

References:

- Broaddus KD, Tillson DM. Patent ductus arteriosus in dogs. *Comp Con Educ Prac Vet* 2010;32:1-14.
- Bureau S, Monnet E, Orton EC. Evaluation and survival rate and prognostic indicators for surgical treatment of left-to-right patent ductus arteriosus in dogs: 52 cases (1995-2003). *JAVMA* 2005;227:1794-99.
- Fossum TW. *Small Animal Surgery, 3rd ed.* St. Louis: Mosby Elsevier; 2007:784-89.
- Hogan DF, Green HW, Gordon S, Miller MW. Transarterial coil embolization of patent ductus arteriosus in small dogs with 0.025-inch vascular occlusion coils: 10 cases. *J Vet Int Med* 2004;18:325-29.
- Miller MW, Gordon SG, Saunders AB, Arsenault WG, Meurs KM, Lehmkuhl LB, Bonagura JD, Fox PR. Angiographic classification of patent ductus arteriosus morphology in the dog. *J Vet Cardiol* 2006;8:109-14.
- Rossi M, Rebonato A, Greco L, Stefanini G, Citone M, Speranza A, David V. A new device for vascular embolization: report on case of two pulmonary arteriovenous fistulas embolization using the Amplatzer vascular plug. *Cardiovasc Intervent Radiol* 2006;29:902-06.
- Schneider M, Schneider I, Hildebrandt N, Wehner M. Percutaneous angiography of patent ductus arteriosus in dogs: techniques, results and implications for intravascular occlusion. *J Vet Cardiol* 2003;5:21-27.