



PATIENT

Raven Pluchino

SPECIES

Canine

BREED

Shetland Sheepdog

SEX

Spayed Female

AGE

5 Years

WEIGHT

Not provided

INTERPRETED BY

Eric Lindquist, DMV
DABVP, Cert. IVUSS

IMAGING PERFORMED BY

Kelly Vasquez

HOSPITAL NAME

Ringwood AH

REFERRING VET

Dr. Jamie DeSpirito

INVOICE

13546

DATE

1/21/22

PRESENTING CLINICAL SIGNS

History: History of gallbladder sludge, was on Ursodial but has been off for awhile. Ultrasound to assess current state of gallbladder and if Ursodial should be re-started. No current meds. Bloods WNL.

ULTRASONOGRAPHIC EXAMINATION OF THE ABDOMEN

Urinary System

The **urinary bladder**, trigone, and pelvic urethra presented normal thicknesses and normal tone. The ureters were not visible which is normal. No uroliths or sediment were visualized and anechoic urine was present. No evidence of inflammatory or neoplastic changes were noted. Ureteral papillae were normal.

The **kidneys** revealed normal size and structure, corticomedullary definition and ratio for this age. The cortices presented largely uniform texture with normal echogenic relationship to liver and spleen. Medullary structure differed distinctly from the cortex and no evidence of pelvic dilation was present. The capsules were acceptably uniform without significant irregularities. The right kidney measured 4.24 cm. The left kidney measured 4.8 cm. The left kidney appears to be stable.

Adrenal Glands

The regions of the **adrenal glands** revealed no evident pathology.

Spleen

The **spleen** presented a smooth homogeneous parenchyma hyperechoic to liver and renal cortical parenchyma. The capsule was smooth without noticeable expansion or deviation from within the spleen or adjacent pathology. The splenic vasculature demonstrated normal volume without signs of congestion or thrombosis. No sonographic evidence of acute or chronic inflammatory, neoplastic, or infarctual changes were noted.

Liver

The **liver** revealed slight uniform enlargement. Parenchyma was unremarkable. The **gallbladder** long axis measured 5.45 cm x 2.5 cm with coalesced debris. The debris was mildly excessive not to the level of mucocele formation.

Gastrointestinal

Examination of the **gastrointestinal tract** revealed a stomach and intestine free of stasis, of normal wall thickness, acceptable curvilinear mural detail, and peristaltic activity. Small and large intestine demonstrated normal luminal chyme and stool consistency respectively. No obstructive or overt infiltrative disease was noted. No associated abnormal lymphatic activity was noted.

Pancreas

The base and limbs of the **pancreas** were observed to be largely isoechoic to surrounding omental fat. Pancreatic duct and capsular contour were acceptably normal and parenchyma respected normal curvilinear patterns. No overt evidence of active inflammatory or neoplastic disease was noted.

ULTRASONOGRAPHIC FINDINGS

- Minor excessive gallbladder debris/sludge- not to the level of mucocele formation



PATIENT

Raven Pluchino

SPECIES

Canine

BREED

Shetland Sheepdog

SEX

Spayed Female

AGE

5 Years

WEIGHT

Not provided

INTERPRETED BY

Eric Lindquist, DMV
DABVP, Cert. IVUSS

IMAGING PERFORMED BY

Kelly Vasquez

HOSPITAL NAME

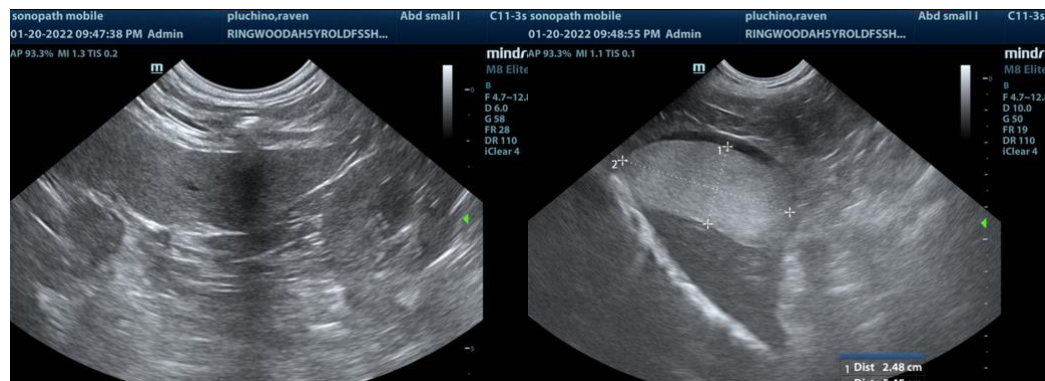
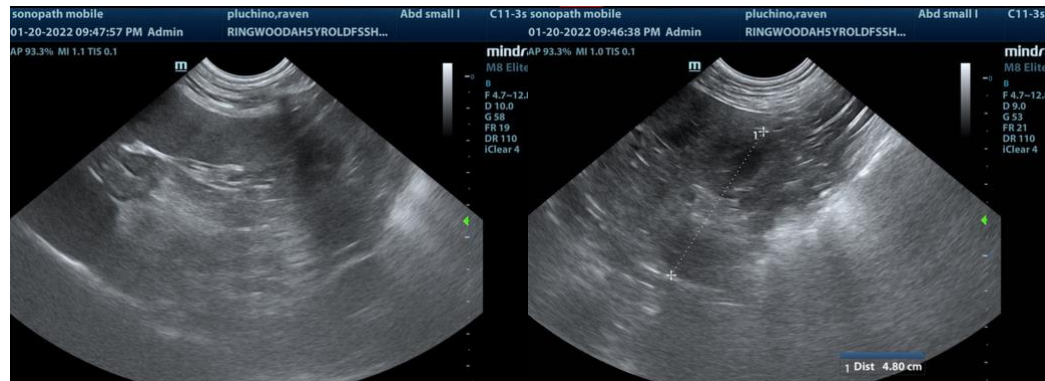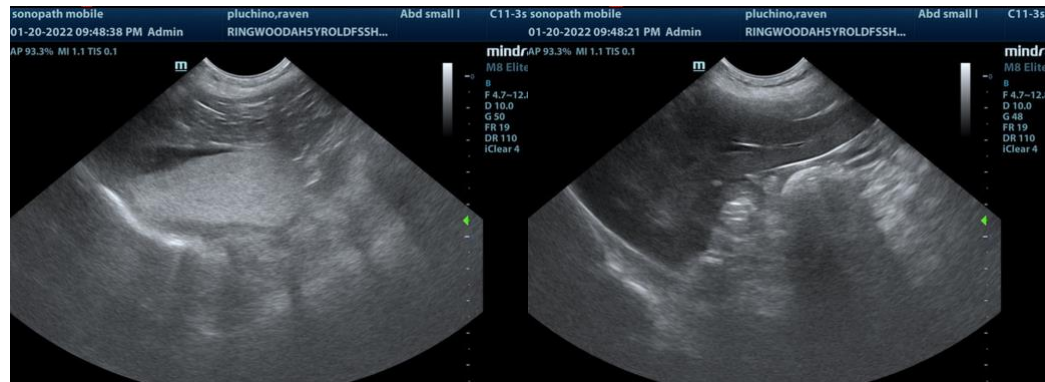
Ringwood AH

REFERRING VET

Dr. Jamie DeSpirito

INTERPRETATION OF THE FINDINGS & FURTHER RECOMMENDATIONS

Given the patient history, I recommended continuation of ursodiol in this patient, given the breed predisposition of mucocele formation. The gallbladder debris is essentially similar to the prior sonogram.



INVOICE

13546

DATE

1/21/22



PATIENT

Raven Pluchino

SPECIES

Canine

BREED

Shetland Sheepdog

SEX

Spayed Female

AGE

5 Years

WEIGHT

Not provided

INTERPRETED BY

Eric Lindquist, DMV
DABVP, Cert. IVUSS

**IMAGING
PERFORMED BY**

Kelly Vasquez

HOSPITAL NAME

Ringwood AH

REFERRING VET

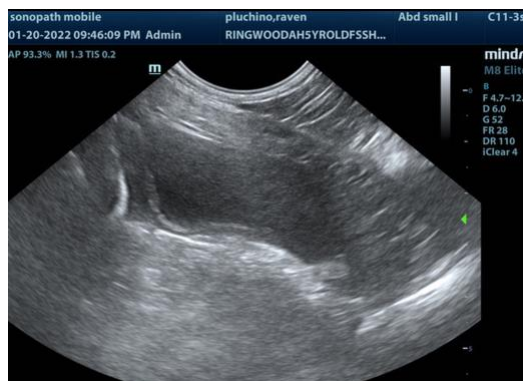Dr. Jamie DeSpirito

INVOICE

13546

DATE

1/21/22



The information and recommendations provided are based on the images presented by the referring veterinarian. No evaluation can be communicated regarding pathology that was not visible in the image/video clips provided.

Thank you for this referral. If the clinical or image interpretation does not parallel your findings or if I can be of any further assistance please contact me.

Eric Lindquist, DMV, DABVP, Cert. IVUSS, CEO of SonoPath.com
info@SonoPath.com