



PATIENT

Portia Barros

SPECIES

Canine

BREED

Pitbull Mix

SEX

Spayed Female

AGE

8 Years

WEIGHT

64.2 Lbs.

PRESENTING CLINICAL SIGNS

History: Minor mitral insufficiency Stage B1 - valvular disease 12/18/20, follow-up echo. No current meds reported.

ULTRASONOGRAPHIC EXAMINATION OF THE HEART

CANINE CARDIAC PARAMETERS	MR VMAX (m/s)	TR VMAX (m/s)	LA/AO (Boon method)	LA/AO (Heart Base; Swe)	FS (%)	EF (%)	EPSS (cm)
NORMAL PARAMETER	4.5-5.5	<2.7	1.3	<1.6	28-40	40-100	<0.6
PATIENT	--	--	1.3	1.2	29	57	0.54
CANINE CARDIAC PARAMETERS	HR (BPM)	AV VMAX (m/s)	PV MAX (m/s)	BODY WEIGHT (kg)	LA 2D short axis Base view (cm)	LVIDd Avg; 2D and m-mode short axis (cm)	LVIDs Avg; 2D and m-mode short axis (cm)
NORMAL PARAMETER	50-100	0.7-1.7	0.7-1.6	BELOW	BELOW	BELOW	BELOW
PATIENT	111	1.52	.91	--	4.1	3.94	--

INTERPRETED BY

Eric Lindquist, DMV DABVP, Cert. IVUSS

IMAGING PERFORMED BY

Kelly Vazquez

HOSPITAL NAME

Englewood AH

REFERRING VET

Dr. Ezik

INVOICE

13541

DATE

1/21/22

Cardiac Presentation

The mitral valve revealed trivial insufficiency, similar to the prior sonogram, not clinically significant. Chamber sizes were normal in this patient. Pericardial and extracardiac spaces were unremarkable. Septal and free wall thicknesses and all valvular apparatus were normal. Trivial mitral insufficiency was noted, not clinically significant.

ULTRASONOGRAPHIC FINDINGS

- Trivial mitral insufficiency, compensated

INTERPRETATION OF THE FINDINGS & FURTHER RECOMMENDATIONS

No progression from the prior sonogram. Recheck echo in 1-2 years or earlier if murmur grade increases.



PATIENT

Portia Barros

SPECIES

Canine

BREED

Pitbull Mix

SEX

Spayed Female

AGE

8 Years

WEIGHT

64.2 Lbs.

INTERPRETED BY

Eric Lindquist, DMV
DABVP, Cert. IVUSS

IMAGING PERFORMED BY

Kelly Vazquez

HOSPITAL NAME

Englewood AH

REFERRING VET

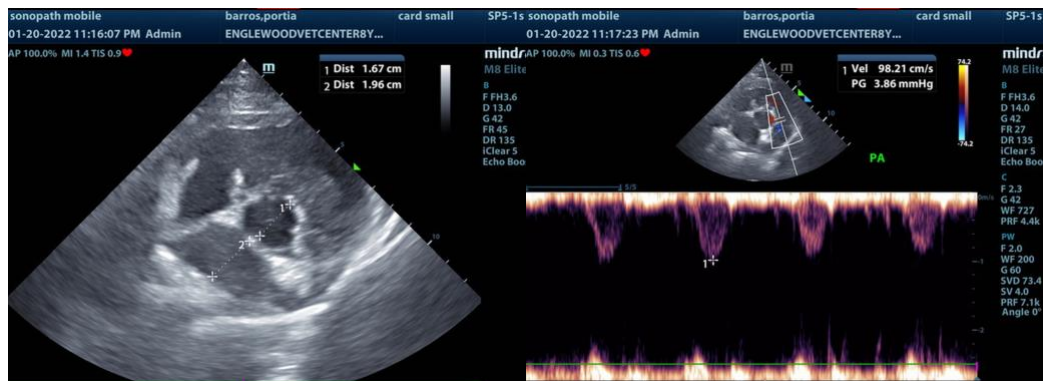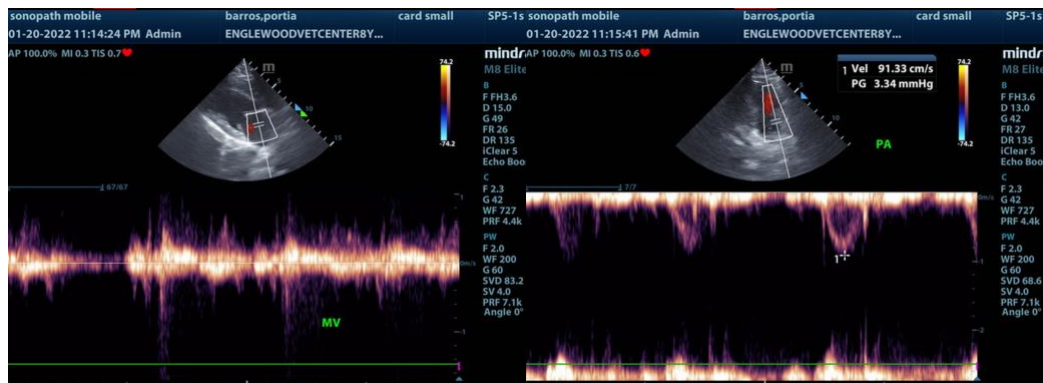
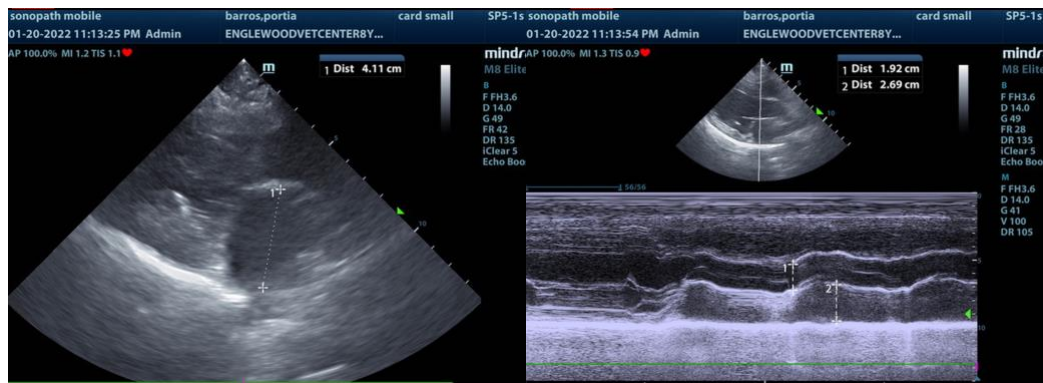
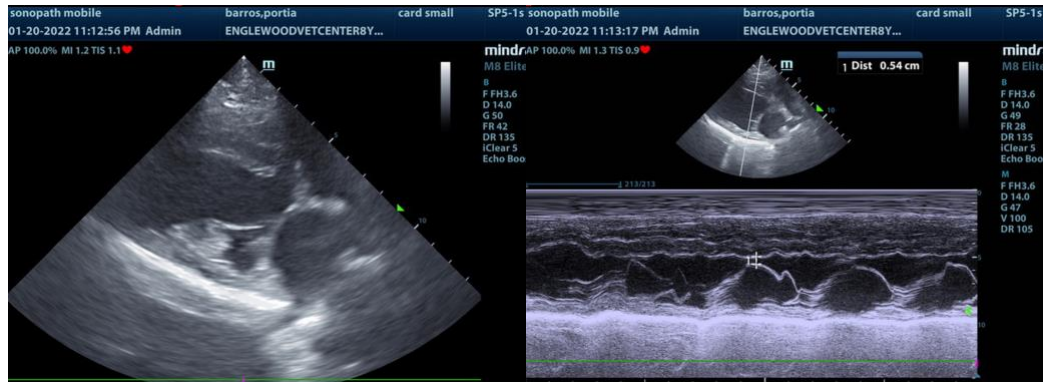
Dr. Ezik

INVOICE

13541

DATE

1/21/22





PATIENT

Portia Barros

SPECIES

Canine

BREED

Pitbull Mix

SEX

Spayed Female

AGE

8 Years

WEIGHT

64.2 Lbs.

INTERPRETED BY

Eric Lindquist, DMV
DABVP, Cert. IVUSS

IMAGING PERFORMED BY

Kelly Vazquez

HOSPITAL NAME

Englewood AH

REFERRING VET

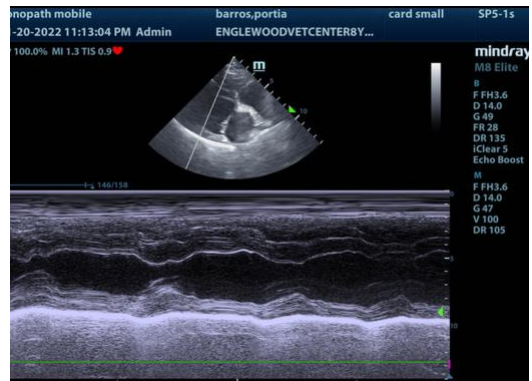
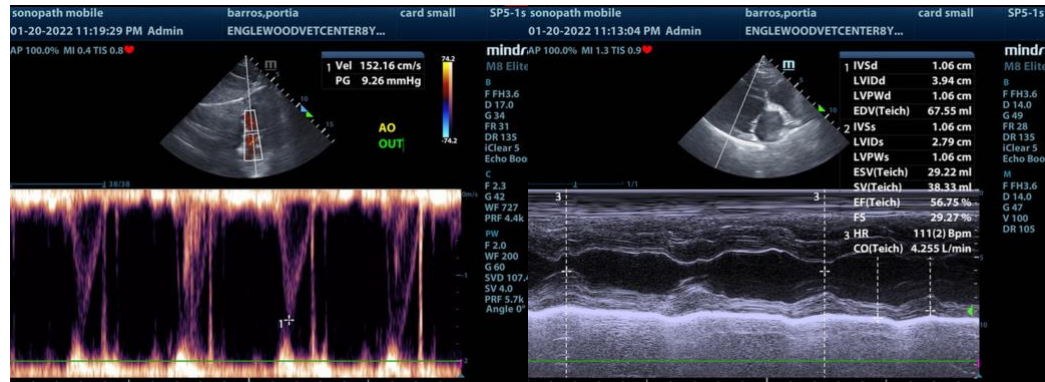
Dr. Ezik

INVOICE

13541

DATE

1/21/22



The information and recommendations provided are based on the images presented by the referring veterinarian. No evaluation can be communicated regarding pathology that was not visible in the image/video clips provided.

Thank you for this referral. If the clinical or image interpretation does not parallel your findings or if I can be of any further assistance please contact me.

Eric Lindquist, DMV, DABVP, Cert. IVUSS, CEO of SonoPath.com
info@SonoPath.com