



PATIENT

Monkey Bugarovich

SPECIES

Feline

BREED

DMH

SEX

Neutered Male

AGE

18 Years

WEIGHT

8 Lbs.

INTERPRETED BY

Eric Lindquist, DMV
DABVP, Cert. IVUSS

IMAGING PERFORMED BY

Jenna Walsh, CVT

HOSPITAL NAME

VCA Westmoreland AH

REFERRING VET

Dr. Bugarovich

INVOICE

13556

DATE

1/21/22

PRESENTING CLINICAL SIGNS

History: senior scanning echo weightloss Current Medications pred, methimazole, pancreazyme

ULTRASONOGRAPHIC EXAMINATION OF THE HEART

| FELINE CARDIAC PARAMETERS | BODY WEIGHT (kg) | HR (BPM) | IVSd (cm) | LVIDd (cm) | LVWd (cm) | FS (%) | EF (%) |
|---------------------------|------------------|---------------------------|--|-----------------|-----------------|-----------|--------|
| NORMAL PARAMETER | ----- | 150-240 | 0.3-0.6 | 1.0-2.1 | 0.25-0.6 | 35-67 | 80-100 |
| PATIENT | -- | 146 | 0.71 | 1.72 | 0.7 | 51 | 85 |
| FELINE CARDIAC PARAMETERS | LA/AO (Boon) | LA/AO HEART BASE (Sisson) | LA 2D 4-chamber long axis AS to FW (Sisson) (cm) | LVOT VEL. (m/s) | RVOT VEL. (m/s) | IVRT (m/) | |
| NORMAL PARAMETER | <1.5 | 0.88-1.79 | 0.7-1.7 | <1.6 | <1.3 | 40-60 | |
| PATIENT | 1.1 | 1.37 | -- | 1.34 | .90 | NM | |

Adapted from June Boon, Veterinary Echocardiography, 1998
Sisson D et al. JVIM 1991; 5: 232, Jacobs et al. Am J Vet Res 1985; 46:1705

Cardiac Presentation

The echocardiogram in this patient demonstrated normal **left atrial** size based on 3 separate LA measurements. Trivial mitral insufficiency noted at 3.51 m/s, not clinically significant. The **left ventricle** presented normal thicknesses with linear contour and was not dilated nor restricted. **Myocardial** remodeling noted yet not a clinical issue. **Contractility** of the ventricular walls was adequate and in normal range for this patient evidenced by the fractional shortening measurement and subjective evaluation of the different regions and angles of the myocardium. Slight left ventricular hypertrophy noted in this patient with myocardial remodeling- not clinically significant. The **right atrium** and auricle revealed normal size, structure and content. No evidence of masses was noted or chamber overload. Minor **tricuspid** insufficiency noted at 1.76 m/s, not clinically significant. The **right ventricle** was of normal size (1/3 diameter of LV), chordae structure, myocardial echogenicity and thickness. **Pulmonic** tract assessment revealed normal valve structure, laminar flow, and diameter (approx. 1:1 pa/ao ratio). No visible **pericardial** or free pleura fluid was noted or extra cardiac pathology in the visible planes. The cranial **mediastinum and pericardial regions** were free of masses in the visible window.

ULTRASONOGRAPHIC FINDINGS

- Slight left ventricular hypertrophy, not clinically significant
- Mitral and tricuspid insufficiency, not clinically significant
- Largely geriatric heart with normal function, volumes and minor remodeling

INTERPRETATION OF THE FINDINGS & FURTHER RECOMMENDATIONS

No cardiac medications recommended. Abdominal sonogram recommended given the patient



PATIENT

Monkey Bugarovich

SPECIES

Feline

BREED

DMH

SEX

Neutered Male

AGE

18 Years

WEIGHT

8 Lbs.

INTERPRETED BY

Eric Lindquist, DMV
DABVP, Cert. IVUSS

IMAGING PERFORMED BY

Jenna Walsh, CVT

HOSPITAL NAME

VCA Westmoreland AH

REFERRING VET

Dr. Bugarovich

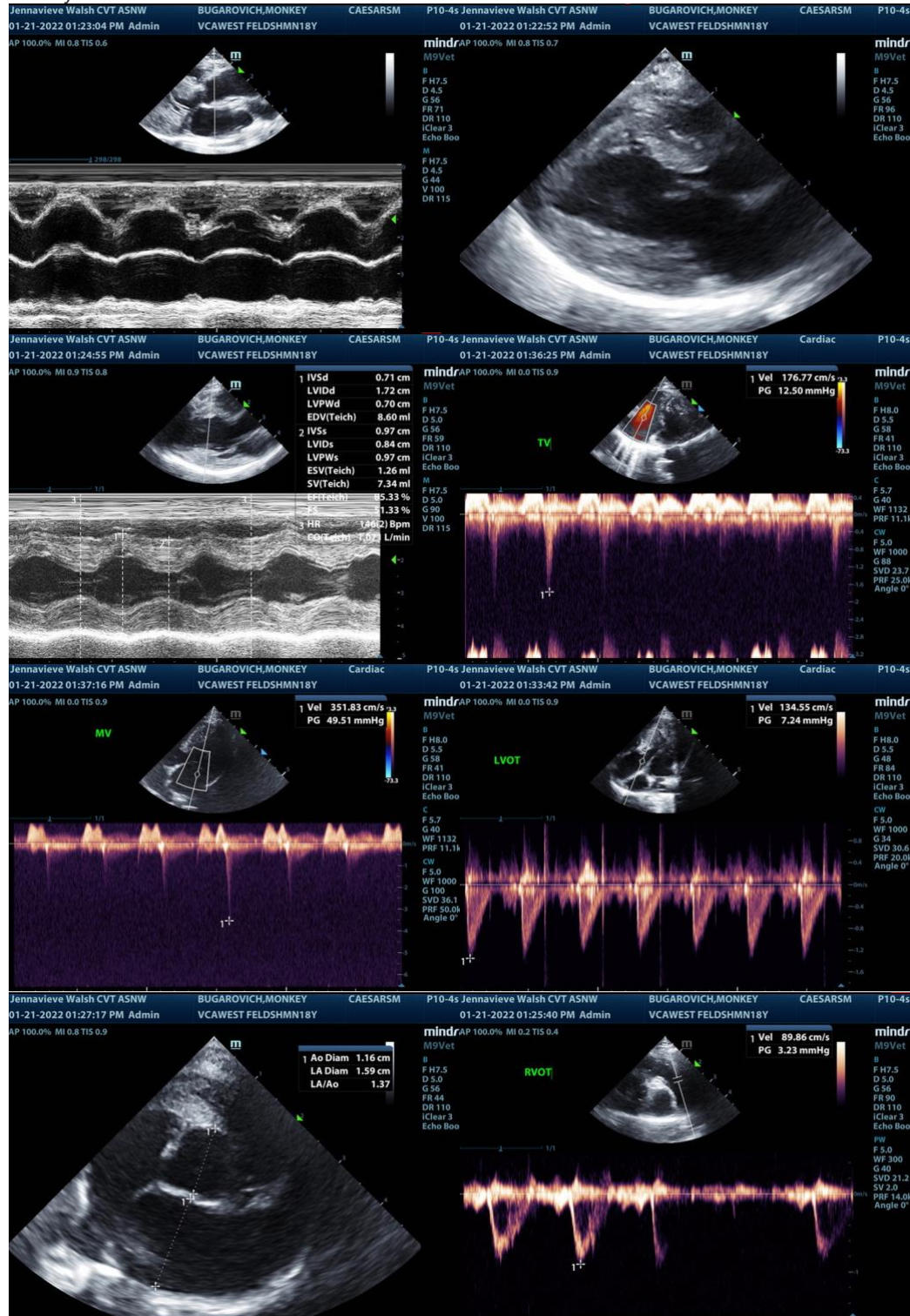
INVOICE

13556

DATE

1/21/22

history.



The information and recommendations provided are based on the images presented by the referring veterinarian. No evaluation can be communicated regarding pathology that was not visible in the image/video clips provided.



PATIENT

Monkey Bugarovich

Thank you for this referral. If the clinical or image interpretation does not parallel your findings or if I can be of any further assistance please contact me.

SPECIES

Feline

Eric Lindquist, DMV, DABVP, Cert. IVUSS, CEO of SonoPath.com
info@SonoPath.com

BREED

DMH

SEX

Neutered Male

AGE

18 Years

WEIGHT

8 Lbs.

INTERPRETED BY

Eric Lindquist, DMV
DABVP, Cert. IVUSS

**IMAGING
PERFORMED BY**

Jenna Walsh, CVT

HOSPITAL NAME

VCA Westmoreland AH

REFERRING VET

Dr. Bugarovich

INVOICE

13556

DATE

1/21/22