# SonoPath
*Clinical Sonography & Telecytology*

EDUCATIONAL TELECONSULTATION SERVICES™

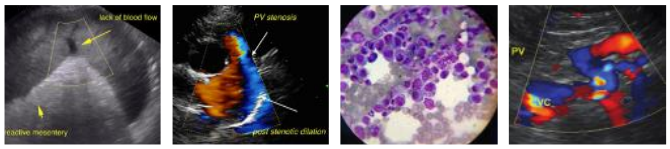

SonoPath.com
1-800-838-4268 info@sonopath.com

**PATIENT**

Jack Gabel

**SPECIES**

Canine

**BREED**

Cocker Spaniel Mix

**SEX**

Neutered Male

**AGE**

8 Years

**WEIGHT**

29.2 Lbs.

**INTERPRETED BY**

Eric Lindquist, DMV DABVP, Cert. IVUSS

**IMAGING PERFORMED BY**

Diane McFadden

**HOSPITAL NAME**

Advanced VC

**REFERRING VET**

Dr. Anderson

**INVOICE**

13538

**DATE**

1/21/22

## PRESENTING CLINICAL SIGNS

History: 3/6 systolic murmur; assess for anesthetic for dental procedure. On carprofen and doxycycline, and clavamox

Abnormal PE/Chem/CBC/UA Results: n/a

## ULTRASONOGRAPHIC EXAMINATION OF THE HEART

| CANINE CARDIAC PARAMETERS | MR VMAX (m/s) | TR VMAX (m/s) | LA/AO (Boon method) | LA/AO (Heart Base; Swe) | FS (%) | EF (%) | EPSS (cm) |
|---|---|---|---|---|---|---|---|
| NORMAL PARAMETER | 4.5-5.5 | <2.7 | 1.3 | <1.6 | 28-40 | 40-100 | <0.6 |
| PATIENT | 5.72 | -- | 1.3 | 1.38 | 29 | 57 | 0.1 |
| **CANINE CARDIAC PARAMETERS** | **HR** (BPM) | **AV VMAX** (m/s) | **PV MAX** (m/s) | **BODY WEIGHT** (kg) | **LA** 2D short axis Base view (cm) | **LVIDd** Avg; 2D and m-mode short axis (cm) | **LVIDs** Avg; 2D and m-mode short axis (cm) |
| NORMAL PARAMETER | 50-100 | 0.7-1.7 | 0.7-1.6 | BELOW | BELOW | BELOW | BELOW |
| PATIENT | 133 | 1.47 | 1.00 | -- | 3.4 | 3.52 | -- |

### *Cardiac Presentation*

The echocardiogram in this patient demonstrated normal **left atrial** size based on 3 different LA measurement methods. Chamber volumes and echogenicity were normal. The cranial and caudal **mitral** valve leaflets presented vegetative thickening consistent with endocardiosis. Doppler indicated measurable insufficiency. The **left ventricle** presented thicknesses with linear contour and was not dilated nor restricted. The **myocardium** presented normal echogenicity without subjective evidence of significant fibrotic or ischemic disease. **Contractility** of the ventricular walls was adequate and in normal range for this patient evidenced by the fractional shortening measurement and subjective evaluation of the different regions of the myocardium. The **left ventricular outflow** tract demonstrated normal laminar flow and subjective structural integrity. The **right atrium** and auricle revealed normal size, structure and content. No evidence of masses was noted or chamber overload. **Tricuspid** valvular assessment demonstrated adequate linear morphology. The **right ventricle** was of normal size (1/3 diameter of LV), chordae structure, myocardial echogenicity and thickness. **Pulmonic** tract assessment revealed normal valve structure, laminar flow, and diameter (approx.1:1 pa/ao ratio). No visible **pericardial** or free pleura fluid was noted. No echographically detectable evidence of infiltrative disease was visible. The cranial **mediastinum and pericardial regions** were free of masses in the visible window.

## ULTRASONOGRAPHIC FINDINGS

- Stage B-1 valvular disease, compensated at this time

SonoPath
Clinical Sonography & Telecytology
EDUCATIONAL TELECONSULTATION SERVICES™

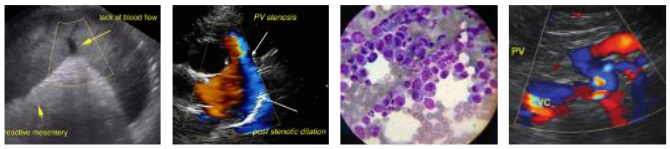


SonoPath.com
1-800-838-4268 info@sonopath.com

**PATIENT**

Jack Gabel

**SPECIES**

Canine

**BREED**

Cocker Spaniel Mix

**SEX**

Neutered Male

**AGE**

8 Years

**WEIGHT**

29.2 Lbs.

**INTERPRETED BY**

Eric Lindquist, DMV
DABVP, Cert. IVUSS

**IMAGING PERFORMED BY**

Diane McFadden

**HOSPITAL NAME**

Advanced VC

**REFERRING VET**

Dr. Anderson

**INVOICE**

13538

**DATE**

1/21/22

## INTERPRETATION OF THE FINDINGS & FURTHER RECOMMENDATIONS

The heart is stable without clinical disease. No overt contraindication for anesthesia of brief to moderate duration. I suggest Torbutrol premed, Propofol induction, Isoflo maintenance or similar protocol if anesthesia is desired. Blood pressure recommended if not already performed and target white coat negative systolic pressure of < 160 mmHg. If higher than this ACE-inhibitor is suggested to reach this level. Recheck echocardiogram is recommended in 6 months, earlier if murmur grade increases or clinical signs initiate.

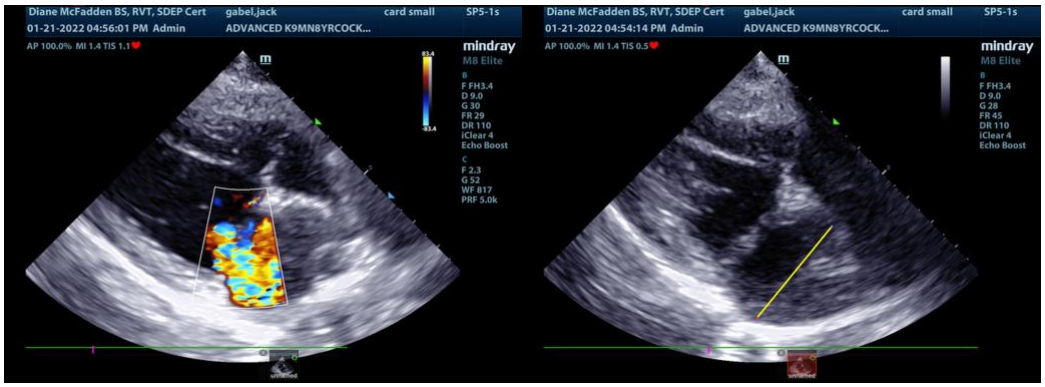

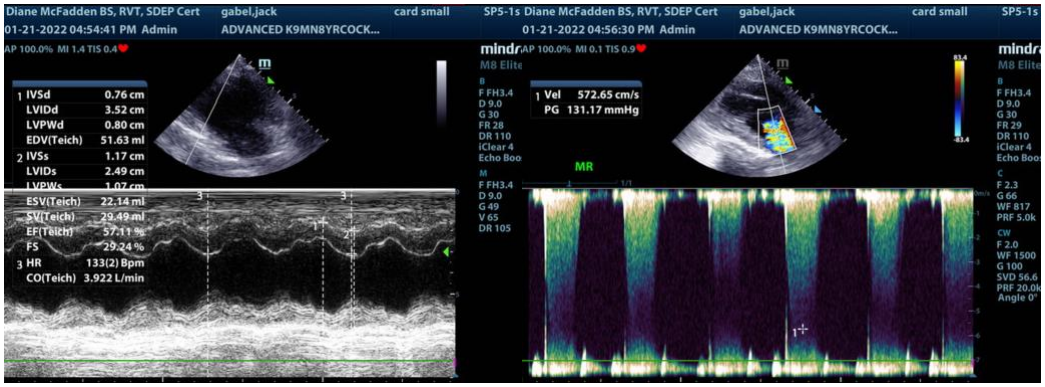

# SonoPath

*Clinical Sonography & Telecytology*

EDUCATIONAL TELECONSULTATION SERVICES™

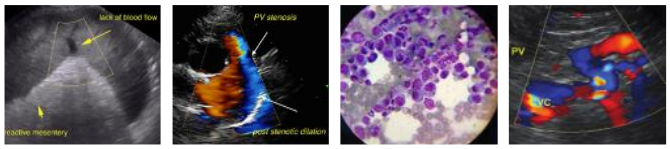

SonoPath.com

1-800-838-4268 info@sonopath.com

**PATIENT**

Jack Gabel

**SPECIES**

Canine

**BREED**

Cocker Spaniel Mix

**SEX**

Neutered Male

**AGE**

8 Years

**WEIGHT**

29.2 Lbs.

**INTERPRETED BY**

Eric Lindquist, DMV DABVP, Cert. IVUSS

**IMAGING PERFORMED BY**

Diane McFadden

**HOSPITAL NAME**

Advanced VC

**REFERRING VET**

Dr. Anderson

**INVOICE**

13538

**DATE**

1/21/22

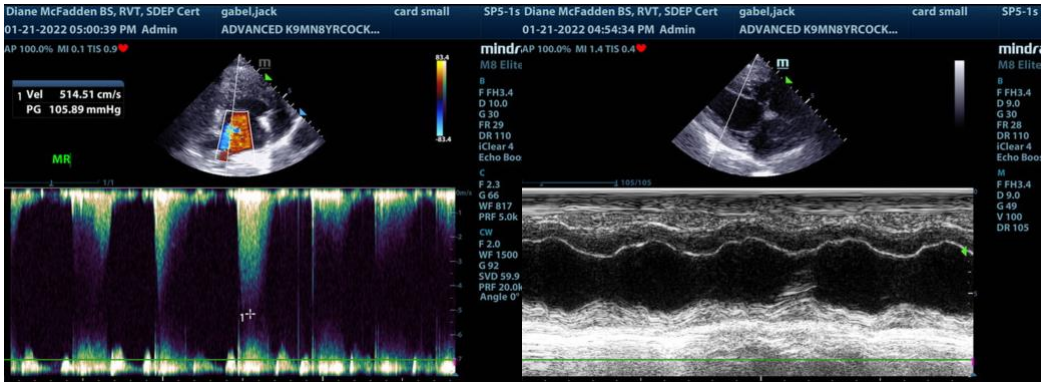


**The information and recommendations provided are based on the images presented by the referring veterinarian. No evaluation can be communicated regarding pathology that was not visible in the image/video clips provided.**

Thank you for this referral. If the clinical or image interpretation does not parallel your findings or if I can be of any further assistance please contact me.

**Eric Lindquist**, DMV, DABVP, Cert. IVUSS, CEO of SonoPath.com
info@SonoPath.com