

IMAGING PERFORMED BY

IntraPet.com



 **SonoPath**

Clinical Sonography & Telecytology

EDUCATIONAL TELECONSULTATION SERVICES™

1-800-838-4268  info@sonopath.com  SonoPath.com

**DATE PRESENTING CLINICAL SIGNS**

1/21/22 History: drinking more/ decreased appetite. Pancreatitis 1/11/22

**PATIENT** Current Medications: Convenia injection 1/12/22.

Blackie Bridgeman

Lab Results: precision PSL 137 (8-26).

Date of Previous IntraPet Ultrasound: No previous IntraPet scans.

Sedation: Not required to complete full diagnostic ultrasound.

Stat Report: Not requested.

**SPECIES**

Feline

**ULTRASONOGRAPHIC EXAMINATION OF THE ABDOMEN**

**BREED**

DSH

**Urinary System**

The **urinary bladder**, trigone, and pelvic urethra presented normal thicknesses and normal tone. The ureters were not visible which is normal. No uroliths or sediment were visualized and anechoic urine was present. No evidence of inflammatory or neoplastic changes were noted. Ureteral papillae were normal.

**SEX**

Neutered Male

The **kidneys** presented a relatively uniform cortical hyperechogenicity when compared to the renal medulla, spleen and liver. No overt masses were noted. Corticomedullary definition was nebulous and the ratio favored the cortex slightly. The ureters were not visible and assumed to be normal. These changes are most consistent with chronic interstitial nephritis yet infiltrative disease could not be entirely ruled out without biopsy though neoplasia is not suspected. The left kidney measured 3.8 cm with pyelectasia of 0.43 cm. The right kidney measured 4.29 cm. Minor mineralization noted in both kidneys. Blood flow to the kidneys appeared to be mildly subnormal. Medullary rim sign noted on both kidneys as well.

**AGE**

2007

**WEIGHT**

10.6 Pounds

**Adrenal Glands**

**INTERPRETED BY**

Eric Lindquist, DMV  
DABVP, Cert. IVUSS

Both **adrenal glands** were visualized and recognized as having normal shape, size, position and echogenicity for this breed. The phrenic vasculature, glandular echogenicity and detail were unremarkable. Capsule, cortex, and medullary definition were normal for this age patient. The right adrenal gland measured 0.42 cm.

**IMAGING PERFORMED BY**

Rachel Brilhart RDMS

**Spleen**

The **spleen** presented a smooth homogeneous parenchyma hyperechoic to liver and renal cortical parenchyma. The capsule was smooth without noticeable expansion or deviation from within the spleen or adjacent pathology. The splenic vasculature demonstrated normal volume without signs of congestion or thrombosis. No sonographic evidence of acute or chronic inflammatory, neoplastic, or infarctual changes were noted.

**HOSPITAL NAME**

Honeygo AH

**Liver**

**REFERRING VET**

Dr. Wright

The **liver** images from right and left intercostal as well as subcostal views revealed subjectively normal liver size, contour, and structure. Some age-related parenchymal remodeling was noted but likely not clinically significant at this time. Vascular and biliary tracts were of normal volume and no evidence of congestion was noted. Minor gallbladder debris noted.

**INVOICE**

35036

**Gastrointestinal**

The **gastrointestinal tract** revealed minor variable thickening and echogenic submucosal changes most consistent with low grade end result of chronic GI disease such as IBD and may be related to malassimilation of nutrients if any weight loss is present. No obvious neoplastic patterns were noted and luminal content as unremarkable. Small intestine measured up to 0.26 cm.

## Pancreas

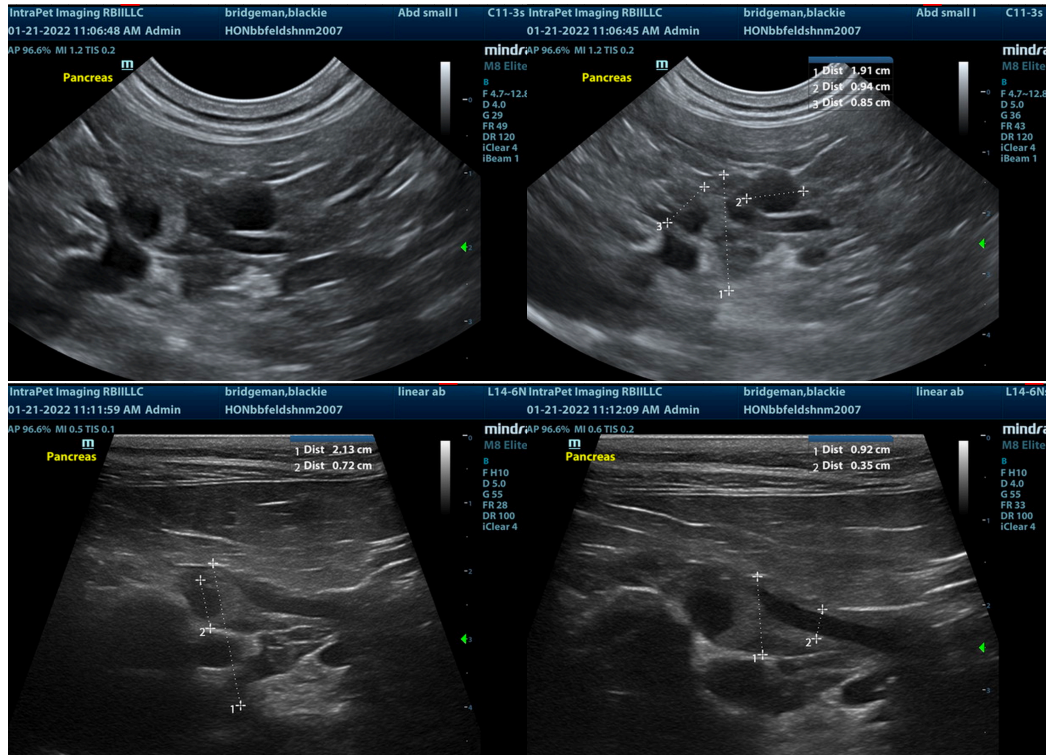
The **pancreas** presented coarse architecture and dilated duct at 0.35 cm. Irregular contour and remodeling noted with nodular changes. Subxiphoid palpation is recommended to assess for pain or discomfort associated with the pancreas. Prior history of pancreatitis likely. Cystic and nodular changes noted.

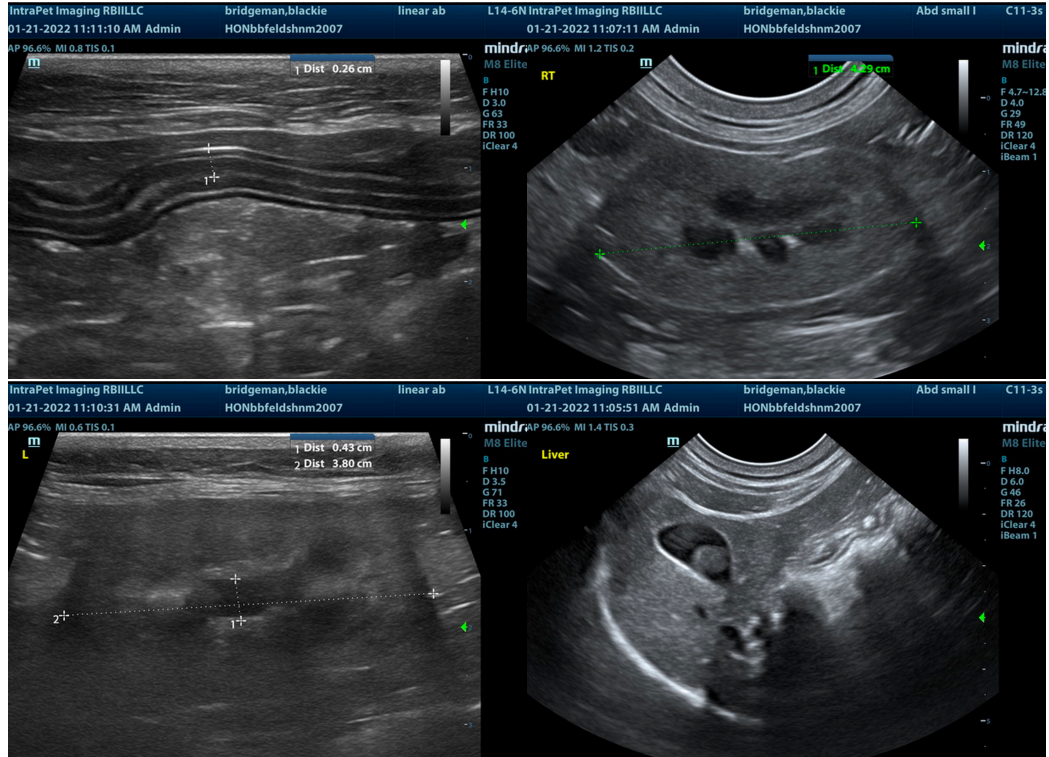
### ULTRASONOGRAPHIC FINDINGS

- Cystic and nodular pancreas
- Chronic interstitial nephrosis renal pattern with minor mineralization
- Age related hepatic changes

### INTERPRETATION OF THE FINDINGS & FURTHER RECOMMENDATIONS

Minor potential for pancreatic neoplasia. However, FNA of the nodules and drainage of the cysts could be considered for further definition. Culture and cytology would be appropriate. The kidneys appear near end stage. Some pancreatic inflammation noted. FNA of the pancreatic changes would allow for assessment of predominant inflammatory cell type as well as to rule out any neoplasia and allow for culture of any cystic content.





The information and recommendations provided are based on the images presented by the referring veterinarian. No evaluation can be communicated regarding pathology that was not visible in the image/video clips provided.

Thank you for this referral. If the clinical or image interpretation does not parallel your findings or if I can be of any further assistance please contact me.

**Eric Lindquist**, DMV, DABVP, Cert. IVUSS, CEO of SonoPath.com  
[info@SonoPath.com](mailto:info@SonoPath.com)