



PATIENT PRESENTING CLINICAL SIGNS

Baxter Bug Shipley
Left apical systolic grade I murmur - r/o mitral valve dysplasia vs other cardiomyopathy vs transient/asymptomatic vs secondary to metabolic dysfunction vs other. HWT negative Current Medications Rimadyl, Dasuquin, Nexgard/Heartgard

SPECIES

Canine

ULTRASONOGRAPHIC EXAMINATION OF THE HEART

BREED

Chiweenie

SEX

Neutered Male

AGE

9 Years

WEIGHT

15.1 Pounds

INTERPRETED BY

Eric Lindquist, DMV

DABVP, Cert. IVUSS

IMAGING PERFORMED BY

Jenna Walsh, CVT

HOSPITAL NAME

The Veterinary Hospital

REFERRING VET

Dr. Berman

INVOICE

35022

DATE

1/21/22

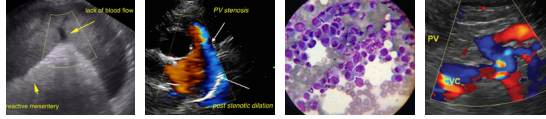
CANINE CARDIAC PARAMETERS	MR VMAX (m/s)	TR VMAX (m/s)	LA/AO (Boon method)	LA/AO (Heart Base; Swe)	FS (%)	EF (%)	EPSS (cm)
NORMAL PARAMETER	4.5-5.5	<2.7	1.3	<1.6	28-40	40-100	<0.6
PATIENT	5.83	2.47	1.4	1.3	30	59	0.6
CANINE CARDIAC PARAMETERS	HR (BPM)	AV VMAX (m/s)	PV MAX (m/s)	BODY WEIGHT (kg)	LA 2D short axis Base view (cm)	LVIDd Avg; 2D and m-mode short axis (cm)	LVIDs Avg; 2D and m-mode short axis (cm)
NORMAL PARAMETER	50-100	0.7-1.7	0.7-1.6				
PATIENT	159	1.1	0.9		2.86	3.27	

Cardiac Presentation

The echocardiogram in this patient demonstrated normal **left atrial** size based on 3 different LA measurement methods. Chamber volumes and echogenicity were normal. The cranial and caudal **mitral** valve leaflets presented vegetative thickening consistent with endocardiosis. Doppler indicated measurable insufficiency. The **left ventricle** presented thicknesses with linear contour and was not dilated nor restricted. The **myocardium** presented normal echogenicity without subjective evidence of significant fibrotic or ischemic disease. **Contractility** of the ventricular walls was adequate and in normal range for this patient evidenced by the fractional shortening measurement and subjective evaluation of the different regions of the myocardium. The **left ventricular outflow** tract demonstrated normal laminar flow and subjective structural integrity. The **right atrium** and auricle revealed normal size, structure and content. No evidence of masses was noted or chamber overload. Minor **tricuspid** insufficiency noted. The **right ventricle** was of normal size (1/3 diameter of LV), chordae structure, myocardial echogenicity and thickness. **Pulmonic** tract assessment revealed normal valve structure, laminar flow, and diameter (approx. 1:1 pa/ao ratio). No visible **pericardial** or free pleura fluid was noted. No echographically detectable evidence of infiltrative disease was visible. The cranial **mediastinum** and **pericardial** regions were free of masses in the visible window.

ULTRASONOGRAPHIC FINDINGS

- Stage B1 valvular disease



PATIENT

Baxter Bug Shipley

SPECIES

Canine

BREED

Chiweenie

SEX

Neutered Male

AGE

9 Years

WEIGHT

15.1 Pounds

INTERPRETED BY

Eric Lindquist, DMV
 DABVP, Cert. IVUSS

IMAGING PERFORMED BY

Jenna Walsh, CVT

HOSPITAL NAME

The Veterinary Hospital

REFERRING VET

Dr. Berman

INVOICE

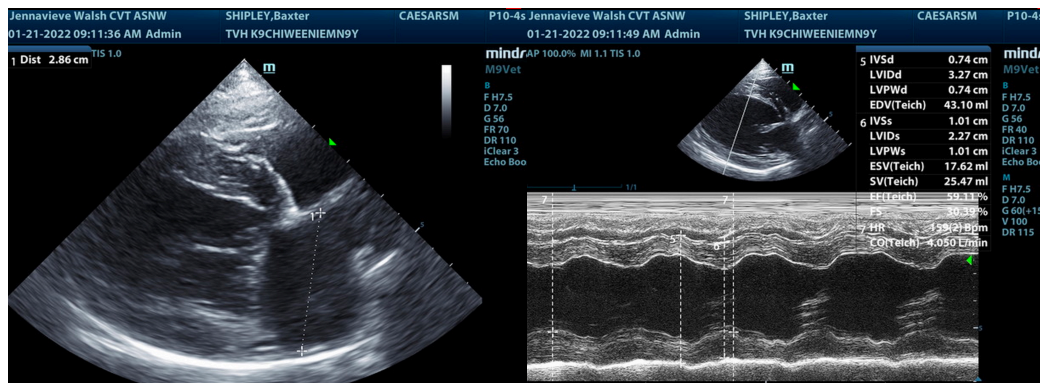
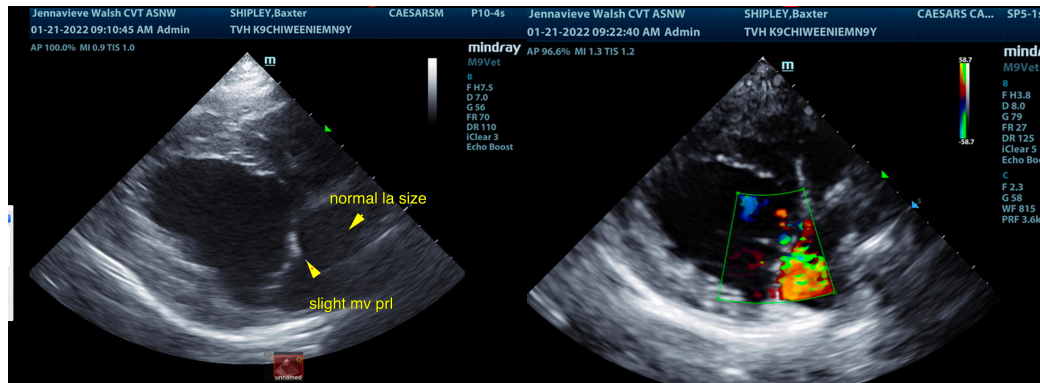
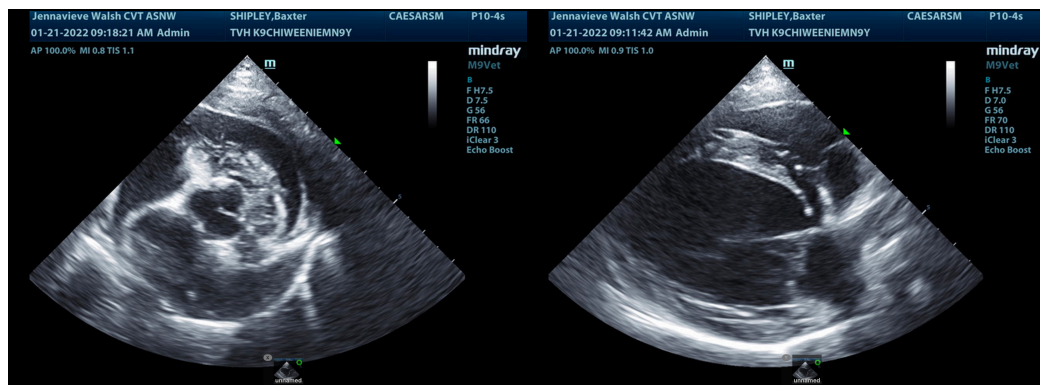
35022

DATE

1/21/22

INTERPRETATION OF THE FINDINGS & FURTHER RECOMMENDATIONS

B1: The heart is stable without clinical disease. No overt contraindication for anesthesia of brief to moderate duration. I suggest Torbutrol premed, Propofol induction, Isoflo maintenance or similar protocol if anesthesia is desired. Blood pressure recommended if not already performed and target white coat negative systolic pressure of < 160 mmHg. If higher than this ACE-inhibitor is suggested to reach this level. Recheck echocardiogram is recommended in 6 months, earlier if murmur grade increases or clinical signs initiate.





PATIENT

Baxter Bug Shipley

SPECIES

Canine

BREED

Chiweenie

SEX

Neutered Male

AGE

9 Years

WEIGHT

15.1 Pounds

INTERPRETED BY

Eric Lindquist, DMV
DABVP, Cert. IVUSS

IMAGING PERFORMED BY

Jenna Walsh, CVT

HOSPITAL NAME

The Veterinary
Hospital

REFERRING VET

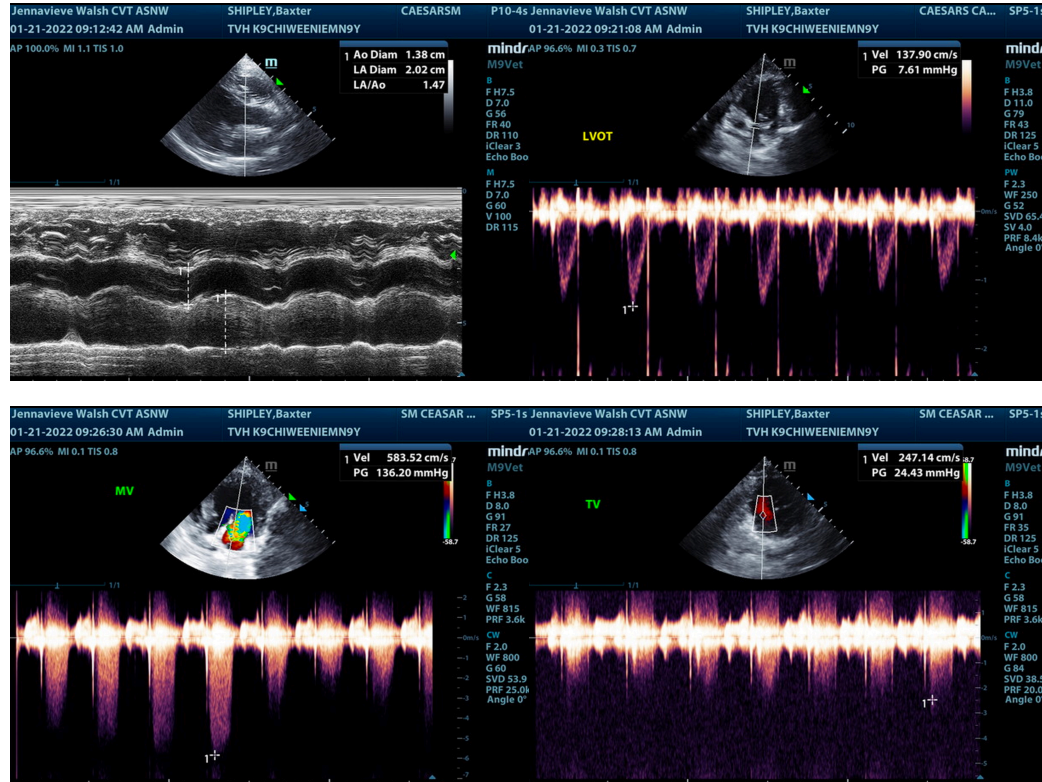
Dr. Berman

INVOICE

35022

DATE

1/21/22



The information and recommendations provided are based on the images presented by the referring veterinarian/sonographer. No evaluation can be communicated regarding pathology that was not visible in the image/video clips provided.

Thank you for this referral. If the clinical or image interpretation does not parallel your findings or if I can be of any further assistance please contact me.

Eric Lindquist, DMV, DABVP, Cert. IVUSS, CEO of SonoPath.com

info@SonoPath.com