



PATIENT

Lucy Marschall

SPECIES

Canine

BREED

Shepherd Mix

SEX

Female

AGE

10 years

WEIGHT

54 lbs

INTERPRETED BY

Eric Lindquist, DMV
DABVP, Cert. IVUSS

IMAGING PERFORMED BY

Heather

HOSPITAL NAME

Animal Care Center of
Flanders

REFERRING VET

Dr. Hargadon

INVOICE

70350

DATE

1/20/26

PRESENTING CLINICAL SIGNS

- Recheck echo, history mitral and tricuspid insufficiency, well controlled on meds
- BP - 70
- Enalapril 10mg - 1 & 1/2 tab BID, spironolactone 25mg BID, vetmedin - 7.5mg BID - lasix 50mg 1 and 1/2 bid (only gave Vetmedin and trazadone today)

ULTRASONOGRAPHIC EXAMINATION OF THE HEART

The echocardiogram in this patient presented persistent, moderate to severe volume overload of the left atrium with arrhythmogenic activity. Prolapse of the anterior mitral valve leaflet was noted. Volume overload was noted in the left ventricle with inadequate contractility. This is consistent with myocardial insufficiency. Tricuspid insufficiency was noted with right atrial enlargement. Hepatic vein dilation was noted. Pulmonary edema lines were noted.

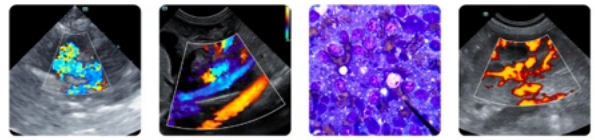
CANINE CARDIAC PARAMETERS	MR VMAX (m/s)	TR VMAX (m/s)	LA/AO	LA/AO (Heart Base)	FS (%)	EF (%)	EPSS (cm)
NORMAL PARAMETER	4.5-5.5	<2.7	1.3	<1.6	28-40	40-100	<0.6
PATIENT	6.0	None	1.7	3.0	35	NM	0.1
CANINE CARDIAC PARAMETERS	HR (BPM)	AV VMAX (m/s)	PV MAX (m/s)	BODY WEIGHT	LA 2D short axis Base view (cm)	LVIDd Avg; 2D and m-mode short axis (cm)	LVIDs Avg; 2D and m-mode short axis (cm)
NORMAL PARAMETER	50-100	0.7-1.7	0.7-1.6	BELOW	BELOW	BELOW	BELOW
PATIENT	Variable 90	None	None	54 lbs	7.3	4.9	

ULTRASONOGRAPHIC FINDINGS

Persistent, mitral and tricuspid insufficiency with moderate volume overload and arrhythmogenic activity.

INTERPRETATION OF THE FINDINGS & FURTHER RECOMMENDATIONS

I recommend increasing Lasix by 1 mg/kg b.i.d. Pimobendan can be increased to t.i.d. dosing if tolerated. Blood pressure measurements are warranted. EKG or Holter monitor are indicated. Recheck echocardiogram is recommended in 3-6 months or earlier if clinical signs are persisting. Prognosis is extremely guarded. BUN, creatinine, urine specific gravity and blood pressure measurements as well as basal respiratory rate should all be monitored.



PATIENT

Lucy Marschall

SPECIES

Canine

BREED

Shepherd Mix

SEX

Female

AGE

10 years

WEIGHT

54 lbs

INTERPRETED BY

Eric Lindquist, DMV
DABVP, Cert. IVUSS

IMAGING PERFORMED BY

Heather

HOSPITAL NAME

Animal Care Center of
Flanders

REFERRING VET

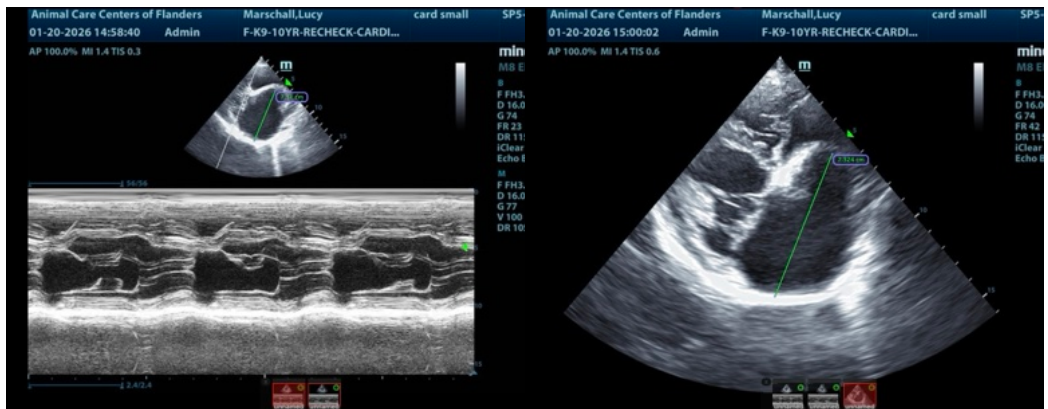
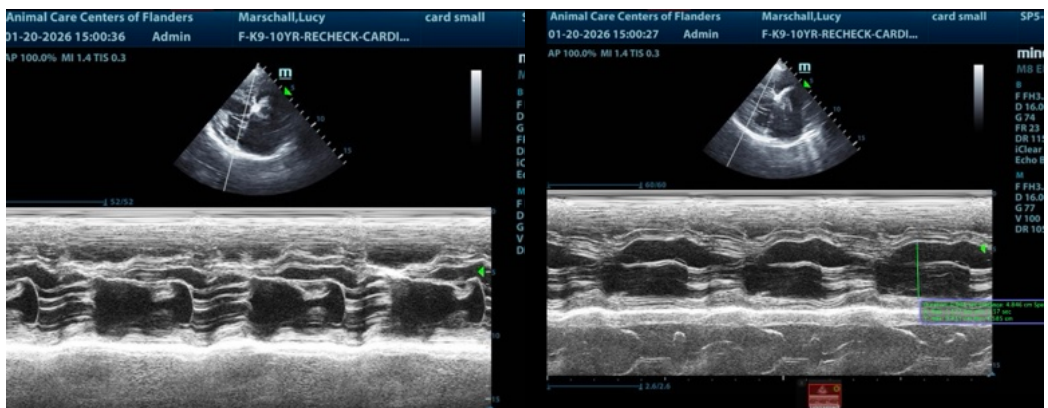
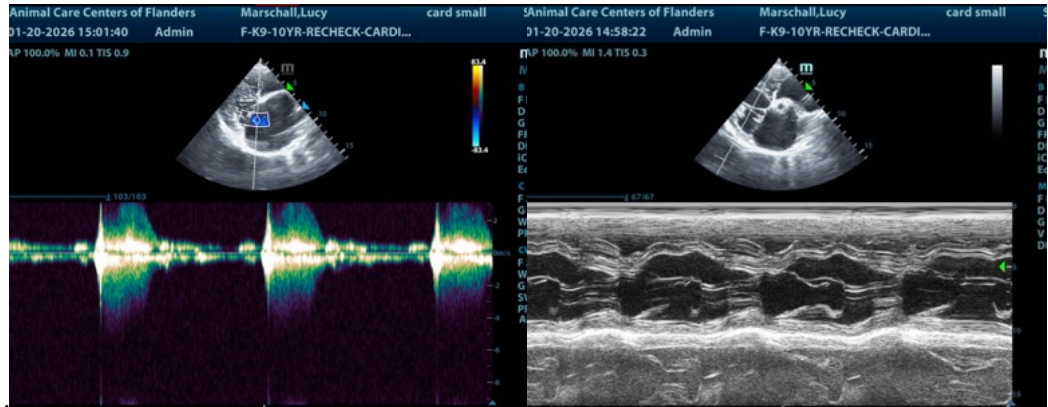
Dr. Hargadon

INVOICE

70350

DATE

1/20/26





PATIENT

Lucy Marschall

SPECIES

Canine

BREED

Shepherd Mix

SEX

Female

AGE

10 years

WEIGHT

54 lbs

INTERPRETED BY

Eric Lindquist, DMV
DABVP, Cert. IVUSS

IMAGING PERFORMED BY

Heather

HOSPITAL NAME

Animal Care Center of
Flanders

REFERRING VET

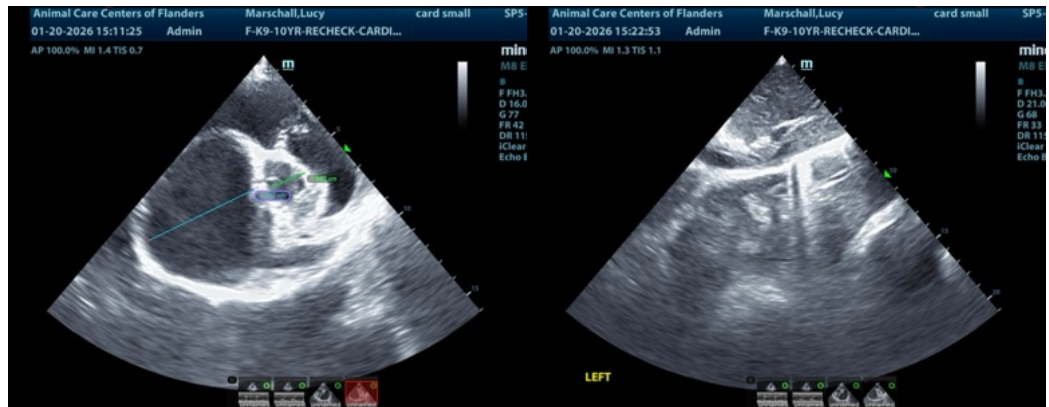
Dr. Hargadon

INVOICE

70350

DATE

1/20/26



The information and recommendations provided are based on the images presented by the referring veterinarian/sonographer. No evaluation can be communicated regarding pathology that was not visible in the image/video clips provided.

Thank you for this referral. If the clinical or image interpretation does not parallel your findings or if I can be of any further assistance please contact me.

Eric Lindquist, DMV, DABVP (CFM), Cert. IVUSS, CEO of SonoPath.com

info@SonoPath.com