



PATIENT

Roxy Torres

SPECIES

Canine

BREED

Cavalier King Charles

SEX

Spayed Female

AGE

9 Years

WEIGHT

26.9 Pounds

INTERPRETED BY

Eric Lindquist, DMV
DABVP, Cert. IVUSS

IMAGING PERFORMED BY

Kely Vazquez

HOSPITAL NAME

Sova AH

REFERRING VET

Dr. Ammeraal

INVOICE

20664

DATE

1/20/23

PRESENTING CLINICAL SIGNS

History: Patient presents for a grade 3/6 systolic murmur. Current meds: Novox 25 mgs BID, Movoflex Advanced.

Abnormal PE/Chem/CBC/UA Results: Alk. Phos. 139.

ULTRASONOGRAPHIC EXAMINATION OF THE HEART

CANINE CARDIAC PARAMETERS	MR VMAX (m/s)	TR VMAX (m/s)	LA/AO (Boon method)	LA/AO (Heart Base; Swe)	FS (%)	EF (%)	EPSS (cm)
NORMAL PARAMETER	4.5-5.5	<2.7	1.3	<1.3	28-40	40-100	<0.6
PATIENT	5.50	3.1	1.1	1.3	32	61	0.1
CANINE CARDIAC PARAMETERS	HR (BPM)	AV VMAX (m/s)	PV MAX (m/s)	BODY WEIGHT (kg)	LA 2D short axis Base view (cm)	LVIDd Avg; 2D and m-mode short axis (cm)	LVIDs Avg; 2D and m-mode short axis (cm)
NORMAL PARAMETER	50-100	0.7-1.7	0.7-1.6				
PATIENT	82	1.60	.76	--	3.13	3.04	--

Cardiac Presentation

The echocardiogram in this patient demonstrated normal **left atrial** size based on 3 different LA measurement methods. Complete filling of the left atrium was noted on color flow assessment of the mitral valve. Doppler indicated measurable insufficiency. The **left ventricle** presented thicknesses with linear contour and was not dilated nor restricted. The **myocardium** presented normal echogenicity without subjective evidence of significant fibrotic or ischemic disease. **Contractility** of the ventricular walls was adequate and in normal range for this patient evidenced by the fractional shortening measurement and subjective evaluation of the different regions of the myocardium. The **left ventricular outflow** tract demonstrated normal laminar flow and subjective structural integrity. The **right atrium** and auricle revealed normal size, structure and content. No evidence of masses was noted or chamber overload. **Tricuspid** insufficiency was noted. The **right ventricle** was of normal size (1/3 diameter of LV), chordae structure, myocardial echogenicity and thickness. **Pulmonic** tract assessment revealed normal valve structure, laminar flow, and diameter (approx.1:1 pa/ao ratio). No visible **pericardial** or free pleura fluid was noted. No echographically detectable evidence of infiltrative disease was visible. The cranial **mediastinum and pericardial regions** were free of masses in the visible window. The hepatic veins were not dilated on sweep of the liver.

ULTRASONOGRAPHIC FINDINGS

- Stage B-1 valvular disease
- Mild early pulmonary hypertension



PATIENT

- No volume overload noted at this time

Roxy Torres

INTERPRETATION OF THE FINDINGS & FURTHER RECOMMENDATIONS

SPECIES

The heart is stable without clinical disease. No overt contraindication for anesthesia of brief to moderate duration. I suggest Torbutrol premed, Propofol induction, Isoflor maintenance or similar protocol if anesthesia is desired. Blood pressure recommended if not already performed and target white coat negative systolic pressure of < 160 mmHg. If higher than this ACE-inhibitor is suggested to reach this level. Recheck echocardiogram is recommended in 6 months, earlier if murmur grade increases or clinical signs initiate.

Canine

BREED

Cavalier King Charles

SEX

Spayed Female

AGE

9 Years

WEIGHT

26.9 Pounds

INTERPRETED BY

Eric Lindquist, DMV
DABVP, Cert. IVUSS

IMAGING PERFORMED BY

Kely Vazquez

HOSPITAL NAME

Sova AH

REFERRING VET

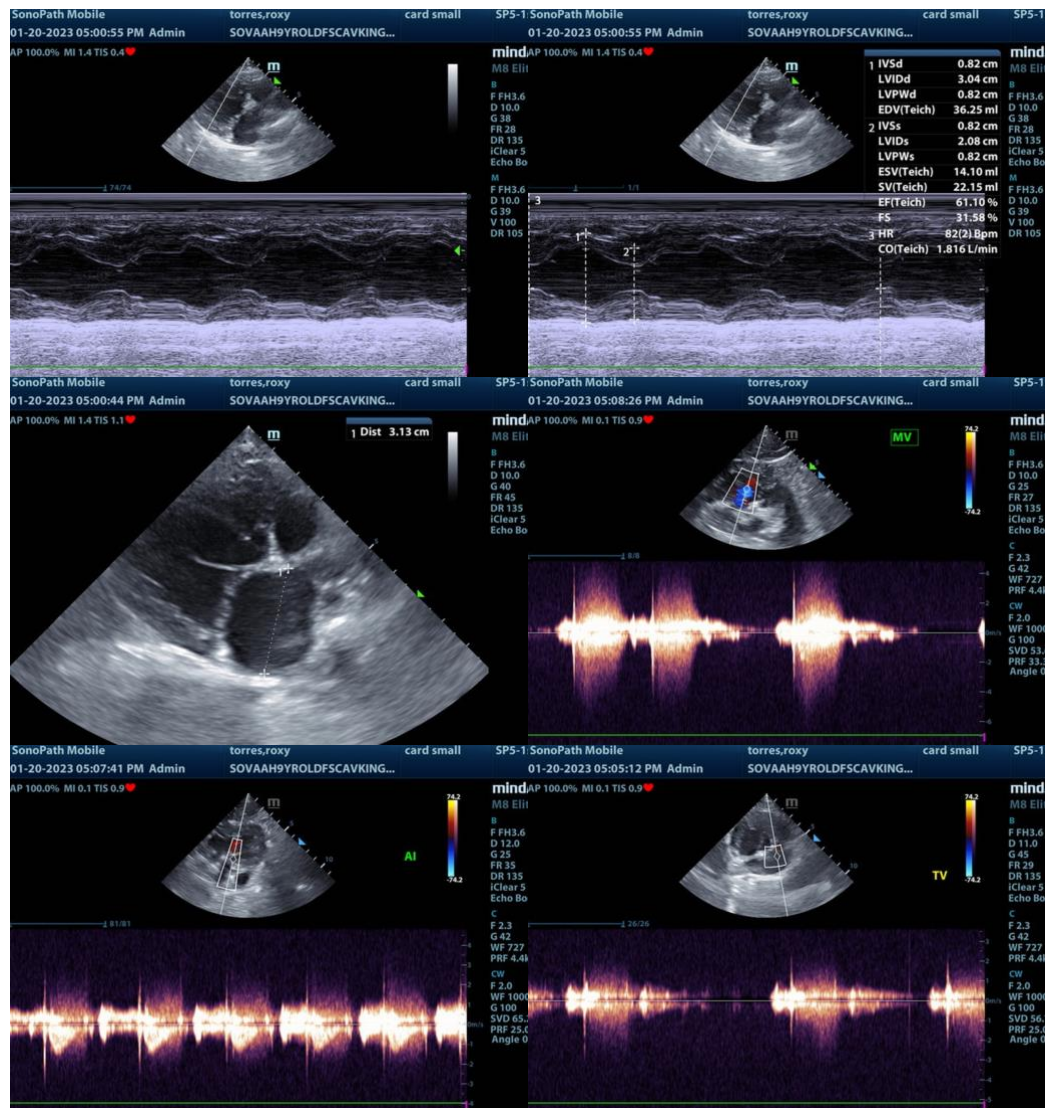
Dr. Ammeraal

INVOICE

20664

DATE

1/20/23





PATIENT

Roxy Torres

SPECIES

Canine

BREED

Cavalier King Charles

SEX

Spayed Female

AGE

9 Years

WEIGHT

26.9 Pounds

INTERPRETED BY

Eric Lindquist, DMV
DABVP, Cert. IVUSS

IMAGING PERFORMED BY

Kely Vazquez

HOSPITAL NAME

Sova AH

REFERRING VET

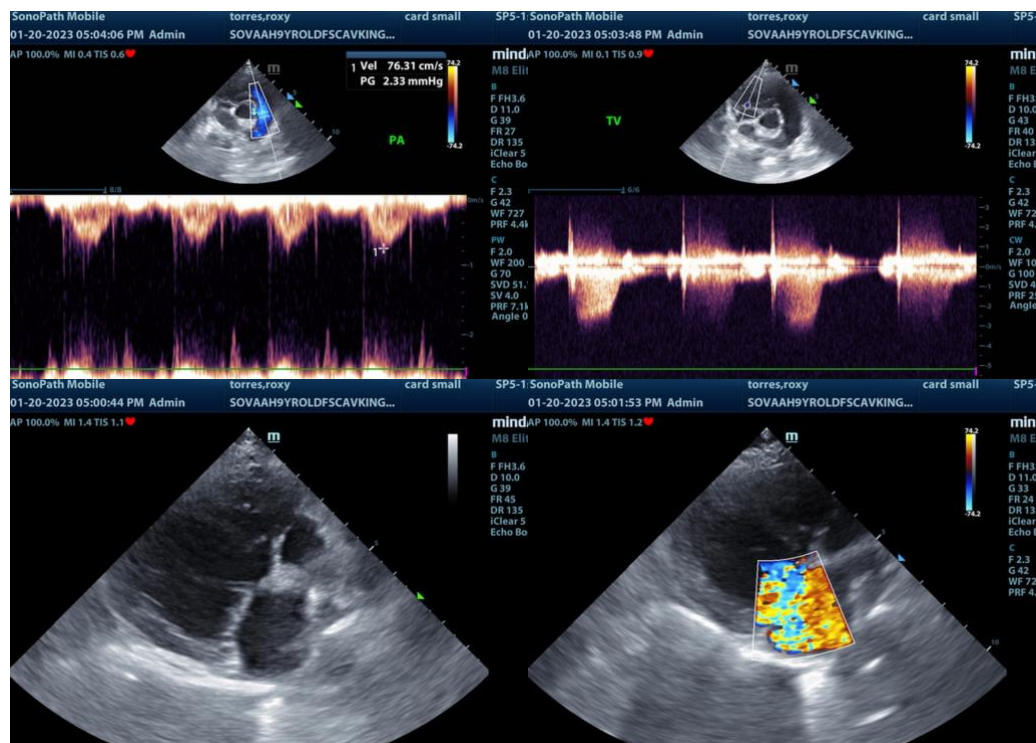
Dr. Ammeraal

INVOICE

20664

DATE

1/20/23



The information and recommendations provided are based on the images presented by the referring veterinarian. No evaluation can be communicated regarding pathology that was not visible in the image/video clips provided.

Thank you for this referral. If the clinical or image interpretation does not parallel your findings or if I can be of any further assistance please contact me.

Eric Lindquist, DMV, DABVP, Cert. IVUSS, CEO of SonoPath.com
info@SonoPath.com