



PATIENT

Remy Golaszewski

SPECIES

Canine

BREED

Frenchie

SEX

Neutered male

AGE

3 years

WEIGHT

22.3 lbs

INTERPRETED BY

Eric Lindquist, DMV
DABVP, Cert. IVUSS

IMAGING PERFORMED BY

Jenn

HOSPITAL NAME

Rockaway

REFERRING VET

Dr. Maniar

INVOICE

42254

DATE

1/20/23

PRESENTING CLINICAL SIGNS

History: acute onset anorexia concern for gastric fb on rads with secondary gas filling intestines
Current meds PLYte Pepcis Metro
Abnormal PE/Chem/CBC/UA Results: WNL CPL norm

ULTRASONOGRAPHIC EXAMINATION OF THE ABDOMEN

Urinary System

The **urinary bladder**, trigone, and pelvic urethra presented normal thicknesses and normal tone. The ureters were not visible which is normal. No uroliths or sediment were visualized and anechoic urine was present. No evidence of inflammatory or neoplastic changes was noted. Ureteral papillae were normal.

The **kidneys** revealed normal size and structure, corticomedullary definition and ratio for this age. The cortices presented largely uniform texture with normal echogenic relationship to liver and spleen. Medullary structure differed distinctly from the cortex and no evidence of pelvic dilation was present. The capsules were acceptably uniform without significant irregularities. The right kidney measured 4.8 cm. The left kidney measured 4.97 cm.

Adrenal Glands

Both **adrenal glands** were visualized and recognized as having normal shape, size, position and echogenicity for this breed. The phrenic vasculature, glandular echogenicity and detail were unremarkable. Capsule, cortex, and medullary definition were normal for this age patient. The left adrenal gland measured 2.11 x 0.49 cm at the caudal pole and 0.49 cm at the cranial pole. The right adrenal gland measured 2.0 x 1.0 cm at the cranial pole and 0.53 cm at the caudal pole.

Spleen

The **spleen** presented a smooth homogeneous parenchyma hyperechoic to liver and renal cortical parenchyma. The capsule was smooth without noticeable expansion or deviation from within the spleen or adjacent pathology. The splenic vasculature demonstrated normal volume without signs of congestion or thrombosis. No sonographic evidence of acute or chronic inflammatory, neoplastic, or infarctual changes was noted.

Liver

The **liver** images submitted revealed subjectively normal liver size, contour, and structure. Parenchymal echogenicity was naturally coarse and hypoechoic to the spleen. Vascular and biliary tracts were of normal volume with no evidence of congestion. The gallbladder presented acceptably thin walls with primarily anechoic content. The cystic and common bile ducts were normal. No pathological hepatic lymphadenopathy was evident. No overt structural evidence of inflammatory, infiltrative or regenerative pathology was evident.



PATIENT

Gastrointestinal

Remy Golaszewski

The **stomach** in this patient presented shadowing structure that measured 4.0 cm. A minor amount of luminal fluid was noted. The stomach had prominent mucosal changes. The pylorus was patent. The small intestines and colon were unremarkable.

SPECIES

Canine

Pancreas

BREED

Frenchie

The base and limbs of the **pancreas** were observed to be largely isoechoic to surrounding omental fat. Pancreatic duct and capsular contour were acceptably normal and parenchyma respected normal curvilinear patterns. No overt evidence of active inflammatory or neoplastic disease was noted.

SEX

Neutered male

ULTRASONOGRAPHIC FINDINGS

Gastric foreign body, non-obstructive. This appears to be fairly passive.

AGE

3 years

INTERPRETATION OF THE FINDINGS & FURTHER RECOMMENDATIONS

Gastrotomy with gastric biopsies are indicated or possible endoscopy with retrieval and gastric biopsies. The foreign body was non-obstructive at the time of the sonogram.

WEIGHT

22.3 lbs

INTERPRETED BY

Eric Lindquist, DMV
DABVP, Cert. IVUSS

IMAGING PERFORMED BY

Jenn

HOSPITAL NAME

Rockaway

REFERRING VET

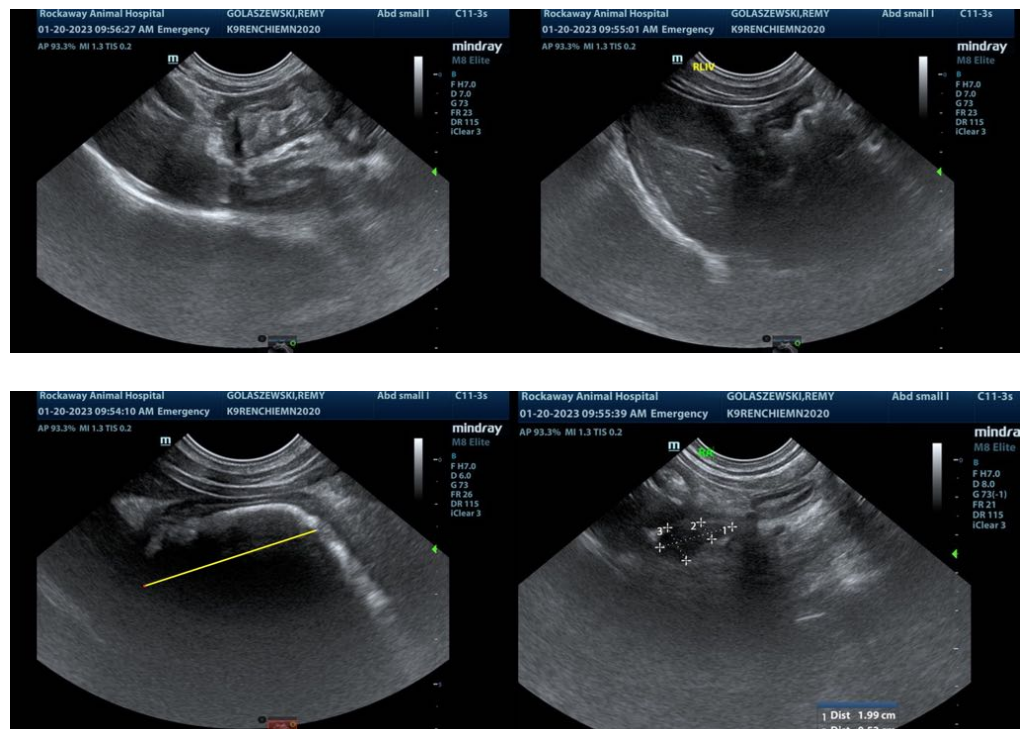
Dr. Maniar

INVOICE

42254

DATE

1/20/23





PATIENT

Remy Golaszewski

SPECIES

Canine

BREED

Frenchie

SEX

Neutered male

AGE

3 years

WEIGHT

22.3 lbs

INTERPRETED BY

Eric Lindquist, DMV
DABVP, Cert. IVUSS

IMAGING PERFORMED BY

Jenn

HOSPITAL NAME

Rockaway

REFERRING VET

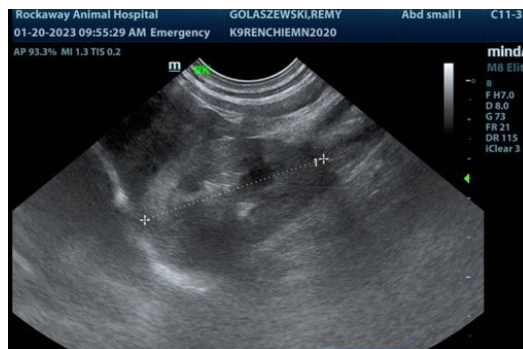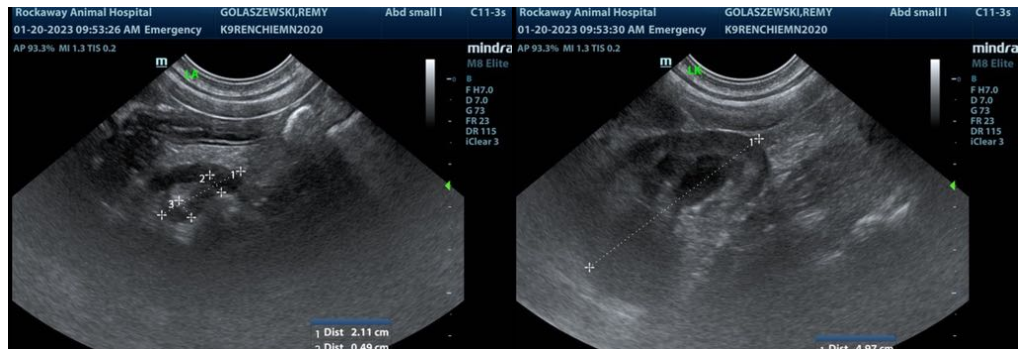
Dr. Maniar

INVOICE

42254

DATE

1/20/23



The information and recommendations provided are based on the images presented by the referring veterinarian/sonographer. No evaluation can be communicated regarding pathology that was not visible in the image/video clips provided.

Thank you for this referral. If the clinical or image interpretation does not parallel your findings or if I can be of any further assistance please contact me.

Eric Lindquist, DMV, DABVP, Cert. IVUSS, CEO of SonoPath.com
info@SonoPath.com