



PATIENT

Lola Velez

SPECIES

Canine

BREED

Cocker Spaniel

SEX

Spayed Female

AGE

1 Year

WEIGHT

25.8 Pounds

INTERPRETED BY

Eric Lindquist, DMV

DABVP, Cert. IVUSS

IMAGING PERFORMED BY

Val Shumskaya

HOSPITAL NAME

Englewood Vet Center

REFERRING VET

Dr. Ezik

INVOICE

44401

DATE

1/20/23

PRESENTING CLINICAL SIGNS

Hit by car in September that caused liver enzymes to elevate - Liver enzymes were normalized

Abnormal PE/Chem/CBC/UA Results: Still tests positive for cPLI - other bw clinically normal.

ULTRASONOGRAPHIC EXAMINATION OF THE ABDOMEN

Urinary System

The **urinary bladder**, trigone, and pelvic urethra presented normal thicknesses and normal tone. The ureters were not visible which is normal. No uroliths or sediment were visualized and anechoic urine was present. No evidence of inflammatory or neoplastic changes were noted. Ureteral papillae were normal. The pelvic urethra was imaged 2.0 cm beyond the cystourethral junction.

The **kidneys** revealed normal size and structure, corticomedullary definition and ratio for this age. The cortices presented largely uniform texture with normal echogenic relationship to liver and spleen. Medullary structure differed distinctly from the cortex and no evidence of pelvic dilation was present. The capsules were acceptably uniform without significant irregularities. The left kidney measured 3.87 cm.

Adrenal Glands

Both **adrenal glands** were visualized and recognized as having normal shape, size, position and echogenicity for this breed. The phrenic vasculature, glandular echogenicity and detail were unremarkable. Capsule, cortex, and medullary definition were normal for this age patient. The left adrenal gland measured 1.64 cm x 0.45 cm at the cranial pole and 0.44 cm at the caudal pole. The right adrenal gland measured 1.88 cm x 0.91 cm at the cranial pole and 0.36 cm at the caudal pole.

Spleen

The **spleen** presented a smooth homogeneous parenchyma hyperechoic to liver and renal cortical parenchyma. The capsule was smooth without noticeable expansion or deviation from within the spleen or adjacent pathology. The splenic vasculature demonstrated normal volume without signs of congestion or thrombosis. No sonographic evidence of acute or chronic inflammatory, neoplastic, or infarctual changes were noted.

Liver

The **liver** was mildly subnormal in size with increased portal markings. The gallbladder and common bile duct were unremarkable. Portal vein to vena cava ratio was 1:1. No overt evidence of portosystemic shunting.

Gastrointestinal

There was some residual chyme and gas was noted in the **stomach**, yet not pathological. This is consistent with end post prandial presentation. Transit of chyme into the small intestine was normal. Curvilinear patterns were maintained throughout the GI tract. No evidence of pathology. Small and large intestine demonstrated normal luminal chyme and stool consistency respectively. No obstructive or overt infiltrative disease was noted. No associated abnormal lymphatic activity was noted.

Pancreas

The base and limbs of the **pancreas** were observed to be largely isoechoic to surrounding omental fat. Pancreatic duct and capsular contour were acceptably normal and parenchyma respected normal curvilinear patterns. No overt evidence of active inflammatory or neoplastic disease was noted.



PATIENT

Lola Velez

SPECIES

Canine

BREED

Cocker Spaniel

SEX

Spayed Female

AGE

1 Year

WEIGHT

25.8 Pounds

INTERPRETED BY

Eric Lindquist, DMV

DABVP, Cert. IVUSS

IMAGING PERFORMED BY

Val Shumskaya

HOSPITAL NAME

Englewood Vet Center

REFERRING VET

Dr. Ezik

INVOICE

44401

DATE

1/20/23

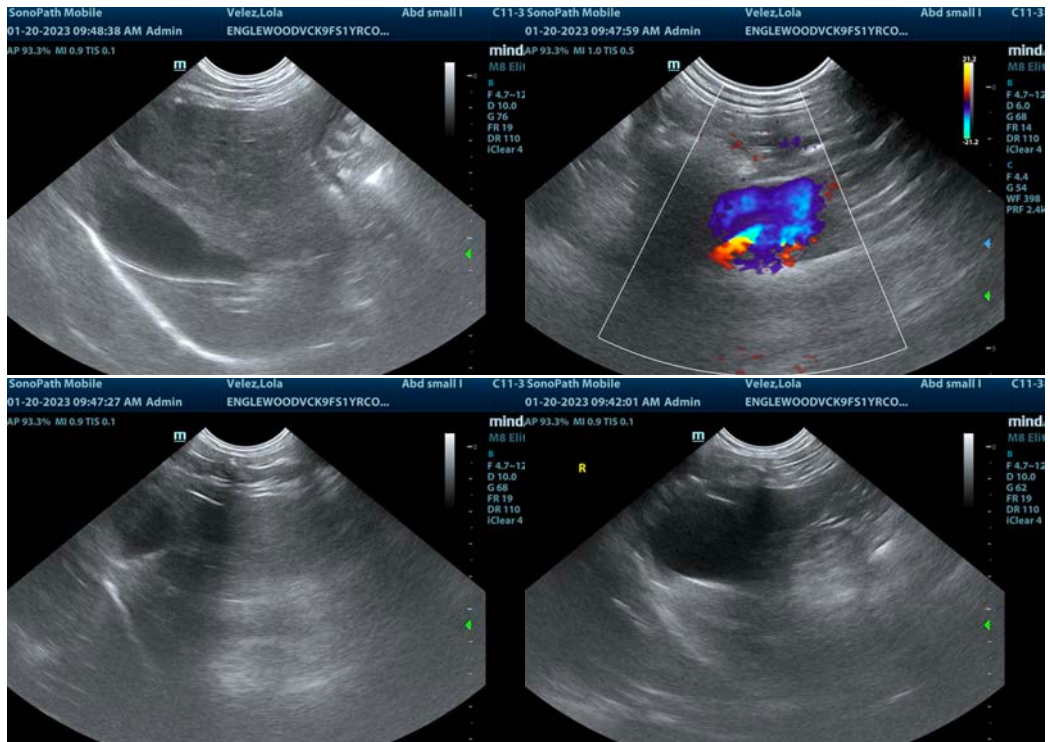
ULTRASONOGRAPHIC FINDINGS

- Mild microhepatica with slight increased portal markings – non-specific inflammatory hepatopathy.
- Partially full stomach

INTERPRETATION OF THE FINDINGS & FURTHER RECOMMENDATIONS

FNA of the liver could be considered for assessment of inflammatory cell type. Possible reactive hepatopathy. No structural evidence of pancreatitis.

The hepatic clinical sonographic presentation is most consistent with Reactive Hepatopathy which is the most common cause of liver enzyme elevation in dogs and cats. The presumption is that gut and other organ antigen stimuli may be causing a low-grade immune response through portal system with which the liver is reacting to causing low-grade enzyme elevations. US-guided FNA could be performed to assess if low grade lymphoplasmacytic inflammation is present that would support this theory. If FNA is performed, please ask the cytologist to emphasize the primary inflammatory cell type. Empirical treatment measures to address this issue can include diet change to hydrolyzed diet, probiotics, deworming, nutraceuticals (SAME, Actigall...), dental exam and cleaning, and potentially antibiotics such as Clavamox. Metronidazole and Tylosin have traditionally been utilized for this purpose but new studies show that both these antibiotics can disrupt the normal intestinal bacterial flora (intestinal dysbiosis) for weeks and up to 4-6 months. Therefore, Metronidazole and Tylosin should be utilized as a last resort if other efforts have not been effective and sonographic organ appearance remains benign.=





PATIENT

Lola Velez

SPECIES

Canine

BREED

Cocker Spaniel

SEX

Spayed Female

AGE

1 Year

WEIGHT

25.8 Pounds

INTERPRETED BY

Eric Lindquist, DMV

DABVP, Cert. IVUSS

IMAGING PERFORMED BY

Val Shumskaya

HOSPITAL NAME

Englewood Vet Center

REFERRING VET

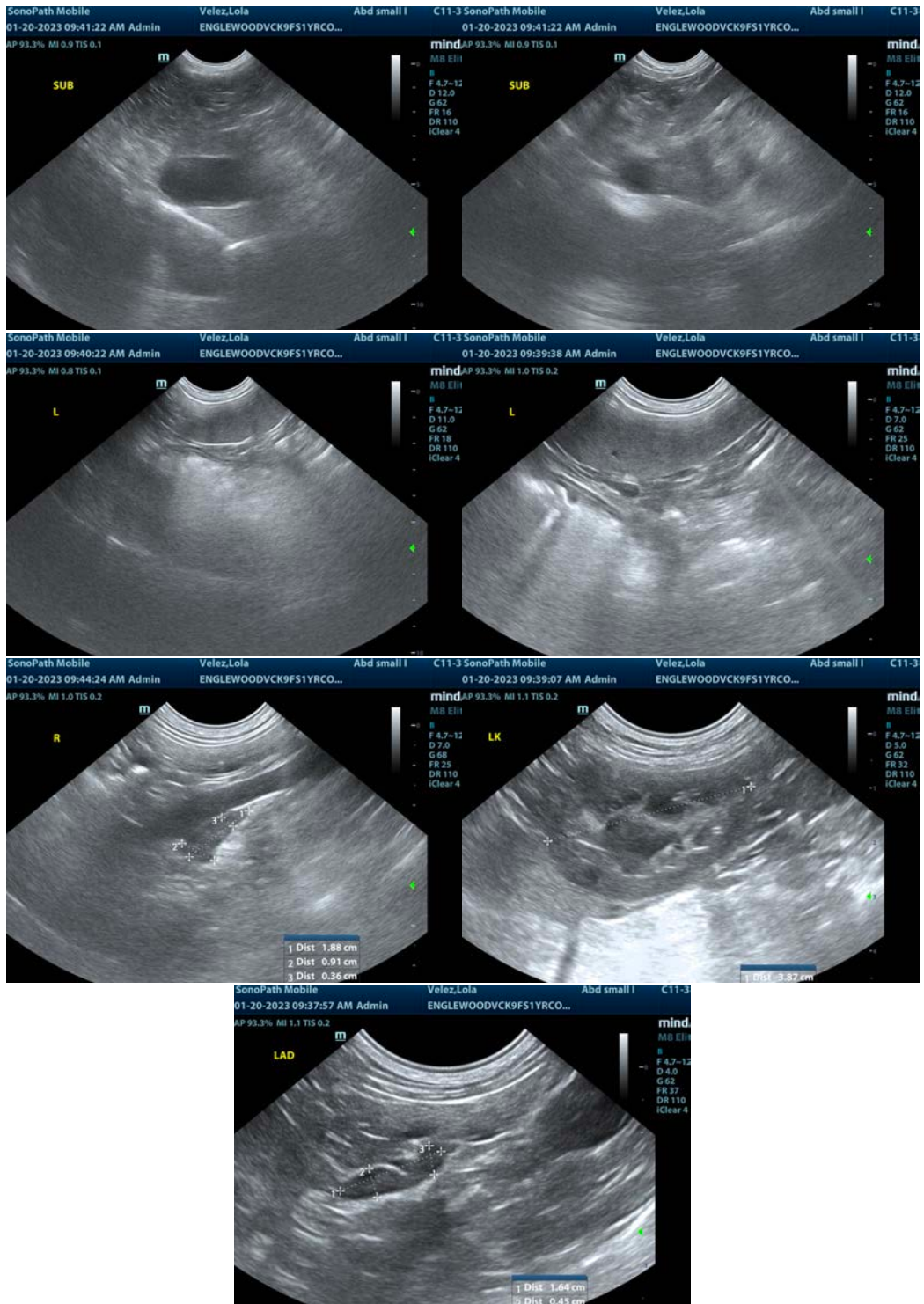
Dr. Ezik

INVOICE

44401

DATE

1/20/23





PATIENT

Lola Velez

The information and recommendations provided are based on the images presented by the referring veterinarian/sonographer. No evaluation can be communicated regarding pathology that was not visible in the image/video clips provided.

SPECIES

Canine

Thank you for this referral. If the clinical or image interpretation does not parallel your findings or if I can be of any further assistance please contact me.

BREED

Cocker Spaniel

Eric Lindquist, DMV, DABVP, Cert. IVUSS, CEO of SonoPath.com

info@SonoPath.com

SEX

Spayed Female

AGE

1 Year

WEIGHT

25.8 Pounds

INTERPRETED BY

Eric Lindquist, DMV

DABVP, Cert. IVUSS

IMAGING PERFORMED BY

Val Shumskaya

HOSPITAL NAME

Englewood Vet Center

REFERRING VET

Dr. Ezik

INVOICE

44401

DATE

1/20/23