

PATIENT

Fenway Mullikin

PRESENTING CLINICAL SIGNS

Decreased appetite, intermittent vomiting

SPECIES

Canine

Abnormal PE/Chem/CBC/UA Results: Very mild icterus, bloodwork pending

LIMITED ULTRASONOGRAPHIC EXAMINATION

BREED

Golden Retriever

The spleen revealed an infiltrative pattern with multiple cystic and parenchymal masses.

The liver was riddled with multiple coalescing, distorted target lesions, with irregular contour and expansive masses.

SEX

Male

Pericardial effusion noted through the diaphragm.

ULTRASONOGRAPHIC FINDINGS

AGE

8 Years

- Splenohepatic neoplasia – aggressive sarcoma type pattern.
- Pericardial effusion

INTERPRETATION OF THE FINDINGS & FURTHER RECOMMENDATIONS

Echocardiogram recommended to assess for right auricular masses, as well as full abdominal sonogram. Immediate chemotherapeutic intervention recommended.

INTERPRETED BY

Eric Lindquist, DMV
DABVP, Cert. IVUSS

IMAGING PERFORMED BY

Dr. Amanda Favis

HOSPITAL NAME

Ruidoso AC

REFERRING VET

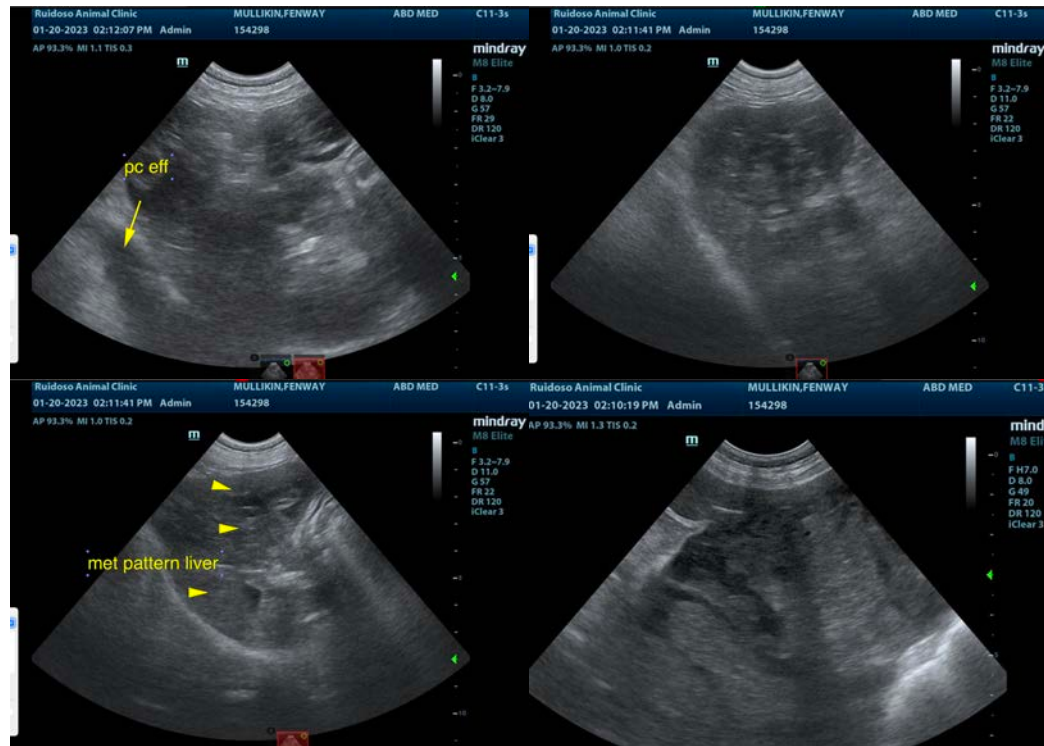
Dr. Amanda Favis

INVOICE

44413

DATE

1/20/23





PATIENT

Fenway Mullikin

The information and recommendations provided are based on the images presented by the referring veterinarian/sonographer. No evaluation can be communicated regarding pathology that was not visible in the image/video clips provided.

SPECIES

Canine

Thank you for this referral. If the clinical or image interpretation does not parallel your findings or if I can be of any further assistance please contact me.

BREED

Golden Retriever

Eric Lindquist, DMV, DABVP, Cert. IVUSS, CEO of SonoPath.com

info@SonoPath.com

SEX

Male

AGE

8 Years

WEIGHT

66 Pounds

INTERPRETED BY

Eric Lindquist, DMV

DABVP, Cert. IVUSS

IMAGING PERFORMED BY

Dr. Amanda Favis

HOSPITAL NAME

Ruidoso AC

REFERRING VET

Dr. Amanda Favis

INVOICE

44413

DATE

1/20/23