

IMAGING PERFORMED BY

IntraPet.com



 **SonoPath**

Clinical Sonography & Telectology

EDUCATIONAL TELECONSULTATION SERVICES™

1-800-838-4268 [info@sonopath.com](mailto:info@sonopath.com) [Sonopath.com](http://Sonopath.com)

**DATE**

1/20/23

**PRESENTING CLINICAL SIGNS**

Losing weight. Possible abdominal mass.

**PATIENT**

Blackie Himmel

Current Medications: None.  
Date of Previous IntraPet Ultrasound: No previous.  
Sedation: Not required to complete full diagnostic ultrasound.  
Stat Report: Not requested.  
Imaging Performed By: Rachel Brillhart, RDMS.

**SPECIES**

Feline

**ULTRASONOGRAPHIC EXAMINATION OF THE ABDOMEN**

**BREED**

DSH

**Urinary System**

The **urinary bladder**, trigone, and pelvic urethra presented normal thicknesses and normal tone. The ureters were not visible which is normal. No uroliths or sediment were visualized and anechoic urine was present. No evidence of inflammatory or neoplastic changes were noted. Ureteral papillae were normal.

**SEX**

Neutered Male

The **kidneys** presented a relatively uniform cortical hyperechogenicity when compared to the renal medulla, spleen and liver. No overt masses were noted. Corticomedullary definition was nebulous and the ratio favored the cortex slightly. The ureters were not visible and assumed to be normal. These changes are most consistent with chronic interstitial nephritis yet infiltrative disease could not be entirely ruled out without biopsy though neoplasia is not suspected. The right kidney measured 4.57 cm.

**AGE**

1/12/16

**WEIGHT**

8.4 Pounds

**Adrenal Glands**

Both **adrenal glands** were visualized and recognized as having normal shape, size, position and echogenicity for this breed. The phrenic vasculature, glandular echogenicity and detail were unremarkable. Capsule, cortex, and medullary definition were normal for this age patient. Mineralization noted in both adrenal glands. The right adrenal gland measured 0.40 cm.

**INTERPRETED BY**

Eric Lindquist, DMV  
DABVP, Cert. IVUSS

**Spleen**

The **spleen** in this patient was uniform, yet volume contracted. Hydration status should be assessed. The spleen measured up to 1.1 cm in width.

**HOSPITAL NAME**

Forest Hill Vet

**Liver**

The **liver** presented mild coarse architecture and slight irregular contour. The gallbladder and common bile duct were unremarkable. Minor increased portal markings. Hepatic lymph nodes enlarged.

**REFERRING VET**

Dr. Saad

**Gastrointestinal**

The **stomach** itself was unremarkable. The intestinal tract revealed variable thickening with two infiltrative masses, one in the jejunum measuring 3.2 cm x 2.8 cm, an ileocecal mass measuring 2.0 cm x 1.5 cm, and a regional lymph node mass measuring 2.0 cm. This is consistent with multicentric neoplasia. Multifocal lymphadenopathy and reactive mesentery noted.

**INVOICE**

44408

**Pancreas**

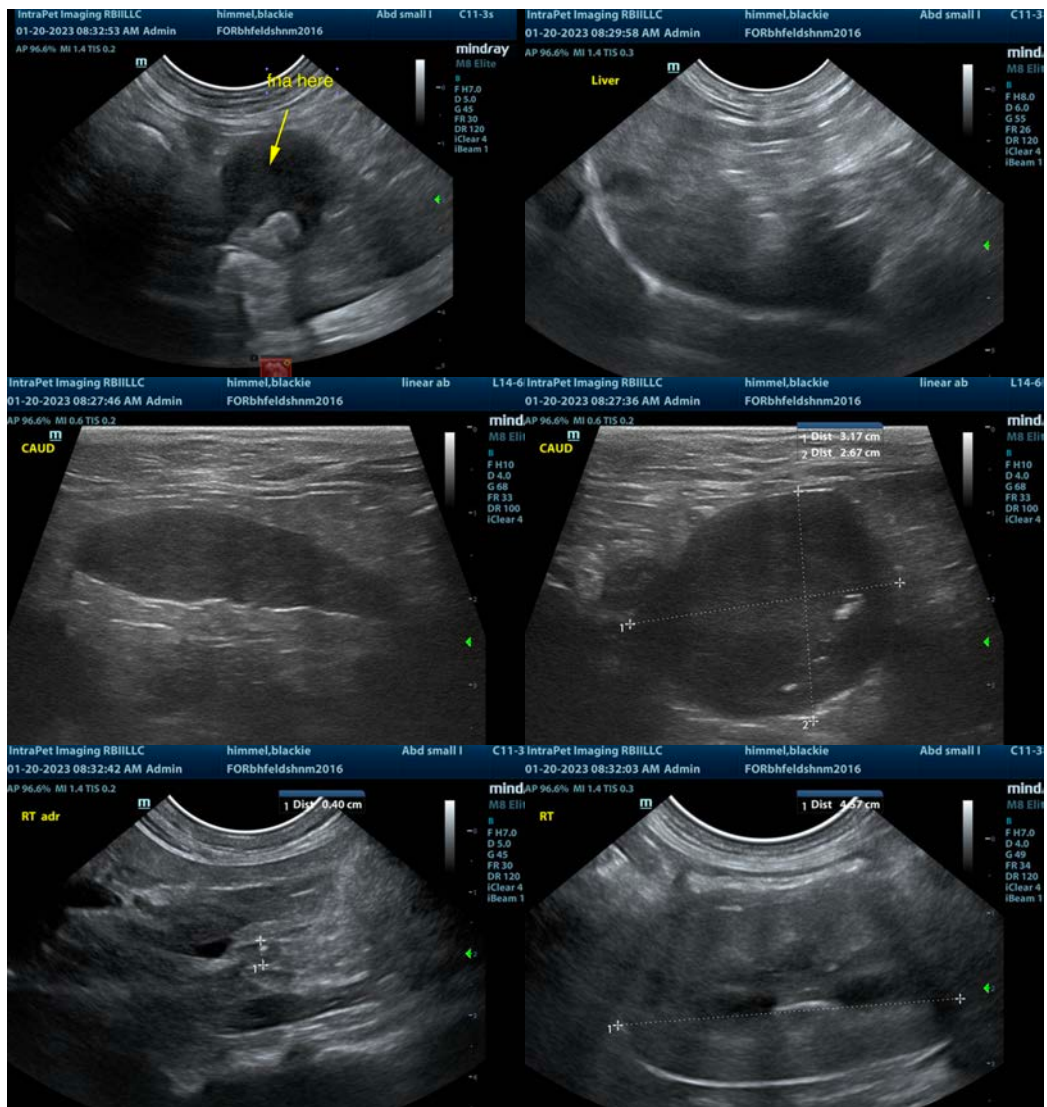
The base and limbs of the **pancreas** were observed to be largely isoechoic to surrounding omental fat. Pancreatic duct and capsular contour were acceptably normal and parenchyma respected normal curvilinear patterns. No overt evidence of active inflammatory or neoplastic disease was noted.

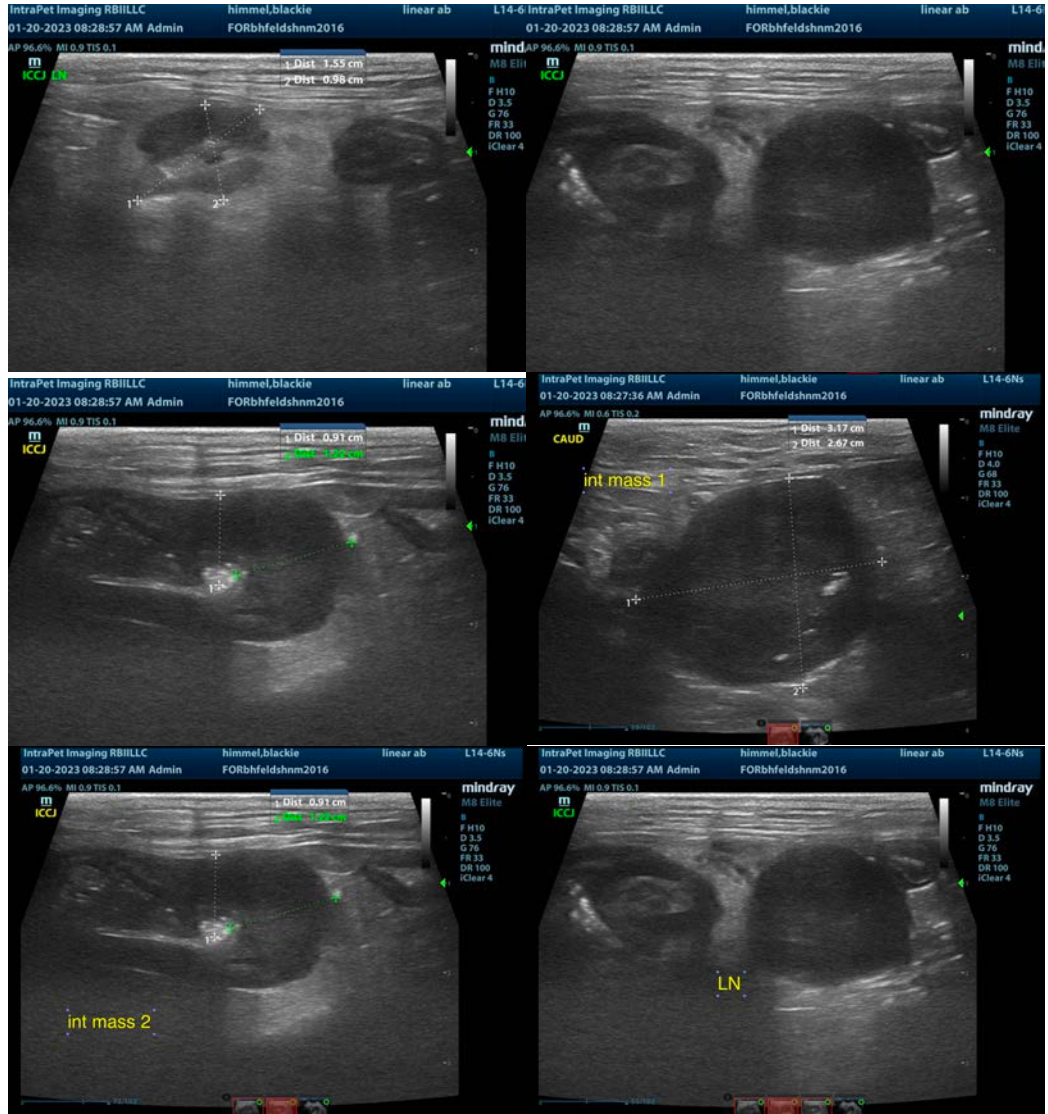
## ULTRASONOGRAPHIC FINDINGS

- Intestinal masses with possible splenic and hepatic involvement - consistent with multicentric neoplasia.
- Multifocal lymphadenopathy
- Interstitial nephrosis renal pattern

## INTERPRETATION OF THE FINDINGS & FURTHER RECOMMENDATIONS

Ultrasound guided FNA of the intestinal masses, largest accessible lymph node, spleen, and liver all indicated for staging purposes.





The information and recommendations provided are based on the images presented by the referring veterinarian/sonographer. No evaluation can be communicated regarding pathology that was not visible in the image/video clips provided.

Thank you for this referral. If the clinical or image interpretation does not parallel your findings or if I can be of any further assistance please contact me.

**Eric Lindquist, DMV, DABVP, Cert. IVUSS, CEO of SonoPath.com**  
[info@SonoPath.com](mailto:info@SonoPath.com)