



DATE PRESENTING CLINICAL SIGNS

1/20/22 History: Owner having a hard time housebreaking (veteran dog/puppy owner)- PU/PD, accidents, pollakiuria.

PATIENT Current Medications: 11/15/21- Clavamox x 10 days.
Lab Results: Urine C and S- neg. Attached separately.
Odie Kelly Date of Previous IntraPet Ultrasound: No previous IntraPet scans.
Sedation: IM dexdomitor.
Stat Report: Not requested.

SPECIES

Canine

BREED

Icelandaic Sheepdog

SEX

Intact Male

AGE

7/9/21

WEIGHT

22 Pounds

INTERPRETED BY

Eric Lindquist, DMV
DABVP, Cert. IVUSS

IMAGING PERFORMED BY

Rachel Brilhart RDMS

HOSPITAL NAME

Bay Country VH

REFERRING VET

Dr. Smith

INVOICE

34969

ULTRASONOGRAPHIC EXAMINATION OF THE ABDOMEN

Urinary System

The **urinary bladder**, trigone, and pelvic urethra presented normal thicknesses and normal tone. No uroliths or sediment were visualized and anechoic urine was present. No evidence of inflammatory or neoplastic changes were noted. The left ureter was slightly dilated and appeared to bypass the cystourethral junction and enter into the pre-prostatic urethra, bypassing the left ureteral papilla. Slight sublumbar lymphadenopathy noted, reactive, likely owing to juvenile enlargement.

The prostate was uniform at 1.52 cm.

The **kidneys** revealed normal size and structure, corticomedullary definition and ratio for this age. The cortices presented largely uniform texture with normal echogenic relationship to liver and spleen. Medullary structure differed distinctly from the cortex and no evidence of pelvic dilation was present. The capsules were acceptably uniform without significant irregularities. The right kidney measured 5.11 cm.

Adrenal Glands

Both **adrenal glands** were visualized and recognized as having normal shape, size, position and echogenicity for this breed. The phrenic vasculature, glandular echogenicity and detail were unremarkable. Capsule, cortex, and medullary definition were normal for this age patient. The left adrenal gland measured 2.38 cm x 0.39 cm at the caudal pole and 0.304 cm at the cranial pole. The right adrenal gland measured 2.37 cm 0.50 cm at the caudal pole and 0.57 cm at the cranial pole.

Spleen

The **spleen** was folded upon itself caudally, unremarkable otherwise.

Liver

The **liver** images submitted revealed subjectively normal liver size, contour, and structure. Parenchymal echogenicity was naturally coarse and hypoechoic to the spleen. Vascular and biliary tracts were of normal volume with no evidence of congestion. The gallbladder presented acceptably thin walls with primarily anechoic content. The cystic and common bile ducts were normal. No pathological hepatic lymphadenopathy was evident. No overt structural evidence of inflammatory, infiltrative or regenerative pathology was evident.

Gastrointestinal

Examination of the **gastrointestinal tract** revealed a stomach and intestine free of stasis, of normal wall thickness, acceptable curvilinear mural detail, and peristaltic activity. Small and large intestine demonstrated

normal luminal chyme and stool consistency respectively. No obstructive or overt infiltrative disease was noted. No associated abnormal lymphatic activity was noted.

Pancreas

The base and limbs of the **pancreas** were observed to be largely isoechoic to surrounding omental fat. Pancreatic duct and capsular contour were acceptably normal and parenchyma respected normal curvilinear patterns. No overt evidence of active inflammatory or neoplastic disease was noted.

Free Abdomen

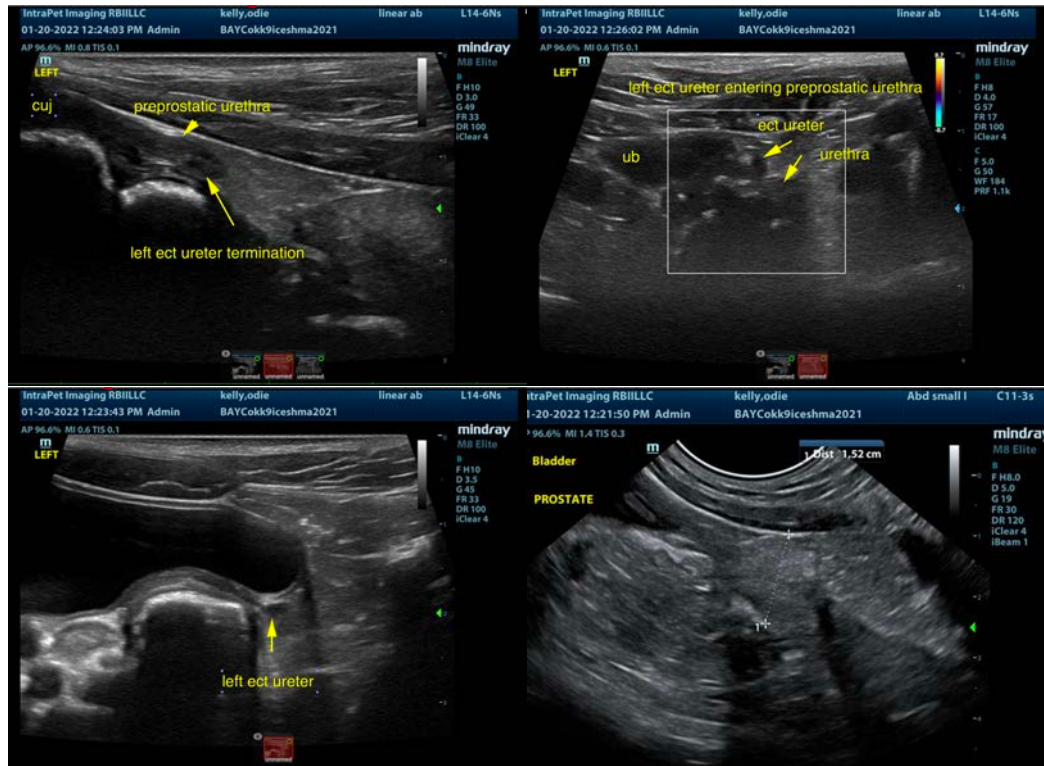
The testicles were imaged and found to be uniform, no evident pathology.

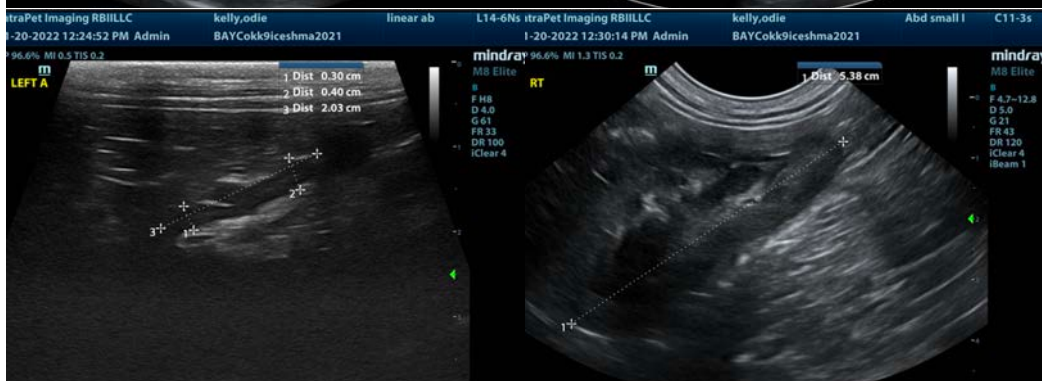
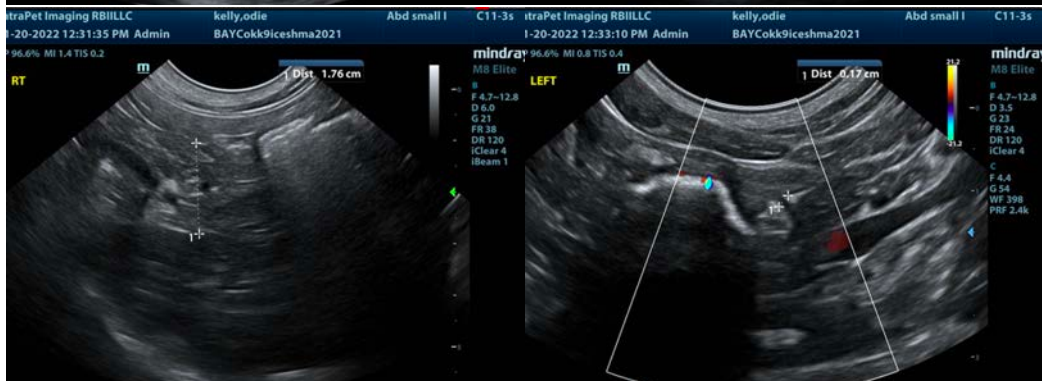
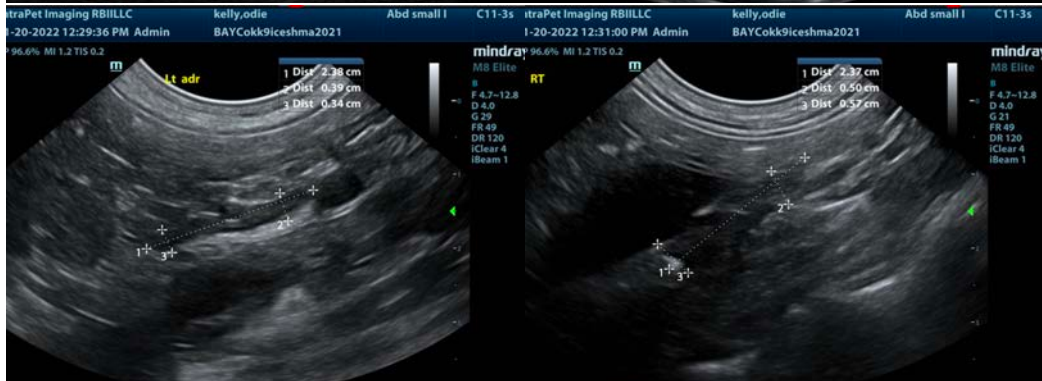
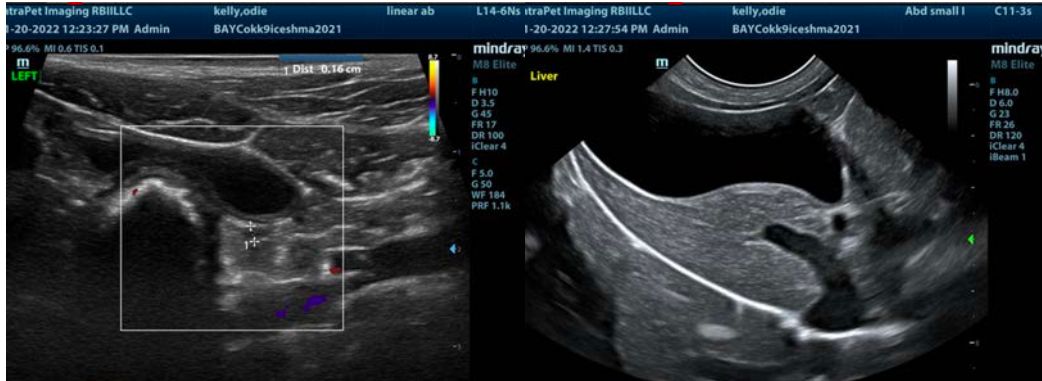
ULTRASONOGRAPHIC FINDINGS

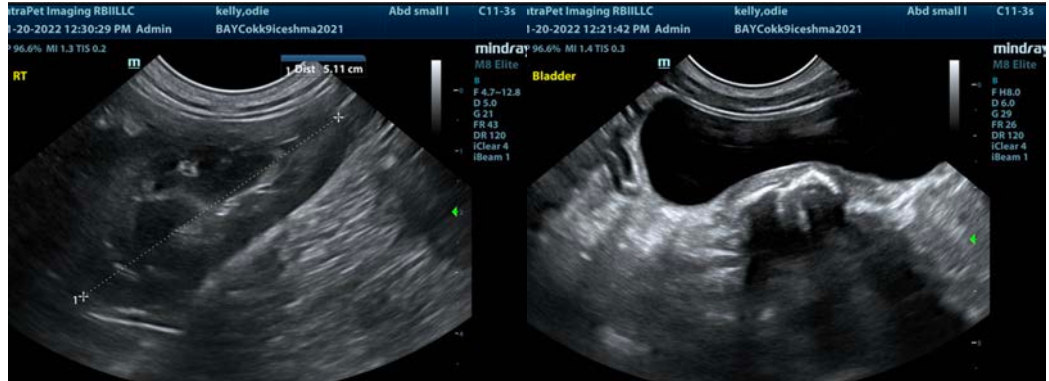
- Left ectopic ureter with termination in the pre-prostatic urethra

INTERPRETATION OF THE FINDINGS & FURTHER RECOMMENDATIONS

Recommend IVP or CT with contrast to confirm, given the small size of the suspected ectopic ureter. However, it appears to be quite definitive on ultrasound. Surgical consultation recommended.







The information and recommendations provided are based on the images presented by the referring veterinarian. No evaluation can be communicated regarding pathology that was not visible in the image/video clips provided.

Thank you for this referral. If the clinical or image interpretation does not parallel your findings or if I can be of any further assistance please contact me.

Eric Lindquist, DMV, DABVP, Cert. IVUSS, CEO of SonoPath.com
info@SonoPath.com