



PATIENT

Nola Pearlstein

SPECIES

Canine

BREED

Goldendoodle

SEX

Spayed Female

AGE

7 Months

WEIGHT

22.8 Pounds

INTERPRETED BY

Eric Lindquist, DMV
DABVP, Cert. IVUSS

IMAGING PERFORMED BY

Dr. Rodriguez

HOSPITAL NAME

Foxfield Vet Services

REFERRING VET

Dr. Rodriguez

INVOICE

34392

DATE

1/20/22

PRESENTING CLINICAL SIGNS

Uncomfortable. Vomited and lethargic. Seen at ER and they dx toy in colon and rec monitor. No improvement and unwilling to eat.
Abnormal PE/Chem/CBC/UA Results: Pending

ULTRASONOGRAPHIC EXAMINATION OF THE ABDOMEN

Urinary System

The **urinary bladder**, trigone, and pelvic urethra presented normal thicknesses and normal tone. The ureters were not visible which is normal. No uroliths or sediment were visualized and anechoic urine was present. No evidence of inflammatory or neoplastic changes were noted. Ureteral papillae were normal.

The **kidneys** revealed normal size and structure, corticomedullary definition and ratio for this age. The cortices presented largely uniform texture with normal echogenic relationship to liver and spleen. Medullary structure differed distinctly from the cortex and no evidence of pelvic dilation was present. The capsules were acceptably uniform without significant irregularities. The right kidney measured 3.86 cm. The left kidney measured 4.22 cm.

Adrenal Glands

Both **adrenal glands** were visualized and recognized as having normal shape, size, position and echogenicity for this breed. The phrenic vasculature, glandular echogenicity and detail were unremarkable. Capsule, cortex, and medullary definition were normal for this age patient. The right adrenal gland measured 1.98 cm x 0.66 cm. The left adrenal gland measured 1.82 cm x 0.48 cm.

Spleen

The **spleen** presented a smooth homogeneous parenchyma hyperechoic to liver and renal cortical parenchyma. The capsule was smooth without noticeable expansion or deviation from within the spleen or adjacent pathology. The splenic vasculature demonstrated normal volume without signs of congestion or thrombosis. No sonographic evidence of acute or chronic inflammatory, neoplastic, or infarctual changes were noted.

Liver

The **liver** images submitted revealed subjectively normal liver size, contour, and structure. Parenchymal echogenicity was naturally coarse and hypoechoic to the spleen. Vascular and biliary tracts were of normal volume with no evidence of congestion. The gallbladder presented acceptably thin walls with primarily anechoic content. The cystic and common bile ducts were normal. No pathological hepatic lymphadenopathy was evident. No overt structural evidence of inflammatory, infiltrative or regenerative pathology was evident.

Gastrointestinal

The **stomach** presented hypertrophied pyloric mucosa with a minor amount of fluid filled lumen. The small intestine was hyperperistaltic, yet not obstructed. The cecum was dilated with excessive gas and fluid continuing into the colon, consistent with typhlitis.

Pancreas

The base and limbs of the **pancreas** were observed to be largely isoechoic to surrounding omental fat. Pancreatic duct and capsular contour were acceptably normal and parenchyma respected normal curvilinear patterns. No overt evidence of active inflammatory or neoplastic disease was noted.



PATIENT

Nola Pearlstein

ULTRASONOGRAPHIC FINDINGS

- Gastroenteritis/typhlitis pattern, no evidence of obstruction

SPECIES

Canine

INTERPRETATION OF THE FINDINGS & FURTHER RECOMMENDATIONS

IV fluid support, broad-spectrum antibiotics and recheck sonogram in 48-72 hours if the patient is not responding. GI protectants also indicated.

BREED

Goldendoodle

SEX

Spayed Female

AGE

7 Months

WEIGHT

22.8 Pounds

INTERPRETED BY

Eric Lindquist, DMV
DABVP, Cert. IVUSS

IMAGING PERFORMED BY

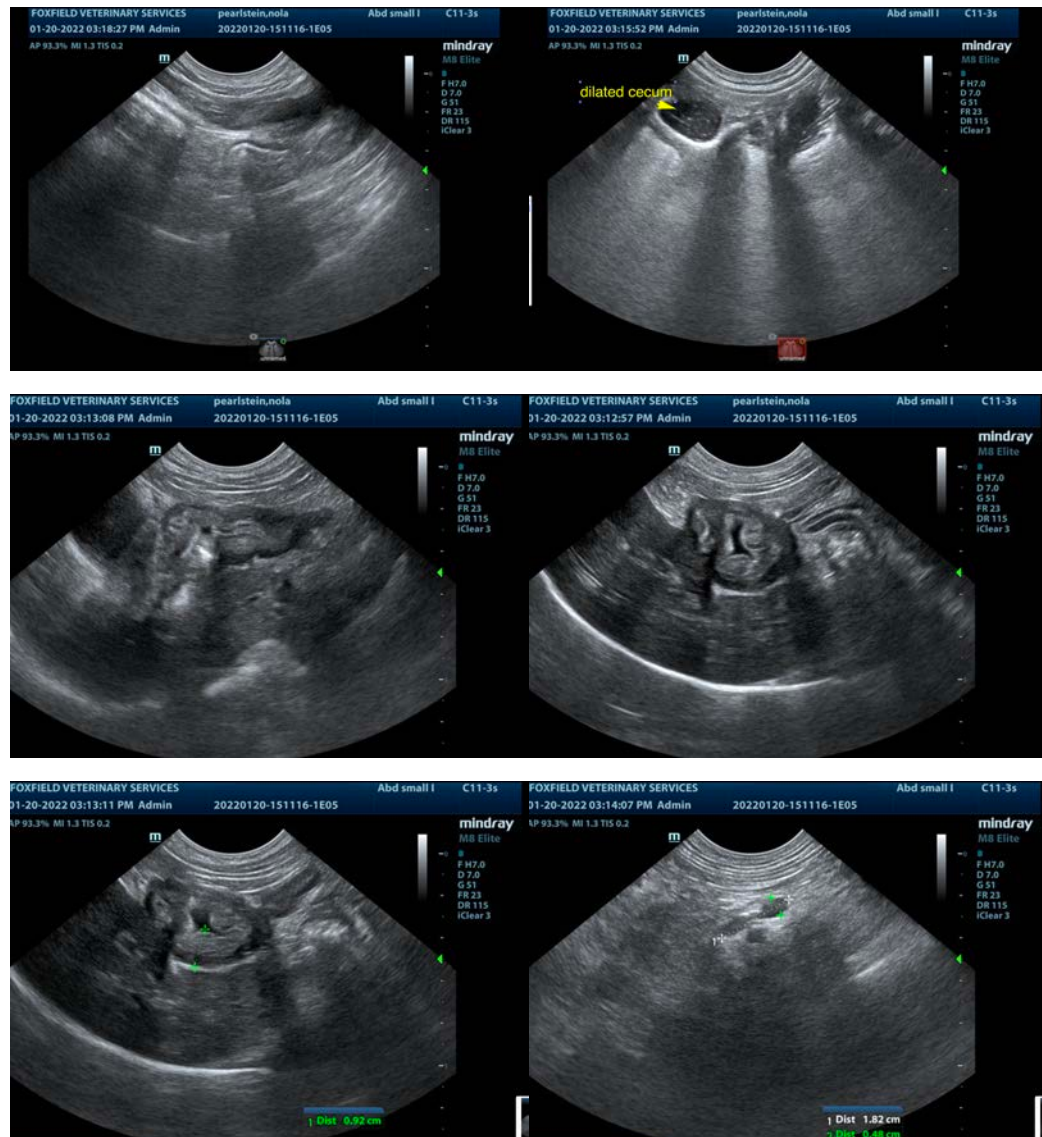
Dr. Rodriguez

HOSPITAL NAME

Foxfield Vet Services

REFERRING VET

Dr. Rodriguez



INVOICE

34392

DATE

1/20/22



PATIENT

Nola Pearlstein

SPECIES

Canine

BREED

Goldendoodle

SEX

Spayed Female

AGE

7 Months

WEIGHT

22.8 Pounds

INTERPRETED BY

Eric Lindquist, DMV
DABVP, Cert. IVUSS

IMAGING PERFORMED BY

Dr. Rodriguez

HOSPITAL NAME

Foxfield Vet Services

REFERRING VET

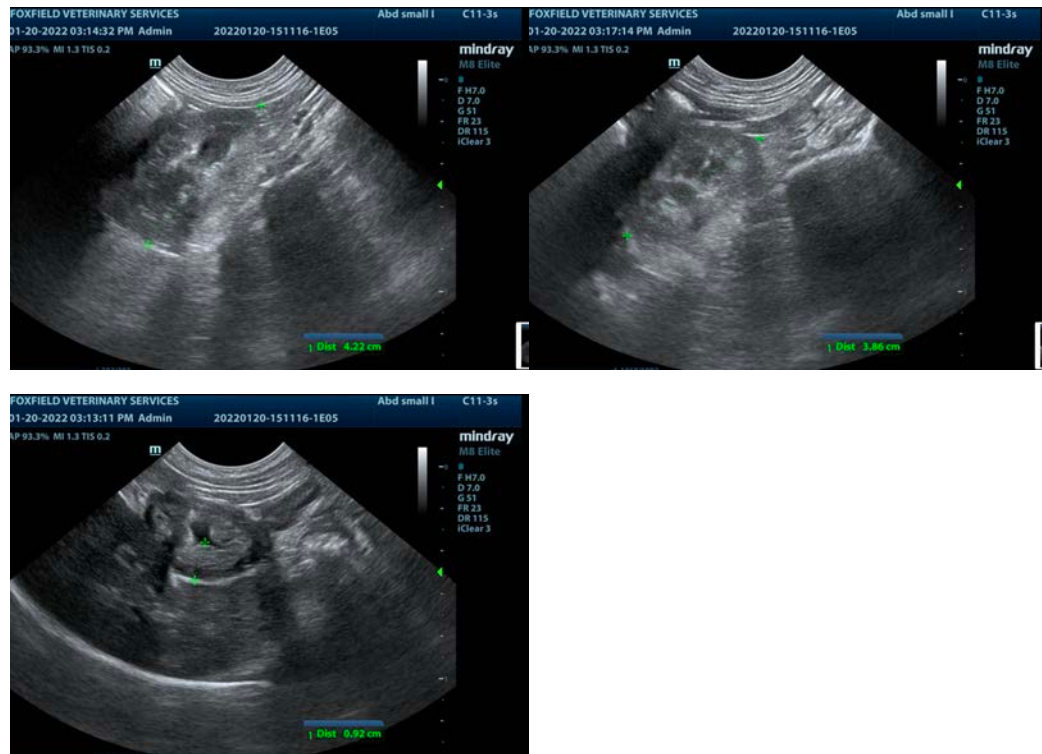
Dr. Rodriguez

INVOICE

34392

DATE

1/20/22



The information and recommendations provided are based on the images presented by the referring veterinarian. No evaluation can be communicated regarding pathology that was not visible in the image/video clips provided.

Thank you for this referral. If the clinical or image interpretation does not parallel your findings or if I can be of any further assistance please contact me.

Eric Lindquist, DMV, DABVP, Cert. IVUSS, CEO of SonoPath.com
info@SonoPath.com