



## PATIENT

Pumpkin Thomas

## SPECIES

Feline

## BREED

Maine Coon x

## SEX

Neutered Male

## AGE

15

## WEIGHT

6.8

## INTERPRETED BY

Eric Lindquist, DMV,  
DABVP (CFM), Cert.  
IVUSS

## IMAGING PERFORMED BY

Jenn

## HOSPITAL NAME

Rockaway Animal  
Hospital

## REFERRING VET

Dr. Kahn

## INVOICE

72904

## DATE

1/2/26

## PRESENTING CLINICAL SIGNS

weight loss needs dental Grade 3/6 HM  
Abnormal PE/Chem/CBC/UA Results: CBC normal Creat 2.8 BUN 43 all else WNL ProBnp abnormal

## ULTRASONOGRAPHIC EXAMINATION OF THE HEART & ABDOMEN

FELINE CARDIAC PARAMETERS	BODY WEIGHT (kg)	HR (BPM)	IVSd (cm)	LVIDd (cm)	LVWd (cm)	FS (%)	EF (%)
NORMAL PARAMETER	-----	150-240	0.3-0.6	1.0-2.1	0.25-0.6	35-67	80-100
PATIENT		NM	0.5	1.4	0.5	50	80
FELINE CARDIAC PARAMETERS	LA/AO (M-mode)	LA/AO HEART BASE (Sisson)	LAD LA MAX 4 Chamber		LVOT VEL. (m/s)	RVOT VEL. (m/s)	IVRT (m/)
NORMAL PARAMETER	<1.5	1.6	0.7-1.7		<1.6	<1.3	40-60
PATIENT	1.3	1.22					NM
Adapted from June Boon, Veterinary Echocardiography, 1998 Sisson D et al. JVIM 1991; 5: 232, Jacobs et al. Am J Vet Res 1985; 46:1705							

## Cardiac Presentation

The echocardiogram in this patient demonstrated normal **left atrial** size based on 3 separate LA measurements. The cranial and caudal **mitral** valve leaflets presented normal linear structure and kinetics. The **left ventricle** presented normal thicknesses with linear contour and was not dilated nor restricted. The **myocardium** presented normal echogenicity without subjective evidence of significant fibrotic or ischemic disease. **Contractility** of the ventricular walls was adequate and in normal range for this patient evidenced by the fractional shortening measurement and subjective evaluation of the different regions and angles of the myocardium. The **left ventricular outflow** tract demonstrated normal laminar flow and subjective structural integrity. The **right atrium** and auricle revealed normal size, structure and content. No evidence of masses was noted or chamber overload. **Tricuspid** valvular assessment demonstrated adequate linear morphology and kinetics. The **right ventricle** was of normal size (1/3 diameter of LV), chordae structure, myocardial echogenicity and thickness. **Pulmonic** tract assessment revealed normal valve structure, laminar flow, and diameter (approx. 1:1 pa/ao ratio). No visible **pericardial** or free pleura fluid was noted or extra cardiac pathology in the visible planes. The cranial **mediastinum** and **pericardial** regions were free of masses in the visible window.

## Urinary System

The **urinary bladder**, trigone, and pelvic urethra presented normal thicknesses and normal tone. The ureters were not visible which is normal. No uroliths or sediment were visualized and anechoic urine was present. No evidence of inflammatory or neoplastic changes were noted. Ureteral papillae were normal.



## PATIENT

Pumpkin Thomas

## SPECIES

Feline

## BREED

Maine Coon x

## SEX

Neutered Male

## AGE

15

## WEIGHT

6.8

## INTERPRETED BY

Eric Lindquist, DMV,  
DABVP (CFM), Cert.  
IVUSS

## IMAGING PERFORMED BY

Jenn

## HOSPITAL NAME

Rockaway Animal  
Hospital

## REFERRING VET

Dr. Kahn

## INVOICE

72904

## DATE

1/2/26

The **kidneys** presented a relatively uniform cortical hyperechogenicity when compared to the renal medulla, spleen and liver. No overt masses were noted. Corticomedullary definition was nebulous and the ratio favored the cortex slightly. The ureters were not visible and assumed to be normal. These changes are most consistent with chronic interstitial nephritis yet infiltrative disease could not be entirely ruled out without biopsy though neoplasia is not suspected. The kidneys were subjectively near end stage. Blood flow to both kidneys was subnormal. Left kidney measured 3.6 cm with slight pyelectasia noted. Right kidney measured 3.5 cm.

### **Adrenal Glands**

The regions of the **adrenal glands** were unremarkable.

### **Spleen**

The **spleen** presented a smooth homogeneous parenchyma hyperechoic to liver and renal cortical parenchyma. The capsule was smooth without noticeable expansion or deviation from within the spleen or adjacent pathology. The splenic vasculature demonstrated normal volume without signs of congestion or thrombosis. No sonographic evidence of acute or chronic inflammatory, neoplastic, or infarctual changes were noted.

### **Liver**

The **liver** images from right and left intercostal as well as subcostal views revealed subjectively normal liver size, contour, and structure. Some age-related parenchymal remodeling was noted but likely not clinically significant at this time. Vascular and biliary tracts were of normal volume and no evidence of congestion was noted. The gallbladder presented some dependent debris with essentially normal contour. The cystic and common bile ducts were normal. No overt evidence of active inflammatory, infiltrative or regenerative pathology was noted but should be paired with current or past LE elevations regarding any clinical significance to this presentation. The hepatic lymph nodes were unremarkable.

### **Gastrointestinal**

Examination of the **gastrointestinal tract** revealed a stomach and intestine free of stasis, of normal wall thickness, acceptable curvilinear mural detail, and peristaltic activity. Small and large intestine demonstrated normal luminal chyme and stool consistency respectively. No obstructive or overt infiltrative disease was noted. No associated abnormal lymphatic activity was noted.

### **Pancreas**

The base and limbs of the **pancreas** were observed to be largely isoechoic to surrounding omental fat. Some parenchymal remodeling, however, with mild deviation from curvilinear normalcy was observed. Pancreatic duct and capsular irregularities were present consistent with age related changes. If pain upon imaging (+ Murphy sign) was present or if the patient is focally painful in subxyphoid palpation then low-grade smoldering chronic pancreatitis should be suspected.

## ULTRASONOGRAPHIC FINDINGS

- Subjectively near end stage degenerative renal disease.
- Age related hepatic and pancreatic changes.
- Structurally normal heart. Likely flow murmur.



## PATIENT

Pumpkin Thomas

## SPECIES

Feline

## BREED

Maine Coon x

## SEX

Neutered Male

## AGE

15

## WEIGHT

6.8

## INTERPRETED BY

Eric Lindquist, DMV,  
DABVP (CFM), Cert.  
IVUSS

## IMAGING PERFORMED BY

Jenn

## HOSPITAL NAME

Rockaway Animal  
Hospital

## REFERRING VET

Dr. Kahn

## INVOICE

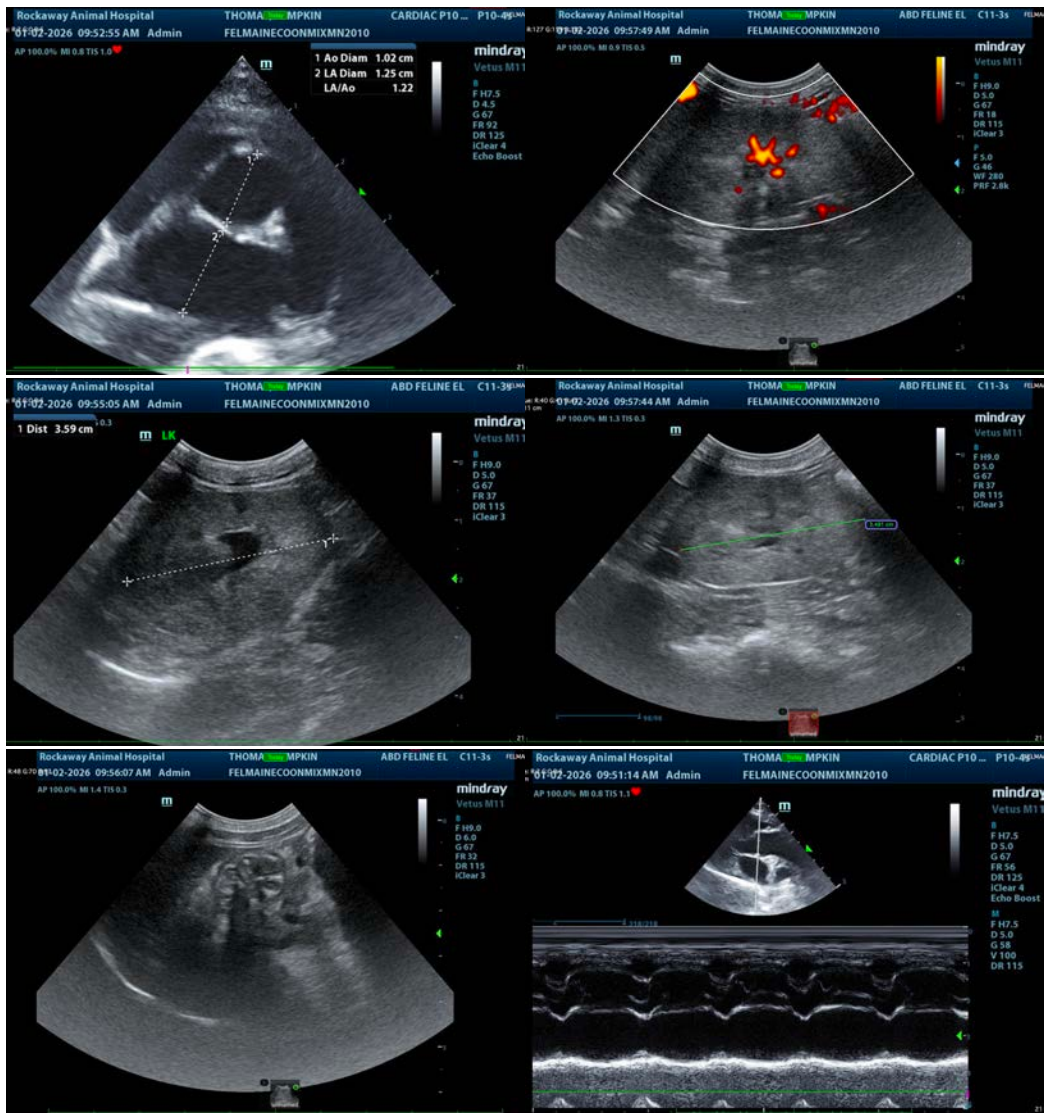
72904

## DATE

1/2/26

## INTERPRETATION OF THE FINDINGS & FURTHER RECOMMENDATIONS

I'm most concerned about long-term viability of the kidneys in this patient. 48-72 hour IV fluid protocol to correct azotemia and full urinary workup indicated. Prognosis long-term is guarded. Serial blood pressures also indicated. Owing to the azotemia, there is some anesthetic risk in this patient.





## PATIENT

Pumpkin Thomas

## SPECIES

Feline

## BREED

Maine Coon x

## SEX

Neutered Male

## AGE

15

## WEIGHT

6.8

## INTERPRETED BY

Eric Lindquist, DMV,  
DABVP (CFM), Cert.  
IVUSS

## IMAGING PERFORMED BY

Jenn

## HOSPITAL NAME

Rockaway Animal  
Hospital

## REFERRING VET

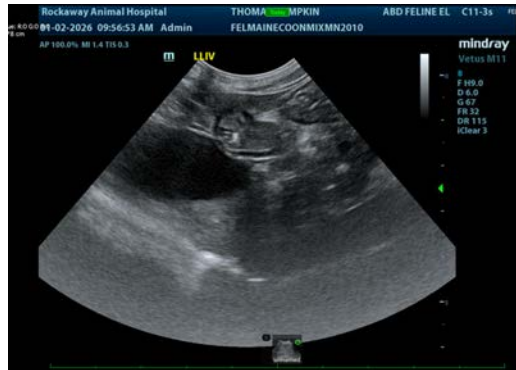
Dr. Kahn

## INVOICE

72904

## DATE

1/2/26



The information and recommendations provided are based on the images presented by the referring veterinarian/sonographer. No evaluation can be communicated regarding pathology that was not visible in the image/video clips provided.

Thank you for this referral. If the clinical or image interpretation does not parallel your findings or if I can be of any further assistance please contact me.

Eric Lindquist, DMV, DABVP(CFM), Cert. IVUSS,  
CEO, Owner, Founder -- SonoPath.com  
[info@SonoPath.com](mailto:info@SonoPath.com)