

PATIENT

Ellie Denton

SPECIES

Canine

BREED

Dachshund

SEX

Spayed Female

AGE

14 Years 4 Months

WEIGHT

11.6 lbs

INTERPRETED BY

Eric Lindquist, DMV,
DABVP (CFM), Cert.
IVUSS

IMAGING PERFORMED BY

Brittney Beigel, DVM

HOSPITAL NAME

Bayside Animal
Medical Center

REFERRING VET

Brittney Beigel, DVM

INVOICE

72956

DATE

1/2/25

PRESENTING CLINICAL SIGNS

Lethargic, fever, hyporexic, ataxic in rear end w/ delayed CP RR; BW demonstrates marked neutrophilia, mild azotemia; O opts to US to screen for abnormal abdominal pathology; P was fasted for US scan, no sedation needed

Abnormal PE/Chem/CBC/UA Results: Attached

ULTRASONOGRAPHIC EXAMINATION OF THE ABDOMEN

Urinary System

The **urinary bladder** revealed a polyp measuring 0.71 cm x 0.60 cm in the area of the ureteral papilla. This may represent simple polypoid hyperplasia and should be monitored.. The cystourethral junction was unremarkable.

The **kidneys** revealed largely normal size and structure, corticomedullary definition and ratio (cortex 1/3 of medulla) were essentially maintained with some age-related loss of curvilinear patterns regarding the capsule and C/M junction. The cortices presented largely uniform texture with some increased echogenicity expected for his age patient. Medullary structure differed distinctly from that of the cortex. The left kidney measured 3.34 cm with slight pyelectasia of 0.30 cm. Right kidney measured 4.2 cm.

Adrenal Glands

Both **adrenal glands** were visualized and recognized as having normal shape, size, position and echogenicity for this breed. The phrenic vasculature, glandular echogenicity and detail were unremarkable. Capsule, cortex, and medullary definition were normal for this age patient. Left measured 0.74 cm at the caudal pole and 0.76 cm at the cranial pole. Right measured 0.62 cm at the cranial pole and 0.55 cm at the caudal pole.

Spleen


The **spleen** presented a smooth homogeneous parenchyma hyperechoic to liver and renal cortical parenchyma. The capsule was smooth without noticeable expansion or deviation from within the spleen or adjacent pathology. The splenic vasculature demonstrated normal volume without signs of congestion or thrombosis. No sonographic evidence of acute or chronic inflammatory, neoplastic, or infarctual changes were noted.

Liver

The **liver** images submitted revealed subjectively normal liver size, contour, and structure. Parenchymal echogenicity was naturally coarse and hypoechoic to the spleen. Vascular and biliary tracts were of normal volume with no evidence of congestion. The gallbladder presented acceptably thin walls with primarily anechoic content. The cystic and common bile ducts were normal. No pathological hepatic lymphadenopathy was evident. No overt structural evidence of inflammatory, infiltrative or regenerative pathology was evident.

Gastrointestinal

Examination of the **gastrointestinal tract** revealed a stomach and intestine free of stasis, of normal wall thickness, acceptable curvilinear mural detail, and peristaltic activity. Small and large intestine



PATIENT

Ellie Denton

SPECIES

Canine

BREED

Dachshund

SEX

Spayed Female

AGE

14 Years 4 Months

WEIGHT

11.6 lbs

INTERPRETED BY

Eric Lindquist, DMV,
DABVP (CFM), Cert.
IVUSS

IMAGING PERFORMED BY

Brittney Beigel, DVM

HOSPITAL NAME

Bayside Animal
Medical Center

REFERRING VET

Brittney Beigel, DVM

INVOICE

72956

DATE

1/2/25

demonstrated normal luminal chyme and stool consistency respectively. No obstructive or overt infiltrative disease was noted. No associated abnormal lymphatic activity was noted.

Pancreas

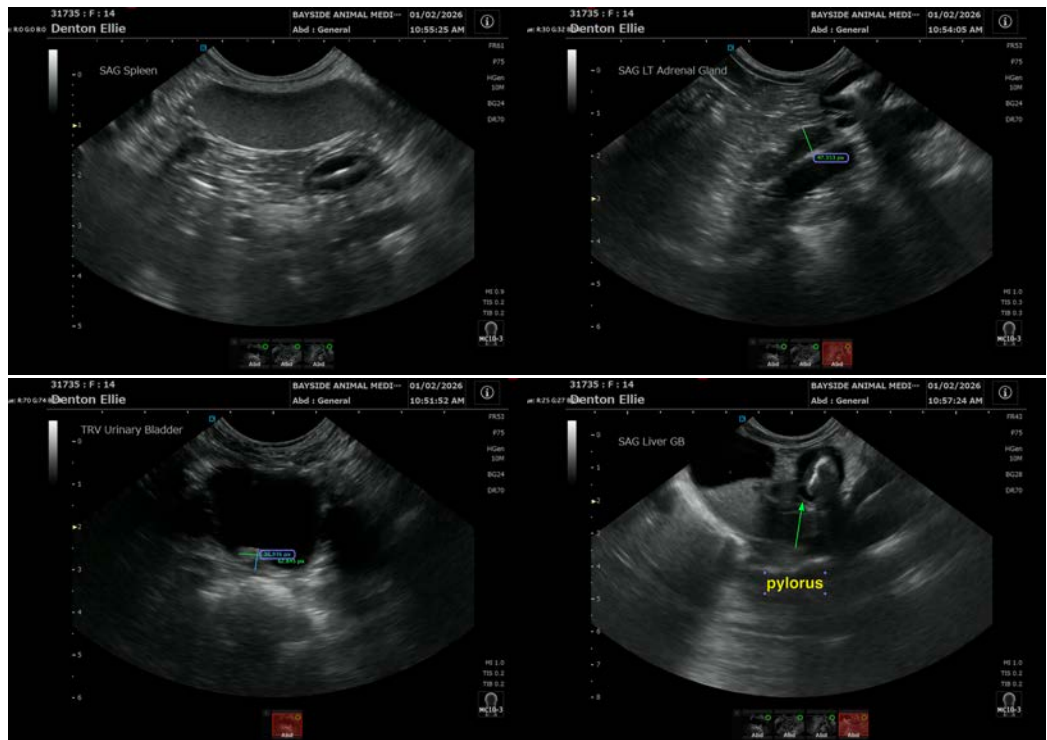
Diffuse hyperechoic changes were present in the area of the **pancreas**. The pancreatic remodeling was evident with multifocal to diffuse hyperechoic changes. These changes are consistent with fibrosis, amyloid, saponification of fat and may contain areas of low-grade chronic active inflammation especially if pain on imaging (+ Murphy sign) was present +/- focal subxyphoid palpation reveals pain response. No overt masses were noted.

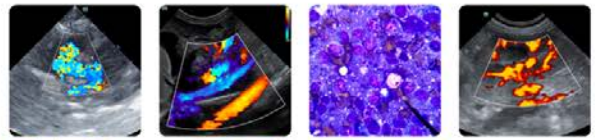
ULTRASONOGRAPHIC FINDINGS

- History of pancreatitis likely yet no evidence of active inflammation.
- Urinary bladder polyp.
- Age related renal changes.

INTERPRETATION OF THE FINDINGS & FURTHER RECOMMENDATIONS

Structurally unremarkable abdomen. No overt GI ulcerative disease noted. However, I cannot rule out GI blood loss as a potential cause of the clinical signs. Empirical GI protectant protocol could be considered. Creatinine/BUN elevation may be owing to periodic passage of calculi yet the kidneys do not appear end stage. Full urinary workup indicated. 72-hour IV fluid protocol, GI protectants indicated. Anemia may be owing to renal failure. However, again the kidneys do not appear end stage. Recent passage of calculi/obstructive episode may have occurred.





PATIENT

Ellie Denton

SPECIES

Canine

BREED

Dachshund

SEX

Spayed Female

AGE

14 Years 4 Months

WEIGHT

11.6 lbs

INTERPRETED BY

Eric Lindquist, DMV,
DABVP (CFM), Cert.
IVUSS

IMAGING PERFORMED BY

Brittney Beigel, DVM

HOSPITAL NAME

Bayside Animal
Medical Center

REFERRING VET

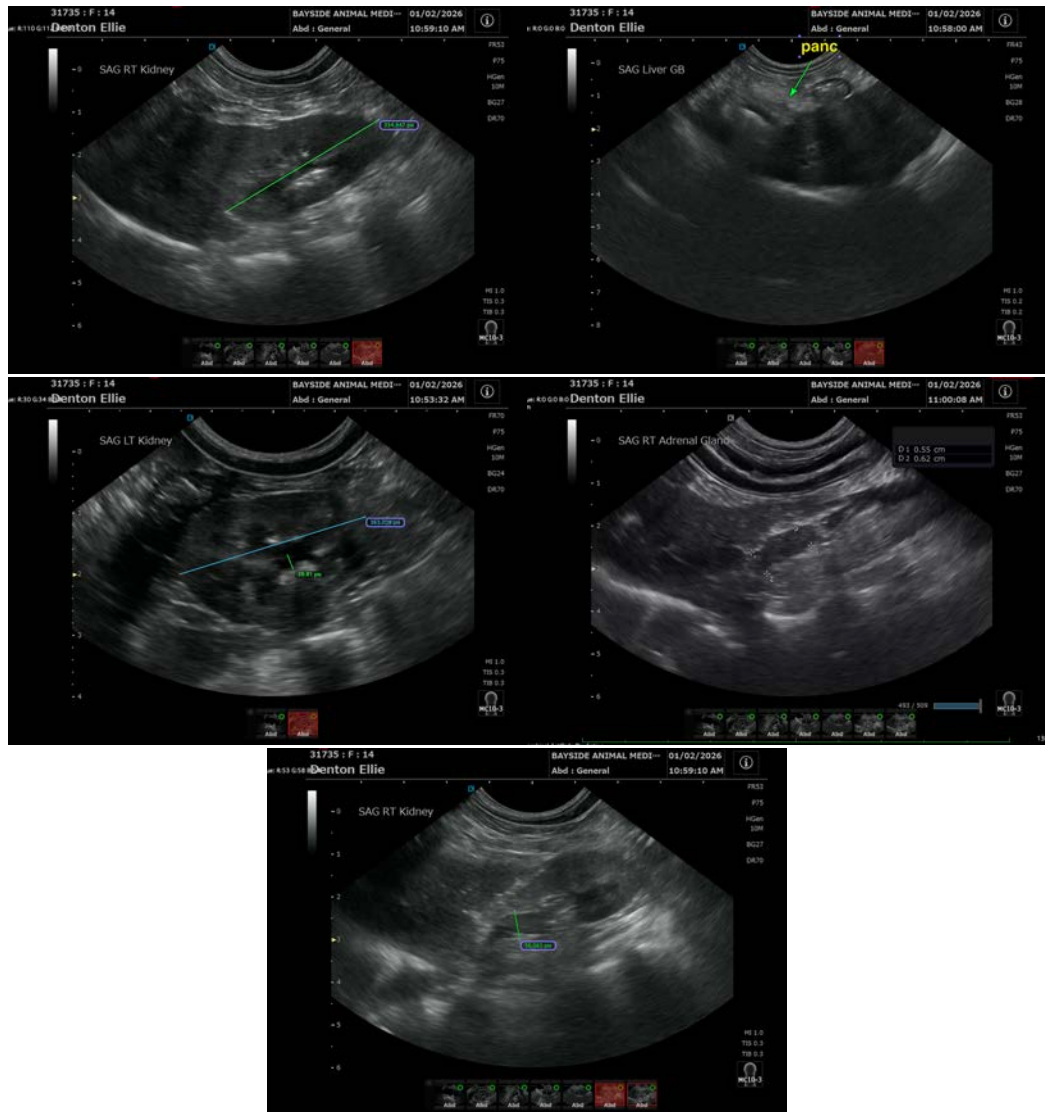
Brittney Beigel, DVM

INVOICE

72956

DATE

1/2/25



The information and recommendations provided are based on the images presented by the referring veterinarian/sonographer. No evaluation can be communicated regarding pathology that was not visible in the image/video clips provided.

Thank you for this referral. If the clinical or image interpretation does not parallel your findings or if I can be of any further assistance please contact me.

Eric Lindquist, DMV, DABVP(CFM), Cert. IVUSS,
CEO, Owner, Founder -- SonoPath.com
info@SonoPath.com