



PATIENT

Tigger Shepardson

SPECIES

Feline

BREED

Domestic Shorthair

SEX

Male

AGE

14 years

WEIGHT

11.5 lbs

INTERPRETED BY

Eric Lindquist, DMV
DABVP, Cert. IVUSS

IMAGING PERFORMED BY

Dr. Levy

HOSPITAL NAME

Court Street VH

REFERRING VET

Dr. Miller

INVOICE

70287

DATE

1/19/26

PRESENTING CLINICAL SIGNS

Severe gastroenteropathy (chronic vomiting & chronic diarrhea)- not responsive to metro, has now been on hydrolyzed protein diet for the past 8w. Hyperthyroidism

ULTRASONOGRAPHIC EXAMINATION OF THE ABDOMEN

Urinary System

The **urinary bladder**, trigone, and pelvic urethra presented normal thicknesses and normal tone. The ureters were not visible which is normal. No uroliths or sediment were visualized and anechoic urine was present. No evidence of inflammatory or neoplastic changes was noted. Ureteral papillae were normal.

The **kidneys** revealed normal size and structure, corticomedullary definition and ratio for this age. The cortices presented largely uniform texture with normal echogenic relationship to liver and spleen. Medullary structure differed distinctly from the cortex and no evidence of pelvic dilation was present. The capsules were acceptably uniform without significant irregularities. The left kidney measured 4.0 cm. The right kidney measured 4.0 cm.

Adrenal Glands

The **adrenal glands** were not overtly visualized. However, the regions of the adrenal glands appeared unremarkable.

Spleen

The **spleen** was enlarged and measured 1.3 cm with uniform parenchyma.

Liver

The **liver** images submitted revealed subjectively normal liver size, contour, and structure. Parenchymal echogenicity was naturally coarse and hypoechoic to the spleen. Vascular and biliary tracts were of normal volume with no evidence of congestion. The gallbladder presented acceptably thin walls with primarily anechoic content. The cystic and common bile ducts were normal. No pathological hepatic lymphadenopathy was evident. No overt structural evidence of inflammatory, infiltrative or regenerative pathology was evident.

Gastrointestinal

Examination of the **gastrointestinal tract** revealed a stomach and intestine free of stasis, of normal wall thickness, acceptable curvilinear mural detail, and peristaltic activity. Small and large intestine



PATIENT

Tigger Shepardson

SPECIES

Feline

BREED

Domestic Shorthair

SEX

Male

AGE

14 years

WEIGHT

11.5 lbs

INTERPRETED BY

Eric Lindquist, DMV
DABVP, Cert. IVUSS

IMAGING PERFORMED BY

Dr. Levy

HOSPITAL NAME

Court Street VH

REFERRING VET

Dr. Miller

INVOICE

70287

DATE

1/19/26

demonstrated normal luminal chyme and stool consistency respectively. No obstructive or overt infiltrative disease was noted. No associated abnormal lymphatic activity was noted.

Pancreas

The base and limbs of the **pancreas** were observed to be largely isoechoic to surrounding omental fat. Pancreatic duct and capsular contour were acceptably normal and parenchyma respected normal curvilinear patterns. No overt evidence of active inflammatory or neoplastic disease was noted.

ULTRASONOGRAPHIC FINDINGS

Splenomegaly.

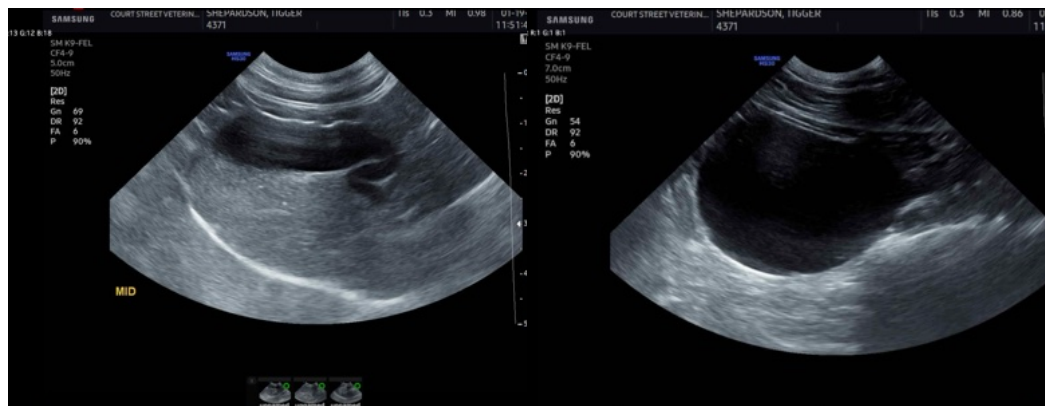
Age related renal changes.

INTERPRETATION OF THE FINDINGS & FURTHER RECOMMENDATIONS

FNA of the spleen is indicated to ensure occult disease is not present such as round cell neoplasia versus reactive spleen and splenitis. There was no evidence of structural disease. 25-gauge FNA of the spleen is indicated.

Internal medicine consult can be utilized through SonoPath.com. You can select the internal medicine drop down at <http://spa.sonopath.com/>.

One of the world's top internists & SonoPath associate Dr. Remo Lobetti BVSc, MMedVet, PhD, DECVIM can evaluate your case through SonoPath. <https://sonopath.com/resources/sonopath-services/internal-medicine-teleconsultation-services>





PATIENT

Tigger Shepardson

SPECIES

Feline

BREED

Domestic Shorthair

SEX

Male

AGE

14 years

WEIGHT

11.5 lbs

INTERPRETED BY

Eric Lindquist, DMV
DABVP, Cert. IVUSS

IMAGING PERFORMED BY

Dr. Levy

HOSPITAL NAME

Court Street VH

REFERRING VET

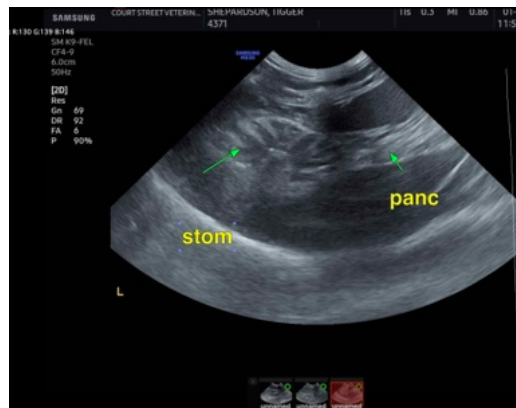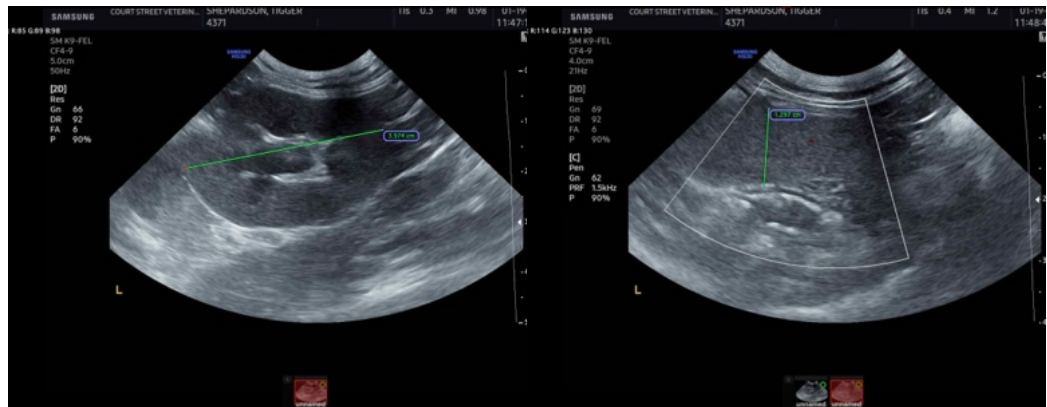
Dr. Miller

INVOICE

70287

DATE

1/19/26



The information and recommendations provided are based on the images presented by the referring veterinarian/sonographer. No evaluation can be communicated regarding pathology that was not visible in the image/video clips provided.

Thank you for this referral. If the clinical or image interpretation does not parallel your findings or if I can be of any further assistance please contact me.

Eric Lindquist, DMV, DABVP (CFM), Cert. IVUSS, CEO of SonoPath.com

info@SonoPath.com