



PATIENT

Sadie Davis

SPECIES

Canine

BREED

Mix

SEX

Intact female

AGE

9 months

WEIGHT

64 lbs

INTERPRETED BY

Eric Lindquist, DMV
DABVP, Cert. IVUSS

IMAGING PERFORMED BY

Gudrun Gunther

HOSPITAL NAME

New Frontier Animal
Medical Center

REFERRING VET

Dr. Gunther

INVOICE

70273

DATE

1/19/26

PRESENTING CLINICAL SIGNS

- Chronic hyporexia and diarrhea since adoption 2 mo ago. Recently started vomiting.
- 2 lb weight loss over last several weeks
- Litter made had parvo but this patient tested negative for Parvo CBC/CHEM - WNL Fecal - no parasites

ULTRASONOGRAPHIC EXAMINATION OF THE ABDOMEN

Urinary System

The **urinary bladder**, trigone, and pelvic urethra presented normal thicknesses and normal tone. The ureters were not visible which is normal. No uroliths or sediment were visualized and anechoic urine was present. No evidence of inflammatory or neoplastic changes was noted. Ureteral papillae were normal.

The **kidneys** revealed normal size and structure, corticomedullary definition and ratio for this age. The cortices presented largely uniform texture with normal echogenic relationship to liver and spleen. Medullary structure differed distinctly from the cortex and no evidence of pelvic dilation was present. The capsules were acceptably uniform without significant irregularities. The right kidney measured 6.74 cm. The left kidney measured 6.3 cm.

Adrenal Glands

Both **adrenal glands** were visualized and recognized as having normal shape, size, position and echogenicity for this breed. The phrenic vasculature, glandular echogenicity and detail were unremarkable. Capsule, cortex, and medullary definition were normal for this age patient. The left adrenal gland measured 3.35 x 0.32 cm at the cranial pole and 0.4 cm at the caudal pole. The right adrenal gland measured 1.7 x 1.37 cm at the cranial pole and 0.5 cm at the caudal pole.

Spleen

The **spleen** presented a smooth homogeneous parenchyma hyperechoic to liver and renal cortical parenchyma. The capsule was smooth without noticeable expansion or deviation from within the spleen or adjacent pathology. The splenic vasculature demonstrated normal volume without signs of congestion or thrombosis. No sonographic evidence of acute or chronic inflammatory, neoplastic, or infarctual changes was noted.

Liver

The **liver** images submitted revealed subjectively normal liver size, contour, and structure. Parenchymal echogenicity was naturally coarse and hypoechoic to the spleen. Vascular and biliary tracts were of normal volume with no evidence of congestion. The gallbladder presented acceptably thin walls with



PATIENT

Sadie Davis

primarily anechoic content. The cystic and common bile ducts were normal. No pathological hepatic lymphadenopathy was evident. No overt structural evidence of inflammatory, infiltrative or regenerative pathology was evident.

SPECIES

Canine

Gastrointestinal

BREED

Mix

Examination of the **gastrointestinal tract** revealed a stomach and intestine free of stasis, of normal wall thickness, acceptable curvilinear mural detail, and peristaltic activity. Small and large intestine demonstrated normal luminal chyme and stool consistency respectively. No obstructive or overt infiltrative disease was noted. No associated abnormal lymphatic activity was noted.

SEX

Intact female

Pancreas

AGE

9 months

The base and limbs of the **pancreas** were observed to be largely isoechoic to surrounding omental fat. Pancreatic duct and capsular contour were acceptably normal and parenchyma respected normal curvilinear patterns. No overt evidence of active inflammatory or neoplastic disease was noted.

WEIGHT

64 lbs

ULTRASONOGRAPHIC FINDINGS

INTERPRETED BY

Eric Lindquist, DMV
DABVP, Cert. IVUSS

Structurally unremarkable abdomen.

INTERPRETATION OF THE FINDINGS & FURTHER RECOMMENDATIONS

IMAGING PERFORMED BY

Gudrun Gunther

There was no evidence of pathology.

HOSPITAL NAME

New Frontier Animal
Medical Center

Differentials for diarrhea include occult parasitism. Dietary indiscretion, dietary intolerance, antibiotic responsive colitis, intestinal dysbiosis and occult Addison's should all be considered as causes of diarrhea in this patient. A hydrolyzed diet trial may be in this patient's best interest +/- probiotics. 24-hour NPO and reintroduction of bland diet indicated. I recommend a baseline cortisol or ACTH stimulation test, a fresh fecal smear and fecal floatation analysis if not already performed

REFERRING VET

Dr. Gunther

INVOICE

70273

DATE

1/19/26



PATIENT

Sadie Davis

SPECIES

Canine

BREED

Mix

SEX

Intact female

AGE

9 months

WEIGHT

64 lbs

INTERPRETED BY

Eric Lindquist, DMV
DABVP, Cert. IVUSS

IMAGING PERFORMED BY

Gudrun Gunther

HOSPITAL NAME

New Frontier Animal Medical Center

REFERRING VET

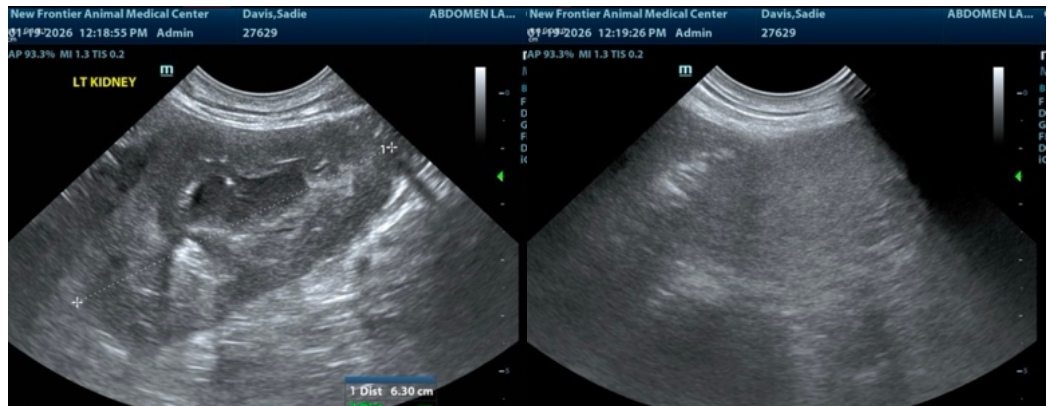
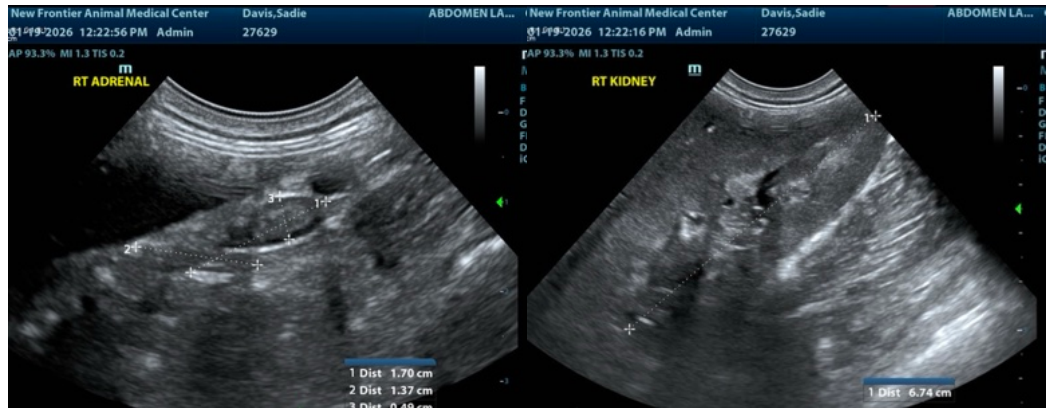
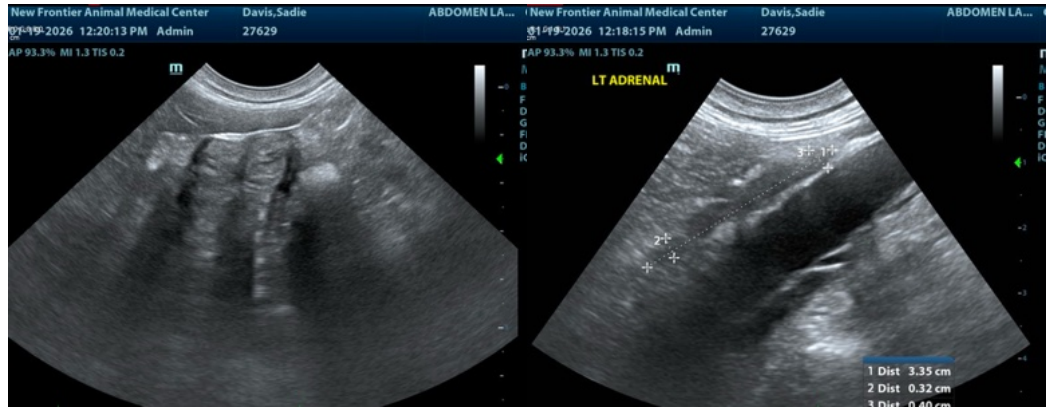
Dr. Gunther

INVOICE

70273

DATE

1/19/26





PATIENT

Sadie Davis

SPECIES

Canine

BREED

Mix

SEX

Intact female

AGE

9 months

WEIGHT

64 lbs

INTERPRETED BY

Eric Lindquist, DMV
DABVP, Cert. IVUSS

IMAGING PERFORMED BY

Gudrun Gunther

HOSPITAL NAME

New Frontier Animal
Medical Center

REFERRING VET

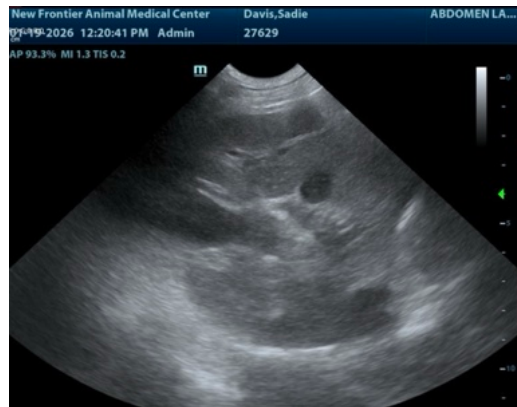Dr. Gunther

INVOICE

70273

DATE

1/19/26



The information and recommendations provided are based on the images presented by the referring veterinarian/sonographer. No evaluation can be communicated regarding pathology that was not visible in the image/video clips provided.

Thank you for this referral. If the clinical or image interpretation does not parallel your findings or if I can be of any further assistance please contact me.

Eric Lindquist, DMV, DABVP (CFM), Cert. IVUSS, CEO of SonoPath.com

info@SonoPath.com