



**PATIENT**

Lexi Macaluso

**SPECIES**

Canine

**BREED**

Chihuahua Mix

**SEX**

Spayed female

**AGE**

7 years

**WEIGHT**

13.6 lbs

**INTERPRETED BY**

Eric Lindquist, DMV  
DABVP, Cert. IVUSS

**PRESENTING CLINICAL SIGNS**

- Recheck echo

**ULTRASONOGRAPHIC EXAMINATION OF THE HEART**

The echocardiogram in this patient demonstrated no evidence of volume overload or pressure overload. Mitral insufficiency as persistently present. Contractility was adequate. There was no pericardial or pleural effusion noted.

CANINE CARDIAC PARAMETERS	MR VMAX (m/s)	TR VMAX (m/s)	LA/AO	LA/AO (Heart Base)	FS (%)	EF (%)	EPSS (cm)
NORMAL PARAMETER	4.5-5.5	<2.7	1.3	<1.6	28-40	40-100	<0.6
PATIENT	5.0	None	1.3	1.6	50	80	0.1
CANINE CARDIAC PARAMETERS	HR (BPM)	AV VMAX (m/s)	PV MAX (m/s)	BODY WEIGHT	LA 2D short axis Base view (cm)	LVIDd Avg; 2D and m-mode short axis (cm)	LVIDs Avg; 2D and m-mode short axis (cm)
NORMAL PARAMETER	50-100	0.7-1.7	0.7-1.6	BELOW	BELOW	BELOW	BELOW
PATIENT	70	None	None	13.6 lbs	2.5	2.2	

**IMAGING PERFORMED BY**

Dr. Cerf

**HOSPITAL NAME**

VC Hardyston

**REFERRING VET**

Dr. Streigel

**INVOICE**

70283

**DATE**

1/19/26

**ULTRASONOGRAPHIC FINDINGS**

Compensated mitral insufficiency, stable Stage B1 valvular disease.

**INTERPRETATION OF THE FINDINGS & FURTHER RECOMMENDATIONS**

The heart is stable without clinical disease. No overt contraindication for anesthesia of brief to moderate duration. I suggest Torbutrol premed, Propofol induction, Isoflo maintenance or similar protocol if anesthesia is desired. Blood pressure recommended if not already performed and target white coat negative systolic pressure of < 160 mmHg. If higher than this ACE-inhibitor is suggested to reach this level. Recheck echocardiogram is recommended in 6 months, earlier if murmur grade increases or clinical signs initiate.



## PATIENT

Lexi Macaluso

## SPECIES

Canine

## BREED

Chihuahua Mix

## SEX

Spayed female

## AGE

7 years

## WEIGHT

13.6 lbs

## INTERPRETED BY

Eric Lindquist, DMV  
DABVP, Cert. IVUSS

## IMAGING PERFORMED BY

Dr. Cerf

## HOSPITAL NAME

VC Hardyston

## REFERRING VET

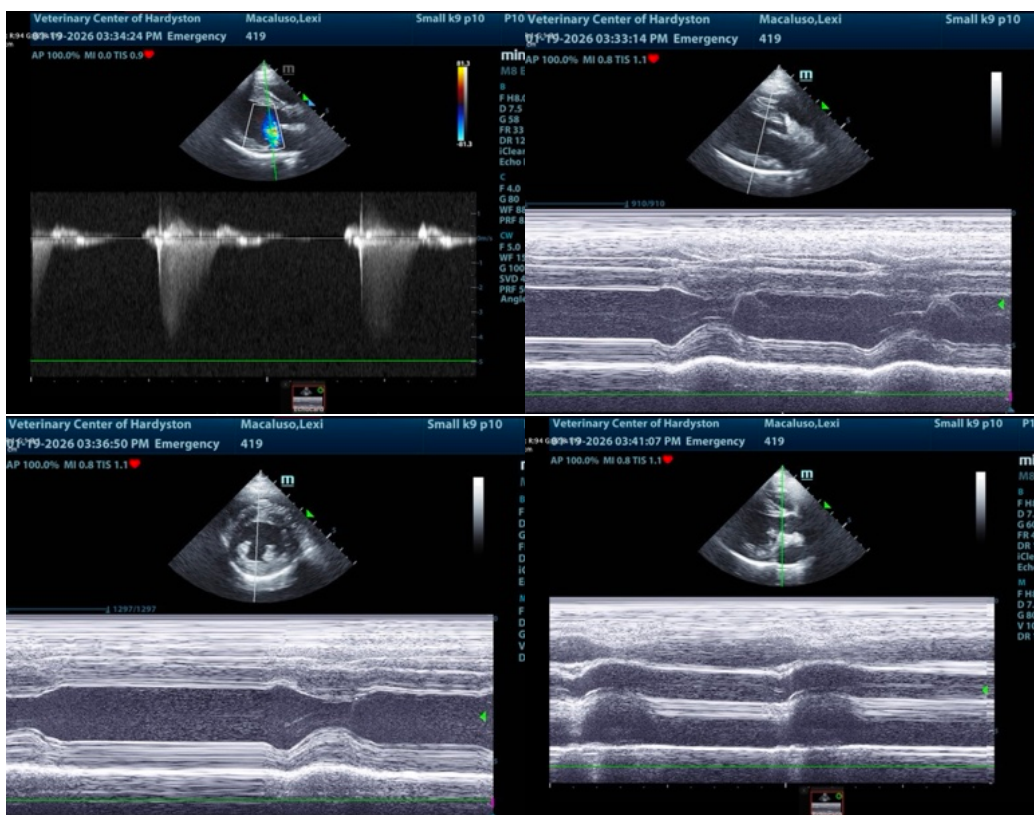
Dr. Streigel

## INVOICE

70283

## DATE

1/19/26



The information and recommendations provided are based on the images presented by the referring veterinarian/sonographer. No evaluation can be communicated regarding pathology that was not visible in the image/video clips provided.

Thank you for this referral. If the clinical or image interpretation does not parallel your findings or if I can be of any further assistance please contact me.

Eric Lindquist, DMV, DABVP (CFM), Cert. IVUSS, CEO of SonoPath.com

[info@SonoPath.com](mailto:info@SonoPath.com)