



## PATIENT

Caiden Robson

## SPECIES

Canine

## BREED

Golden Retriever

## SEX

Neutered male

## AGE

14 years

## WEIGHT

88.4 lbs

## INTERPRETED BY

Eric Lindquist, DMV  
DABVP, Cert. IVUSS

## IMAGING PERFORMED BY

Dr. Megan Bray

## HOSPITAL NAME

Taylorsville VC

## REFERRING VET

Dr. Bray

## INVOICE

70253

## DATE

1/19/26

## PRESENTING CLINICAL SIGNS

- Patient presented on 1/2/26 for cutaneous, mildly erythematous, slightly ulcerated, pruritic, moist mass (1.5 cm x 2 cm), freely movable, nonpainful on right ventrolateral abdomen. FNA reveals pyogranulomatous inflammation with population of relatively uniform suspected round cells. Patient presented today for mass growing in size, FNA of mass today revealed MCT.
- Staging for mast cell tumor, has history of a lipoma and hemangioma that have been removed.

## ULTRASONOGRAPHIC EXAMINATION OF THE ABDOMEN

### Urinary System

The **urinary bladder**, trigone, and pelvic urethra presented normal thicknesses and normal tone. The pelvic urethra was imaged 2.0 cm beyond the cystourethral junction and appeared normal. The ureters were not visible which is normal. No uroliths or sediment were visualized and anechoic urine was present. No evidence of inflammatory or neoplastic changes was noted. Ureteral papillae were normal.

The **kidneys** revealed largely normal size and structure, corticomedullary definition and ratio (cortex 1/3 of medulla) were essentially maintained with some age-related loss of curvilinear patterns regarding the capsule and C/M junction. The cortices presented largely uniform texture with some increased echogenicity expected for this age patient. Medullary structure differed distinctly from that of the cortex and no evidence of pelvic dilation was present. Slight mineralization was noted. The left kidney measured 6.5 cm. The right kidney measured 7.9 cm.

### Adrenal Glands

Both **adrenal glands** were visualized and recognized as having normal shape, size, position and echogenicity for this breed. The phrenic vasculature, glandular echogenicity and detail were unremarkable. Capsule, cortex, and medullary definition were normal for this age patient. The left adrenal gland measured 0.8 cm. The right adrenal gland measured 0.84 cm at the cranial pole and 0.56 cm at the caudal pole.

### Spleen

The **spleen** presented a smooth homogeneous parenchyma hyperechoic to liver and renal cortical parenchyma. The capsule was smooth without noticeable expansion or deviation from within the spleen or adjacent pathology. The splenic vasculature demonstrated normal volume without signs of congestion or thrombosis. No sonographic evidence of acute or chronic inflammatory, neoplastic, or infarctual changes was noted.

### Liver

The **liver** images from right and left intercostal as well as subcostal views revealed subjectively normal liver size, contour, and structure. Some age-related parenchymal remodeling was noted but likely not



## PATIENT

Caiden Robson

## SPECIES

Canine

## BREED

Golden Retriever

## SEX

Neutered male

## AGE

14 years

## WEIGHT

88.4 lbs

## INTERPRETED BY

Eric Lindquist, DMV  
DABVP, Cert. IVUSS

## IMAGING PERFORMED BY

Dr. Megan Bray

## HOSPITAL NAME

Taylorville VC

## REFERRING VET

Dr. Bray

## INVOICE

70253

## DATE

1/19/26

clinically significant at this time. Vascular and biliary tracts were of normal volume and no evidence of congestion was noted. The gallbladder presented some dependent debris with essentially normal contour. The cystic and common bile ducts were normal. No overt evidence of active inflammatory, infiltrative or regenerative pathology was noted but should be paired with current or past LE elevations regarding any clinical significance to this presentation. The hepatic lymph nodes were unremarkable.

## Gastrointestinal

Examination of the **gastrointestinal tract** revealed a stomach and intestine free of stasis, of normal wall thickness, acceptable curvilinear mural detail, and peristaltic activity. Small and large intestine demonstrated normal luminal chyme and stool consistency respectively. No obstructive or overt infiltrative disease was noted. No associated abnormal lymphatic activity was noted.

## Pancreas

The base and limbs of the **pancreas** were observed to be largely isoechoic to surrounding omental fat. Pancreatic duct and capsular contour were acceptably normal and parenchyma respected normal curvilinear patterns. No overt evidence of active inflammatory or neoplastic disease was noted.

## ULTRASONOGRAPHIC FINDINGS

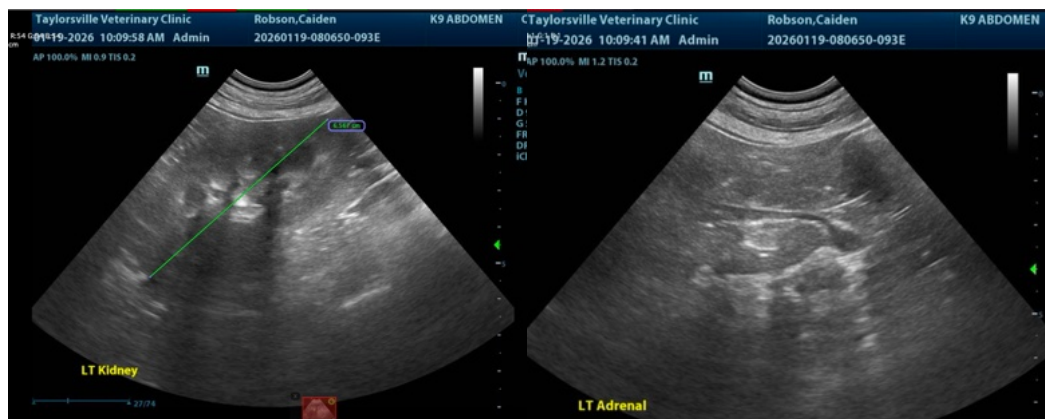Structurally unremarkable abdomen.

Minor renal mineralization.

Age related abdominal changes.

## INTERPRETATION OF THE FINDINGS & FURTHER RECOMMENDATIONS

There was no evidence of mast cell disease or clinically significant primary disease.





**PATIENT**

Caiden Robson

**SPECIES**

Canine

**BREED**

Golden Retriever

**SEX**

Neutered male

**AGE**

14 years

**WEIGHT**

88.4 lbs

**INTERPRETED BY**

Eric Lindquist, DMV  
DABVP, Cert. IVUSS

**IMAGING  
PERFORMED BY**

Dr. Megan Bray

**HOSPITAL NAME**

Taylorville VC

**REFERRING VET**

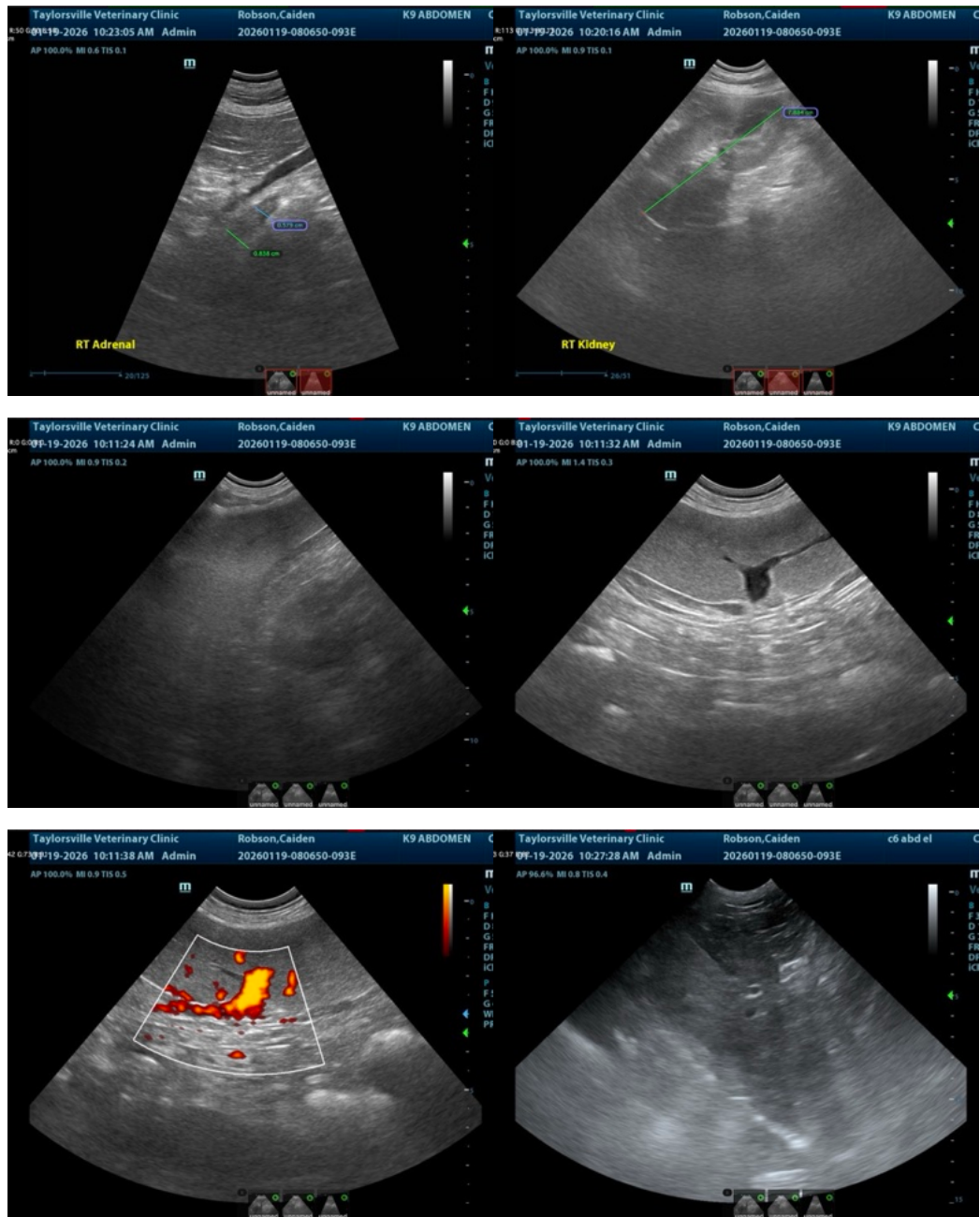
Dr. Bray

**INVOICE**

70253

**DATE**

1/19/26





## PATIENT

Caiden Robson

## SPECIES

Canine

## BREED

Golden Retriever

## SEX

Neutered male

## AGE

14 years

## WEIGHT

88.4 lbs

## INTERPRETED BY

Eric Lindquist, DMV  
DABVP, Cert. IVUSS

## IMAGING PERFORMED BY

Dr. Megan Bray

## HOSPITAL NAME

Taylorsville VC

## REFERRING VET

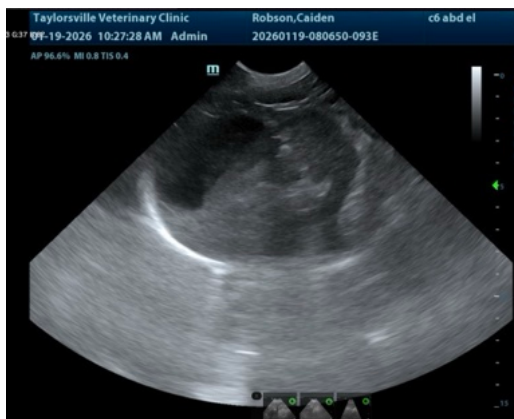Dr. Bray

## INVOICE

70253

## DATE

1/19/26



The information and recommendations provided are based on the images presented by the referring veterinarian/sonographer. No evaluation can be communicated regarding pathology that was not visible in the image/video clips provided.

Thank you for this referral. If the clinical or image interpretation does not parallel your findings or if I can be of any further assistance please contact me.

Eric Lindquist, DMV, DABVP (CFM), Cert. IVUSS, CEO of SonoPath.com

[info@SonoPath.com](mailto:info@SonoPath.com)