



**PATIENT**

Brownie Cordero

**SPECIES**

Canine

**BREED**

Dachshund

**SEX**

Intact male

**AGE**

8 years

**WEIGHT**

12.2 lbs

**PRESENTING CLINICAL SIGNS**

History: Presented as a referral for a thyroid-neck region ultrasound examination. During the examination the thyroid area was wnl, but the area cranial to it, the left submandibular area, was swollen and pendulous with an apparent fluid-filled sq mass. The neck ultrasound was done and the fluid collected was submitted for evaluation.

**ULTRASONOGRAPHIC EXAMINATION**

The left and right left sided thyroid lobes revealed normal contour. The esophagus and trachea were unremarkable. The salivary glands bilaterally presented cystic changes with mineralization in the left salivary gland. Cysts were noted with echogenic debris in the right and left.

**ULTRASONOGRAPHIC FINDINGS**

Sialolithiasis and salivary cysts. Mild potential for abscessation depending upon fluid analysis and culture.

**INTERPRETATION OF THE FINDINGS & FURTHER RECOMMENDATIONS**

This is not likely neoplastic. Drainage and culture are indicated. Surgical intervention may be appropriate.

**INTERPRETED BY**

Eric Lindquist, DMV  
DABVP, Cert. IVUSS

**IMAGING PERFORMED BY**

Dr. Ferrer

**HOSPITAL NAME**

Paseos VC

**REFERRING VET**

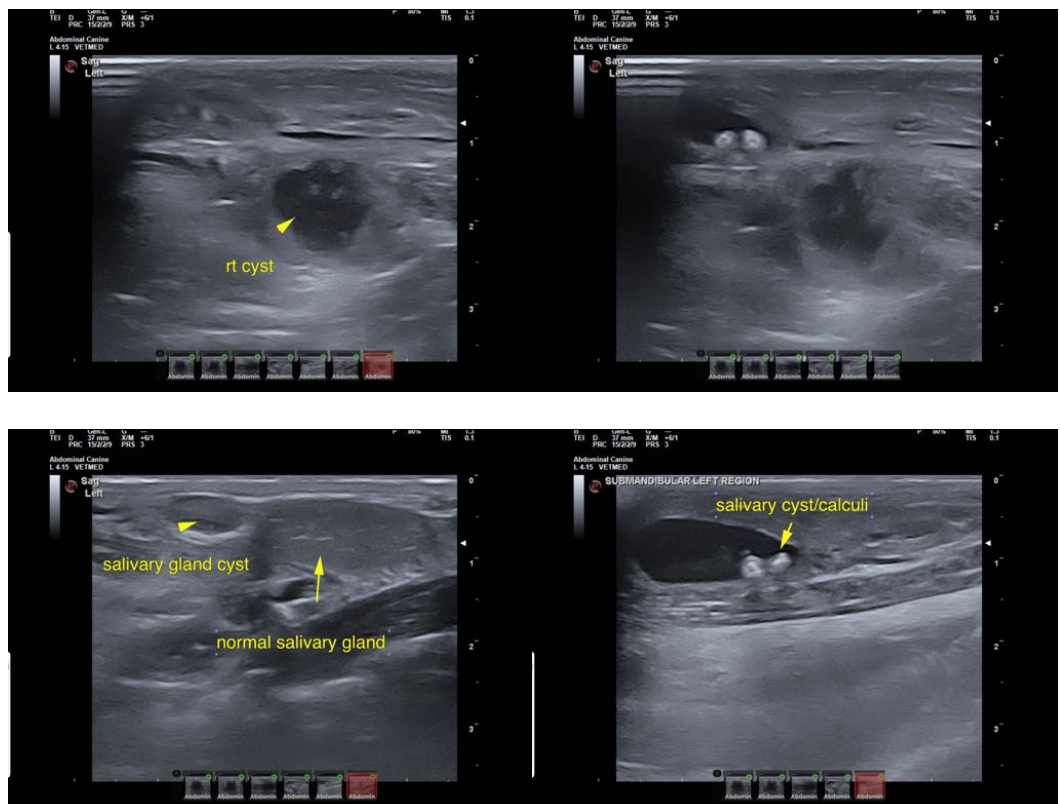
Dr. Archilla

**INVOICE**

42244

**DATE**

1/19/23





**PATIENT**

Brownie Cordero

**SPECIES**

Canine

**BREED**

Dachshund

**SEX**

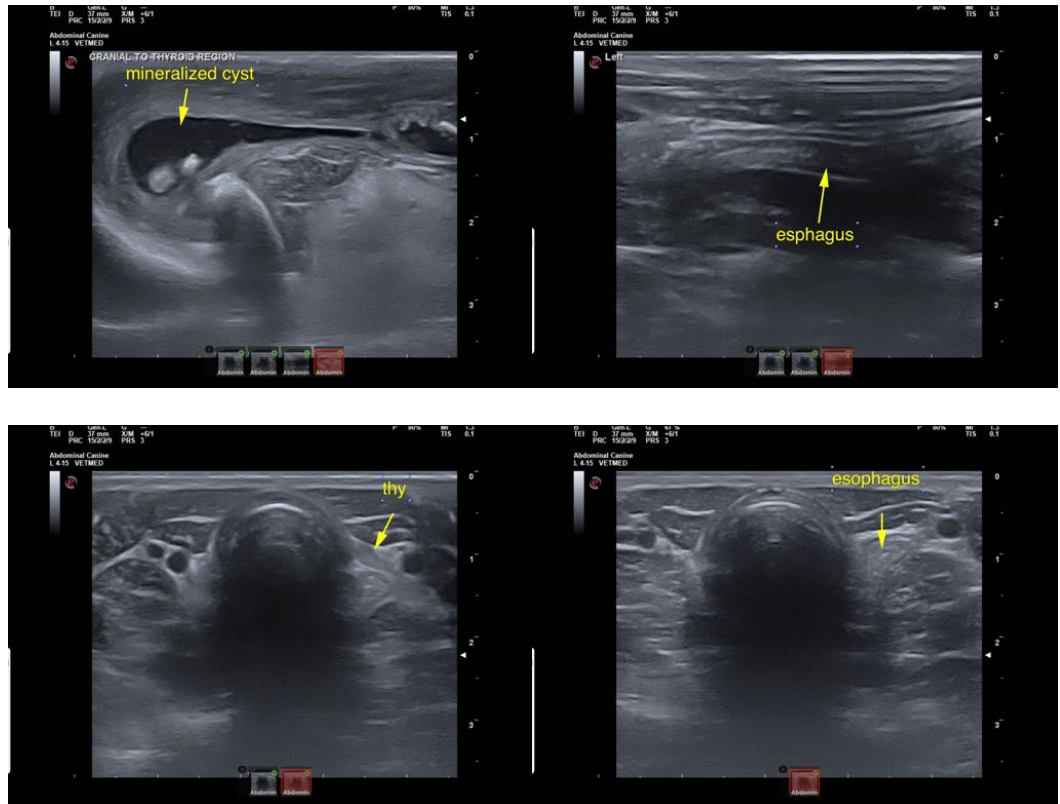
Intact male

**AGE**

8 years

**WEIGHT**

12.2 lbs



**INTERPRETED BY**

Eric Lindquist, DMV  
DABVP, Cert. IVUSS

**IMAGING PERFORMED BY**

Dr. Ferrer

**HOSPITAL NAME**

Paseos VC

**REFERRING VET**

Dr. Archilla

**INVOICE**

42244

**DATE**

1/19/23

The information and recommendations provided are based on the images presented by the referring veterinarian/sonographer. No evaluation can be communicated regarding pathology that was not visible in the image/video clips provided.

Thank you for this referral. If the clinical or image interpretation does not parallel your findings or if I can be of any further assistance please contact me.

Eric Lindquist, DMV, DABVP, Cert. IVUSS, CEO of SonoPath.com  
info@SonoPath.com