



**PATIENT PRESENTING CLINICAL SIGNS**

Pippa Carney Recheck splenic nodule.

**SPECIES ULTRASONOGRAPHIC EXAMINATION OF THE ABDOMEN**

Canine **Urinary System**

**BREED** The **urinary bladder**, trigone, and pelvic urethra presented normal thicknesses and normal tone. The ureters were not visible which is normal. No uroliths or sediment were visualized and anechoic urine was present. No evidence of inflammatory or neoplastic changes was noted. Ureteral papillae were normal.

Beagle

**SEX**

Spayed Female The **kidneys** revealed normal size and structure, corticomedullary definition and ratio for this age. The cortices presented largely uniform texture with normal echogenic relationship to liver and spleen. Medullary structure differed distinctly from the cortex and no evidence of pelvic dilation was present. The capsules were acceptably uniform without significant irregularities. Slight pinpoint mineralization was noted. The left kidney measured 5.07 cm. The right kidney measured 4.79 cm.

**AGE**

6 years

**WEIGHT**

23 lbs

**Adrenal Glands**

Both **adrenal glands** were visualized and recognized as having normal shape, size, position and echogenicity for this breed. The phrenic vasculature, glandular echogenicity and detail were unremarkable. Capsule, cortex, and medullary definition were normal for this age patient. The right adrenal gland measured 2.31 x 0.76 cm at the caudal pole and 0.76 cm at the cranial pole. The left adrenal gland measured 1.86 x 0.67 cm at the caudal pole and 0.47 cm at the cranial pole.

**INTERPRETED BY**

Eric Lindquist, DMV  
DABVP, Cert. IVUSS

**Spleen**

The **spleen** revealed a mass that measured 2.86 x 2.04 cm. The width of the mass has increased and the length has maintained the same. The mass was moderately vascular and was isoechoic to the surrounding mesentery. Other minor, heterogenous changes were noted in the spleen. Subjectively the splenic appears benign, yet capsular expansion is concerning. The other nodular changes noted on the prior ultrasound appear to have resorbed in the parenchyma; however, the parenchyma is slightly heterogenous.

**IMAGING PERFORMED BY**

Kelly Vazquez, CVT

**HOSPITAL NAME**

Animal General on Hudson

**REFERRING VET**

Dr. Zelinski

**Liver**

The **liver** images submitted revealed subjectively normal liver size, contour, and structure. Parenchymal echogenicity was naturally coarse and hypoechoic to the spleen. Vascular and biliary tracts were of normal volume with no evidence of congestion. The gallbladder presented acceptably thin walls with primarily anechoic content. The cystic and common bile ducts were normal. No pathological hepatic lymphadenopathy was evident. No overt structural evidence of inflammatory, infiltrative or regenerative pathology was evident.

**INVOICE**

95397

**DATE**

1/19/22



**PATIENT**

**Gastrointestinal**

Pippa Carney

Examination of the **gastrointestinal tract** revealed a stomach and intestine free of stasis, of normal wall thickness, acceptable curvilinear mural detail, and peristaltic activity. Small and large intestine demonstrated normal luminal chyme and stool consistency respectively. No obstructive or overt infiltrative disease was noted. No associated abnormal lymphatic activity was noted.

**SPECIES**

Canine

**BREED**

Beagle

**Pancreas**

The base and limbs of the **pancreas** were observed to be largely isoechoic to surrounding omental fat. Pancreatic duct and capsular contour were acceptably normal and parenchyma respected normal curvilinear patterns. No overt evidence of active inflammatory or neoplastic disease was noted.

**SEX**

Spayed Female

**Heart**

Rapid view of the heart revealed no evidence of pathology.

**AGE**

6 years

**ULTRASONOGRAPHIC FINDINGS**

**WEIGHT**

23 lbs

Splenic mass. Nodules noted on prior ultrasound appear to have resorbed in the parenchyma. Hyperplasia, emerging round cell neoplasia and hemangiosarcoma are all possible.

**INTERPRETED BY**

Eric Lindquist, DMV  
DABVP, Cert. IVUSS

**INTERPRETATION OF THE FINDINGS & FURTHER RECOMMENDATIONS**

Three view chest radiographs are recommended followed by a proactive splenectomy.

**IMAGING PERFORMED BY**

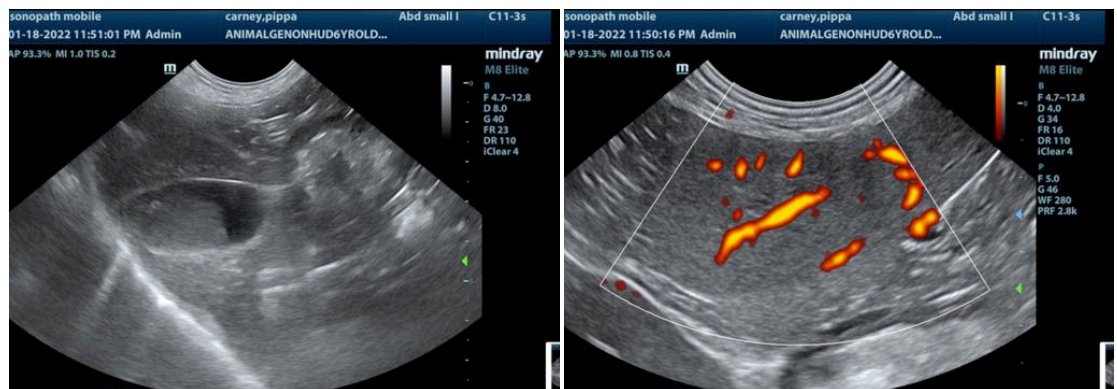
Kelly Vazquez, CVT

**HOSPITAL NAME**

Animal General on Hudson

**REFERRING VET**

Dr. Zelinski

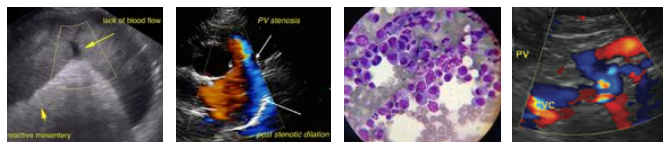


**INVOICE**

95397

**DATE**

1/19/22



**PATIENT**

Pippa Carney

**SPECIES**

Canine

**BREED**

Beagle

**SEX**

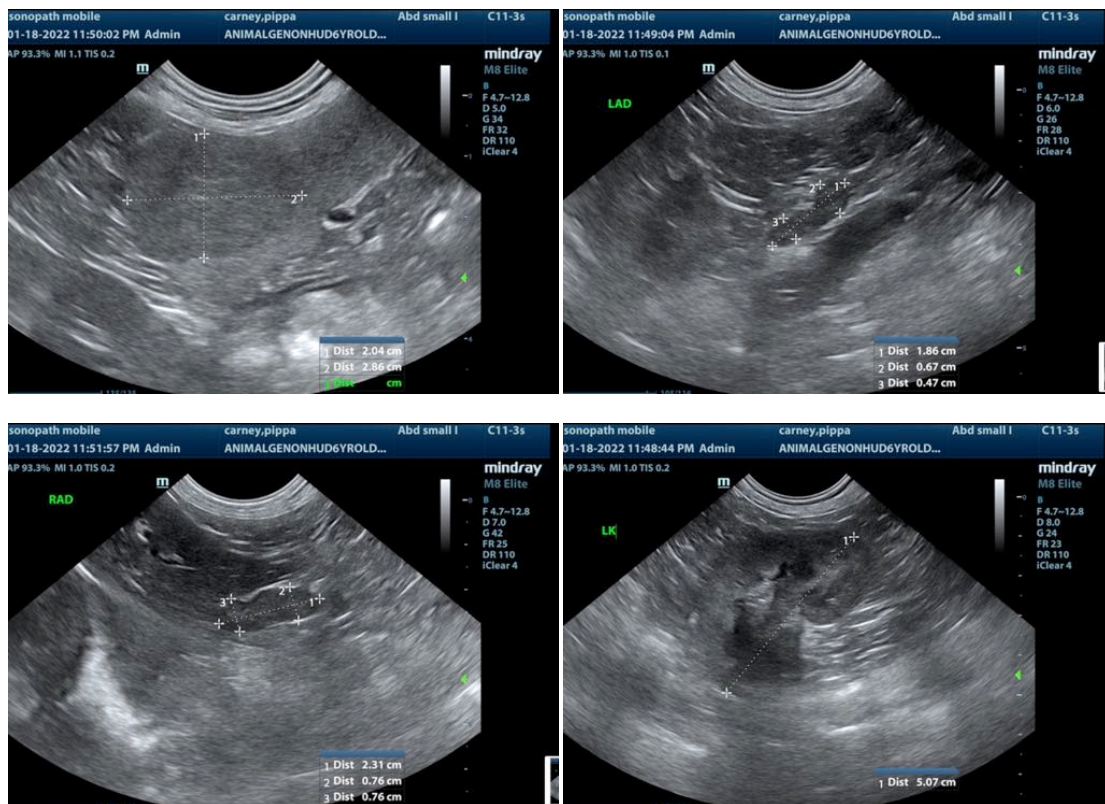
Spayed Female

**AGE**

6 years

**WEIGHT**

23 lbs



**INTERPRETED BY**

Eric Lindquist, DMV  
DABVP, Cert. IVUSS

**IMAGING PERFORMED BY**

Kelly Vazquez, CVT

**HOSPITAL NAME**

Animal General on  
Hudson

**REFERRING VET**

Dr. Zelinski

**INVOICE**

95397

**DATE**

1/19/22

The information and recommendations provided are based on the images presented by the referring veterinarian. No evaluation can be communicated regarding pathology that was not visible in the image/video clips provided.

Thank you for this referral. If the clinical or image interpretation does not parallel your findings or if I can be of any further assistance please contact me.

Eric Lindquist, DMV, DABVP, Cert. IVUSS, CEO of SonoPath.com  
info@SonoPath.com