



PATIENT

Bodhi Sipala

SPECIES

Canine

BREED

Labrador

SEX

Neutered male

AGE

9 years

WEIGHT

81 lbs

INTERPRETED BY

Eric Lindquist, DMV
DABVP, Cert. IVUSS

IMAGING PERFORMED BY

Dr. Scott

HOSPITAL NAME

HoHoKus VH

REFERRING VET

Dr. Scott

INVOICE

95418

DATE

1/19/22

PRESENTING CLINICAL SIGNS

Hx of splenectomy in March of 2021- was a hemangiosarcoma Pet is on l'm yunity and doing great- gets serial ultrasounds and chest rads to look for reemergence
Abnormal PE/Chem/CBC/UA Results: chest rads WNL

ULTRASONOGRAPHIC EXAMINATION OF THE ABDOMEN

Urinary System

The **urinary bladder**, trigone, and pelvic urethra presented normal thicknesses and normal tone. The pelvic urethra was imaged 2.0 cm beyond the cystourethral junction. The ureters were not visible which is normal. No uroliths or sediment were visualized and anechoic urine was present. No evidence of inflammatory or neoplastic changes was noted. Ureteral papillae were normal.

The **kidneys** revealed normal size and structure, corticomedullary definition and ratio for this age. The cortices presented largely uniform texture with normal echogenic relationship to liver and spleen. Medullary structure differed distinctly from the cortex and no evidence of pelvic dilation was present. The capsules were acceptably uniform without significant irregularities. The left kidney measured 6.0 cm. The right kidney measured 6.0 cm.

Adrenal Glands

Both **adrenal glands** were visualized and recognized as having normal shape, size, position and echogenicity for this breed. The phrenic vasculature, glandular echogenicity and detail were unremarkable. Capsule, cortex, and medullary definition were normal for this age patient. The left adrenal gland measured 0.6 cm. The right adrenal gland measured 0.8 cm at the cranial pole and 0.5 cm at the caudal pole.

Spleen

The **spleen** presented a smooth homogeneous parenchyma hyperechoic to liver and renal cortical parenchyma. The capsule was smooth without noticeable expansion or deviation from within the spleen or adjacent pathology. The splenic vasculature demonstrated normal volume without signs of congestion or thrombosis. No sonographic evidence of acute or chronic inflammatory, neoplastic, or infarctual changes was noted.

Liver

The **liver** revealed coarse architecture with mildly increased portal markings and minor enlargement. The gallbladder and common bile duct were unremarkable. There was no evidence of cavitated lesions. However, some nodular changes were noted in the left liver and were non-disruptive.



PATIENT

Gastrointestinal

Bodhi Sipala

Examination of the **gastrointestinal tract** revealed a stomach and intestine free of stasis, of normal wall thickness, acceptable curvilinear mural detail, and peristaltic activity. Small and large intestine demonstrated normal luminal chyme and stool consistency respectively. No obstructive or overt infiltrative disease was noted. No associated abnormal lymphatic activity was noted.

SPECIES

Canine

BREED

Labrador

Pancreas

The base and limbs of the **pancreas** were observed to be largely isoechoic to surrounding omental fat. Pancreatic duct and capsular contour were acceptably normal and parenchyma respected normal curvilinear patterns. No overt evidence of active inflammatory or neoplastic disease was noted.

SEX

Neutered male

Heart

Rapid view of the heart revealed no evidence of pathology.

AGE

9 years

ULTRASONOGRAPHIC FINDINGS

WEIGHT

81 lbs

Mild hepatic remodeling with minor nodular changes.

Stable abdomen.

INTERPRETED BY

Eric Lindquist, DMV
DABVP, Cert. IVUSS

INTERPRETATION OF THE FINDINGS & FURTHER RECOMMENDATIONS

There was no obvious evidence of metastatic disease.

IMAGING PERFORMED BY

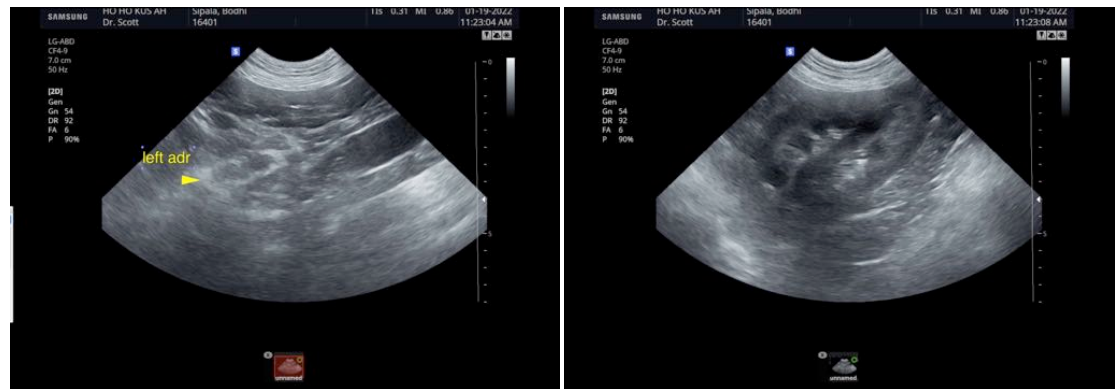
Dr. Scott

HOSPITAL NAME

HoHoKus VH

REFERRING VET

Dr. Scott



INVOICE

95418

DATE

1/19/22



PATIENT

Bodhi Sipala

SPECIES

Canine

BREED

Labrador

SEX

Neutered male

AGE

9 years

WEIGHT

81 lbs

INTERPRETED BY

Eric Lindquist, DMV
DABVP, Cert. IVUS

IMAGING PERFORMED BY

Dr. Scott

HOSPITAL NAME

HoHoKus VH

REFERRING VET

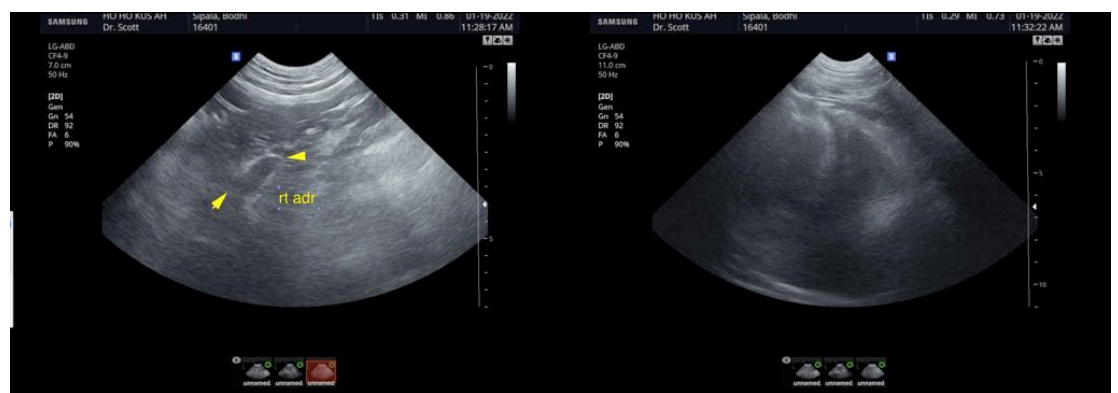
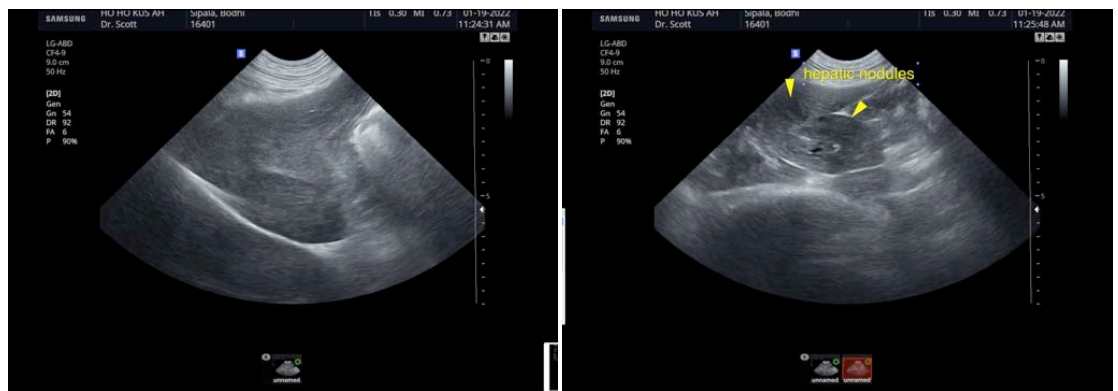
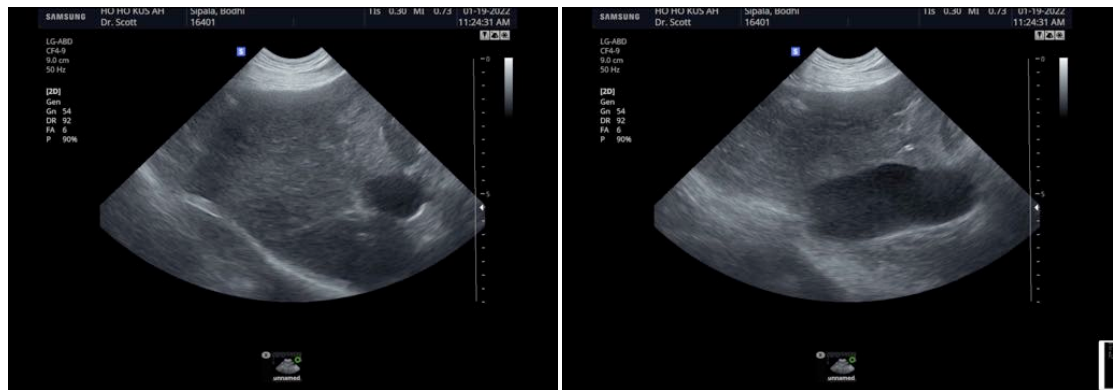
Dr. Scott

INVOICE

95418

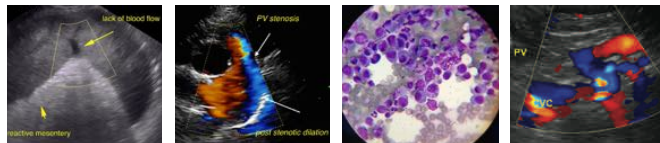
DATE

1/19/22



The information and recommendations provided are based on the images presented by the referring veterinarian. No evaluation can be communicated regarding pathology that was not visible in the image/video clips provided.

Thank you for this referral. If the clinical or image interpretation does not parallel your findings or if I can be of any further assistance please contact me.



PATIENT

Eric Lindquist, DMV, DABVP, Cert. IVUSS, CEO of SonoPath.com
info@SonoPath.com

Bodhi Sipala

SPECIES

Canine

BREED

Labrador

SEX

Neutered male

AGE

9 years

WEIGHT

81 lbs

INTERPRETED BY

Eric Lindquist, DMV
DABVP, Cert. IVUSS

**IMAGING
PERFORMED BY**

Dr. Scott

HOSPITAL NAME

HoHoKus VH

REFERRING VET

Dr. Scott

INVOICE

95418

DATE

1/19/22