



PATIENT

Kristy McGee

SPECIES

Canine

BREED

Labrador
Retriever/Mix

SEX

Spayed Female

AGE

10 Years

WEIGHT

68 Pounds

INTERPRETED BY

Eric Lindquist, DMV,
DABVP (CFM), Cert.
IVUSS

IMAGING PERFORMED BY

Dr. Jeremiah Gabriel

HOSPITAL NAME

Central Jersey AH

REFERRING VET

Dr. Jeremiah Gabriel

INVOICE

35478

DATE

1/18/26

PRESENTING CLINICAL SIGNS

History: Anorexic lethargic fever 102.8 F history of liver enzymes elevation but last blood work was normal 6 months ago.

Abnormal PE/Chem/CBC/UA Results: WBC 4.36 Lymphocytes 0.66 Albumin 4.1 ALT 912 GGT 19 Lipase 3,027.

ULTRASONOGRAPHIC EXAMINATION OF THE ABDOMEN

Urinary System

The **urinary bladder**, trigone, and pelvic urethra presented normal thicknesses and normal tone. The ureters were not visible which is normal. No uroliths or sediment were visualized and anechoic urine was present. No evidence of inflammatory or neoplastic changes were noted. Ureteral papillae were normal. The pelvic urethra was imaged 1.0 cm beyond the cystourethral junction.

The **kidneys** revealed largely normal size and structure, corticomedullary definition and ratio (cortex 1/3 of medulla) were essentially maintained with some age-related loss of curvilinear patterns regarding the capsule and C/M junction. The cortices presented largely uniform texture with some increased echogenicity expected for this age patient. Medullary structure differed distinctly from that of the cortex, and no evidence of pelvic dilation was present. Slight mineralizations were noted. The left kidney measured 6.0 cm. The right kidney measured 6.3 cm.

Adrenal Glands

The **left adrenal gland** was visualized and recognized as having normal shape, size, position and echogenicity for this breed. The phrenic vasculature, glandular echogenicity and detail were unremarkable. Capsule, cortex, and medullary definition were normal for this age patient. The left adrenal gland measured 0.5 cm.

The **right adrenal gland** was not visualized.

Spleen

The **spleen** was enlarged and folded upon itself with uniform parenchyma, consistent with benign splenic enlargement or reactive spleen.

Liver

The **liver** images from right and left intercostal as well as subcostal views revealed subjectively normal liver size, contour, and structure. Some mild age-related parenchymal remodeling was noted but likely not clinically significant at this time. Vascular and biliary tracts were of normal volume, and no evidence of congestion was noted. The gallbladder presented some dependent debris with essentially normal contour. The cystic and common bile ducts were normal. No overt evidence of active inflammatory, infiltrative or regenerative pathology was noted but should be paired with current or past LE elevations regarding any clinical significance to this presentation. The hepatic lymph nodes were unremarkable.

Gastrointestinal

Examination of the **gastrointestinal tract** revealed a stomach and intestine free of stasis, of normal wall thickness, acceptable curvilinear mural detail, and peristaltic activity. Small and large intestine



PATIENT

Kristy McGee

SPECIES

Canine

BREED

Labrador
Retriever/Mix

SEX

Spayed Female

AGE

10 Years

WEIGHT

68 Pounds

INTERPRETED BY

Eric Lindquist, DMV,
DABVP (CFM), Cert.
IVUS

IMAGING PERFORMED BY

Dr. Jeremiah Gabriel

HOSPITAL NAME

Central Jersey AH

REFERRING VET

Dr. Jeremiah Gabriel

INVOICE

35478

DATE

1/18/26

demonstrated normal luminal chyme and stool consistency respectively. No obstructive or overt infiltrative disease was noted. No associated abnormal lymphatic activity was noted.

Pancreas

The base and limbs of the **pancreas** were observed to be largely isoechoic to surrounding omental fat. Pancreatic duct and capsular contour were acceptably normal and parenchyma respected normal curvilinear patterns. No overt evidence of active inflammatory or neoplastic disease was noted.

Free Abdomen

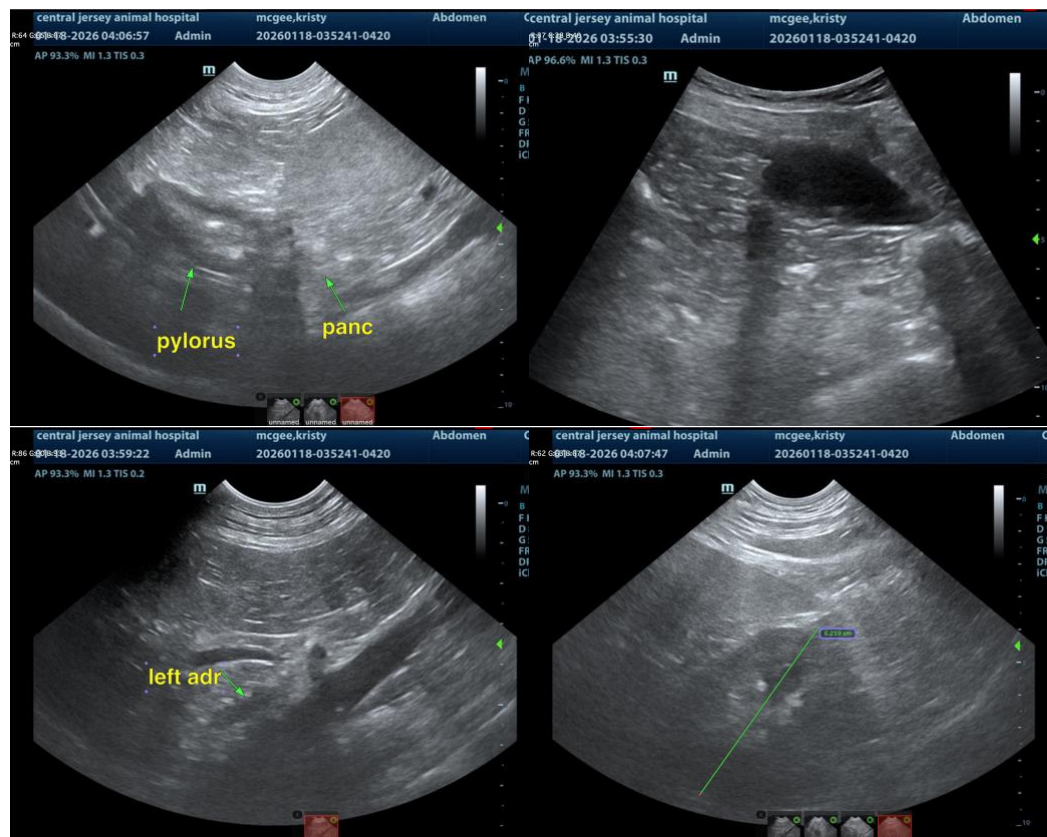
A large amount of **abdominal fat** was noted in this patient.

ULTRASONOGRAPHIC FINDINGS

- Mild hypersplenism
- Nonspecific inflammatory hepatopathy
- Age-related renal changes with mineralization
- Large amount of abdominal fat

INTERPRETATION OF THE FINDINGS & FURTHER RECOMMENDATIONS

The cause of immune stimulation should be investigated. FNA of the spleen and liver would be appropriate (25 gauge FNA of the spleen and 22 gauge FNA of the liver are indicated).





PATIENT

Kristy McGee

SPECIES

Canine

BREED

Labrador
Retriever/Mix

SEX

Spayed Female

AGE

10 Years

WEIGHT

68 Pounds

INTERPRETED BY

Eric Lindquist, DMV,
DABVP (CFM), Cert.
IVUSS

IMAGING PERFORMED BY

Dr. Jeremiah Gabriel

HOSPITAL NAME

Central Jersey AH

REFERRING VET

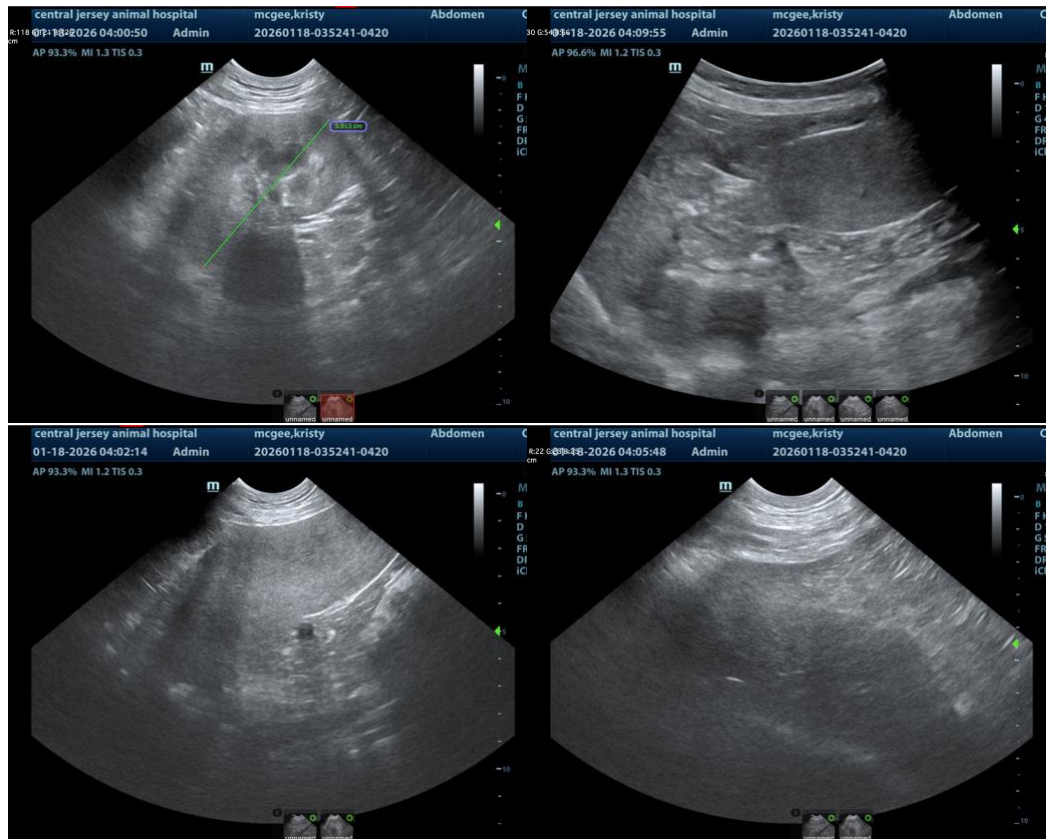
Dr. Jeremiah Gabriel

INVOICE

35478

DATE

1/18/26



The information and recommendations provided are based on the images presented by the referring veterinarian/sonographer. No evaluation can be communicated regarding pathology that was not visible in the image/video clips provided.

Thank you for this referral. If the clinical or image interpretation does not parallel your findings or if I can be of any further assistance please contact me.

Eric Lindquist, DMV, DABVP(CFM), Cert. IVUSS,
CEO, Owner, Founder -- SonoPath.com
info@SonoPath.com