



**PATIENT**

Phoebe Kupka

**SPECIES**

Canine

**BREED**

Great Pyrenes

**SEX**

Spayed female

**AGE**

12 years

**WEIGHT**

50 lbs

**PRESENTING CLINICAL SIGNS**

History: PRESENTED FOR: anorexia. REPORTED SYMPTOM: Phoebe has been eating very little for the past couple days, with decreased appetite for a few days before that. Not sure about bowel movements. No vomiting noticed. Phoebe has been on AmoxiClav since 1/4/23-AFTER the appetite had already decreased. Her appetite has worsened. Is interested in food, but then walks away. VITALS: 50 pounds Temperature: 103.2 (normal range is 99.5 F- 102.0 F) Heart Rate: 144 bpm (normal is 70-80) Respiratory Rate: 48 bpm (normal is 15-25) Mucous Membrane Color: Pale Pink Capillary Refill Time: <2 seconds CURRENT MEDICATIONS: Current Medications / Nutraceuticals, dose, and frequency: Amoxi-clav 91.4 mg/mL (5.4 mL BID for 14d) started 1/4/2023, was on Entyce for 3 days :1/4-1/6. Trazodone as needed Heartworm prevention ABNORMAL EXAM FINDINGS: Phoebe lost weight, and is thin with body score of 2-3/9: She had gained weight and was 54.3 on 12/7/22, 51.7 on 1/4/23, and today is 50.4 pounds. No apparent pain on abdominal palpation. Grade II/III dental calculus and gingivitis. Pale mucous membranes. Lacks PLR, but dazzle and menace reflexes present. Nuclear sclerosis. No abnormalities noted on retinal exam. Lacks proprioception in both front and left rear limbs, and slow on the right rear limb. No shaking. Muscle atrophy or rear legs. Lacks PLR, but dazzle and menace reflexes present. No apparent pain on deep muscle palpation of the neck or lumbar spine. No apparent pain on extension or flexion of the neck. HISTORY: Previous splenectomy for multiple masses. Histopathologic Diagnosis: Splenic nodular hyperplasia. LAB RESULTS: Urinalysis results reveal protein 100, low numbers of red blood cell, moderate white blood cells, possible cocci bacteria on cytology stain, with pH of 5.5 and specific gravity of 1.035. UPC is >=0.5-<2.0. On 1/4/2023: NSF on fecal gram stain. CBC results reveal mild anemia. Chemistry: mild increase in ALKP (new). ASSESSMENT AND PLAN: Urine culture submitted. Amoxi-clav was discontinued. A Cerenia injection was administered. Entyce and Cerenia begun orally pending results.

**INTERPRETED BY**

Eric Lindquist, DMV  
DABVP, Cert. IVUSS

**IMAGING PERFORMED BY**

Dr. Rupley

**HOSPITAL NAME**

All Pets Medical Center

**REFERRING VET**

Dr. Rupley

**INVOICE**

42213

**DATE**

1/18/23

**ULTRASONOGRAPHIC EXAMINATION OF THE ABDOMEN**

**Urinary System**

The **urinary bladder**, trigone, and pelvic urethra presented normal thicknesses and normal tone. The bladder revealed slight ventral polyp that measured 1.0 cm. It appeared to be in the caudal ventral bladder, yet exact position cannot be completely ascertained. The ureters were not visible which is normal. No uroliths or sediment were visualized and anechoic urine was present.

The **kidneys** revealed normal size and structure, corticomedullary definition and ratio for this age. The cortices presented largely uniform texture with normal echogenic relationship to liver and spleen. Medullary structure differed distinctly from the cortex and no evidence of pelvic dilation was present. The capsules were acceptably uniform without significant irregularities. The left kidney measured 7.6 cm. The right kidney measured 6.7 cm.

**Adrenal Glands**

Both **adrenal glands** were visualized and recognized as having normal shape, size, position and echogenicity for this breed. The phrenic vasculature, glandular echogenicity and detail were unremarkable. Capsule, cortex, and medullary definition were normal for this age patient. The left adrenal gland measured 0.9 cm.

**Spleen**

The **spleen** was not visualized as it was previously removed.



**PATIENT**

**Liver**

Phoebe Kupka

The **liver** are mildly enlarged and uniform. The gallbladder presented acceptably thin walls with primarily anechoic content. The cystic and common bile ducts were normal. No pathological hepatic lymphadenopathy was evident. No overt structural evidence of inflammatory, infiltrative or regenerative pathology was evident.

**SPECIES**

Canine

**BREED**

Great Pyrenes

**Gastrointestinal**

Examination of the **gastrointestinal tract** revealed a stomach and intestine free of stasis, of normal wall thickness, acceptable curvilinear mural detail, and peristaltic activity. Small and large intestine demonstrated normal luminal chyme and stool consistency respectively. No obstructive or overt infiltrative disease was noted. No associated abnormal lymphatic activity was noted.

**SEX**

Spayed female

**Pancreas**

**AGE**

12 years

The base and limbs of the **pancreas** were observed to be largely isoechoic to surrounding omental fat. Pancreatic duct and capsular contour were acceptably normal and parenchyma respected normal curvilinear patterns. No overt evidence of active inflammatory or neoplastic disease was noted.

**WEIGHT**

50 lbs

**ULTRASONOGRAPHIC FINDINGS**

Structurally unremarkable abdomen.

**INTERPRETED BY**

Eric Lindquist, DMV  
DABVP, Cert. IVUSS

**INTERPRETATION OF THE FINDINGS & FURTHER RECOMMENDATIONS**

There was no obvious evidence of pathology in the abdomen that would be responsible for the clinical signs. Thoracic, CNS or orthopedic pain related disease should be considered.

**IMAGING PERFORMED BY**

Dr. Rupley

**HOSPITAL NAME**

All Pets Medical Center

**REFERRING VET**

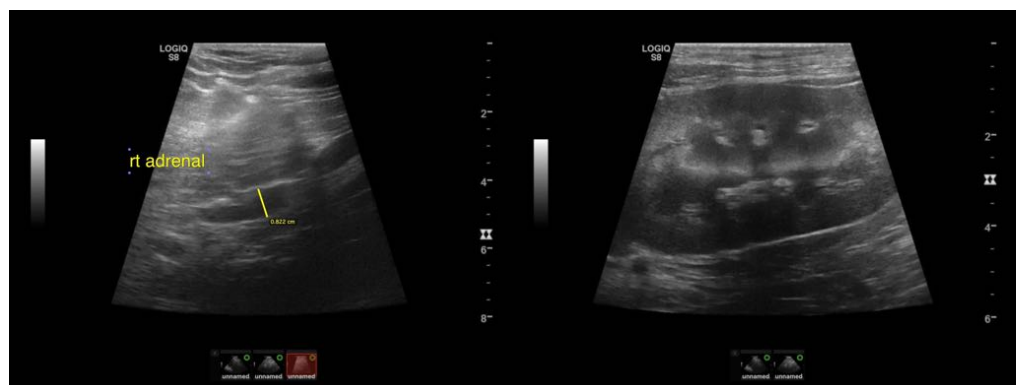
Dr. Rupley

**INVOICE**

42213

**DATE**

1/18/23





**PATIENT**

Phoebe Kupka

**SPECIES**

Canine

**BREED**

Great Pyrenes

**SEX**

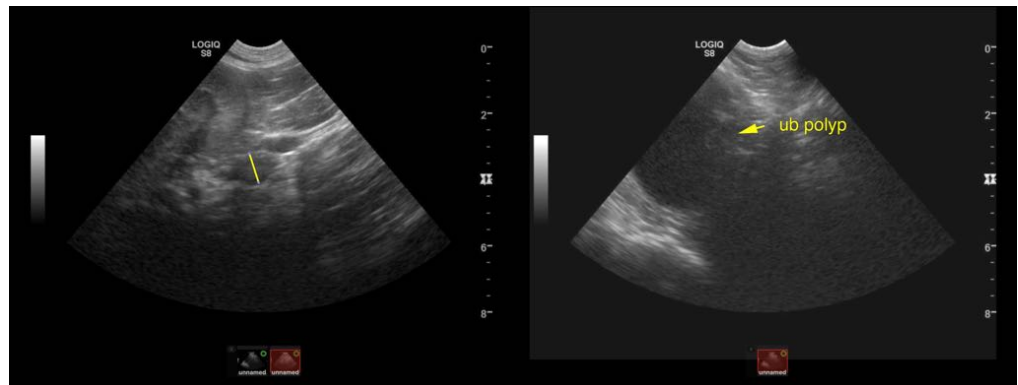
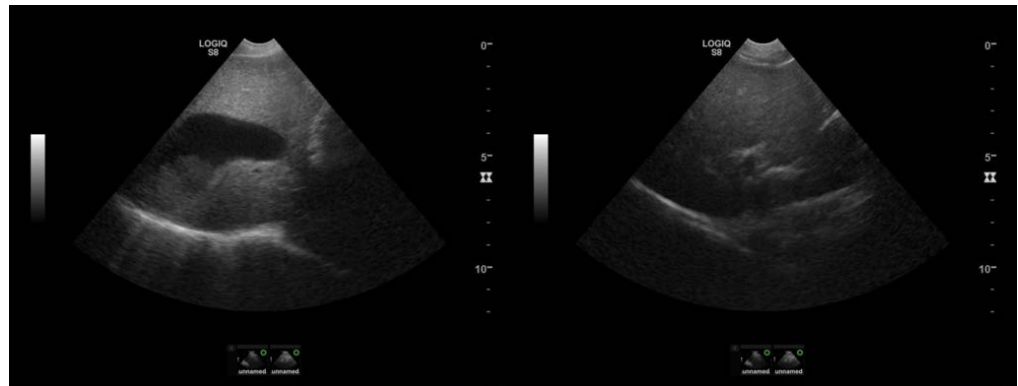
Spayed female

**AGE**

12 years

**WEIGHT**

50 lbs



**INTERPRETED BY**

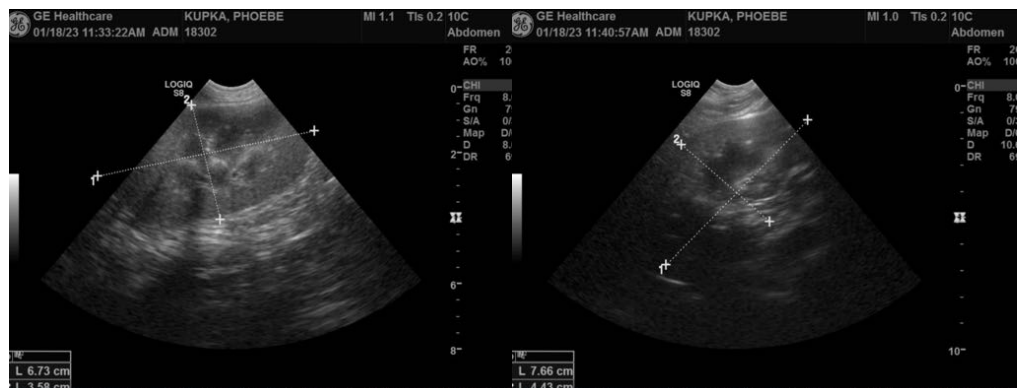Eric Lindquist, DMV  
DABVP, Cert. IVUSS

**IMAGING PERFORMED BY**

Dr. Rupley

**HOSPITAL NAME**

All Pets Medical Center



**REFERRING VET**

Dr. Rupley

**INVOICE**

42213

**DATE**

1/18/23

The information and recommendations provided are based on the images presented by the referring veterinarian/sonographer. No evaluation can be communicated regarding pathology that was not visible in the image/video clips provided.

Thank you for this referral. If the clinical or image interpretation does not parallel your findings or if I can be of any further assistance please contact me.

**Eric Lindquist, DMV, DABVP, Cert. IVUSS, CEO of SonoPath.com**  
[info@SonoPath.com](mailto:info@SonoPath.com)



**PATIENT**

Phoebe Kupka

**SPECIES**

Canine

**BREED**

Great Pyrenes

**SEX**

Spayed female

**AGE**

12 years

**WEIGHT**

50 lbs

**INTERPRETED BY**

Eric Lindquist, DMV  
DABVP, Cert. IVUSS

**IMAGING PERFORMED BY**

Dr. Rupley

**HOSPITAL NAME**

All Pets Medical Center

**REFERRING VET**

Dr. Rupley

**INVOICE**

42213

**DATE**

1/18/23



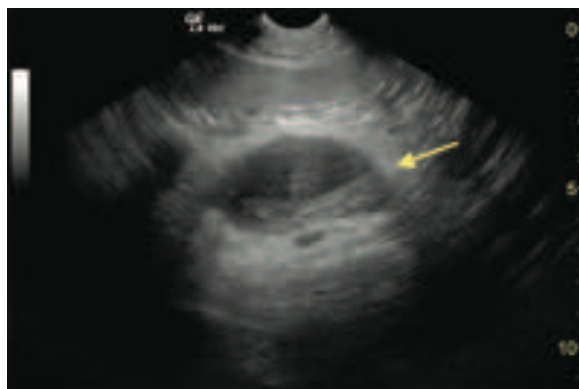
The following is an applicable excerpt from the *Curbside Guide to Diagnosis and Treatment of Sonographic Disease* offered by [SonoPath.com](http://sonopath.com) Lindquist, Fra Lobetti, and Modler.

An essential quick guide for every general practitioner and sonographer.

<https://sonopath.com/products/curbside-guide-editing-due-release-1201201>

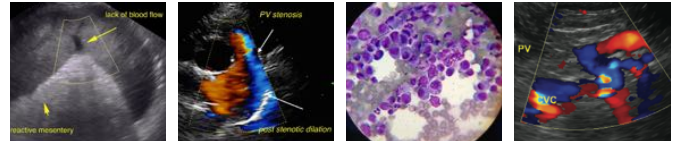
Fever of Unknown Origin

<http://www.sonopath.com/FUO>



Long axis of the mid-abdomen in a dog with an omental abscess after foreign body penetration from the gastrointestinal tract. The hypoechoic necrotic center of the lesion is surrounded by a thick echogenic capsule and hyperechoic mesenteric fat (arrow) indicating focal peritonitis. The linear echogenic needle (5 cm depth) is barely visible owing to the density of the purulent material contained within the abscess.

Description: The definition of a fever of unknown origin (FUO) has not been clearly defined for animals. Currently, it is either understood to be a fever that does not resolve within the period one would expect for a “self-limiting infection” being treated with appropriate antimicrobial therapy, or that for which an underlying diagnosis has not been determined despite considerable diagnostic effort. The common causes of FUO were summarized concisely in a presentation at the American


**PATIENT**

Phoebe Kupka

College of Veterinary Internal Medicine 2004 Forum. The presenters synthesized information from three veterinary papers on the subject, which suggested the following:

**SPECIES**

Canine

**BREED**

Great Pyrenes

**SEX**

Spayed female

**AGE**

12 years

**WEIGHT**

50 lbs

Final Diagnosis	Bennett (dogs & cats)	Dunn and Dunn (dogs only)	Lunn (dogs & one cat)	Total
Infection	21	16	10	47
Immune	18	22	6	46
Bone marrow disease	4	22	2	28
Neoplasia (outside marrow)	0	10	2	12
Miscellaneous	2	12	2	16
No diagnosis	0	19	2	21
<b>TOTALS</b>	<b>45</b>	<b>101</b>	<b>24</b>	<b>170</b>

**INTERPRETED BY**

 Eric Lindquist, DMV  
 DABVP, Cert. IVUSS

**IMAGING PERFORMED BY**

Dr. Rupley

**HOSPITAL NAME**

All Pets Medical Center

**REFERRING VET**

Dr. Rupley

**INVOICE**

42213

**DATE**

1/18/23

The types of infection diagnosed in this case series were varied, ranging from discospondylitis (8 cases), blastomycosis (6), and bacterial endocarditis (4), to leishmaniasis (1), prostatitis (1), and *Ehrlichia canis* infection (1); a multitude of other infectious causes also fell within the spectrum. Of the cases in which immune-mediated disease was found, 44% had immune-mediated polyarthritis. Bone marrow diseases included myeloproliferative disease, myelodysplasia (8), lymphocytic leukemia (8), myeloma (3), chronic granulocytic leukemia (3), lymphoblastic leukemia, and malignant histiocytosis. The types of neoplasia located outside the bone marrow included lymphoma (6), metastatic disease (2), and neoplasms of the lung, spleen, and stomach. Finally, miscellaneous diseases included hypertrophic osteodystrophy (6), meningitis (3), portosystemic shunt (3), lymphadenitis (2), panosteitis, and intervertebral disc disease. Overall, the most common causes across all cases were polyarthritis (44), lymphoid neoplasia (15), discospondylitis (8), myelodysplasia (8), hypertrophic osteodystrophy (6), and blastomycosis (6).

**Clinical Signs:** Animals usually present with either persistent or waxing and waning fevers ranging from 103°F to 106°F. Other clinical signs depend on the underlying cause of the fever. Careful and thorough physical examination is required to assess potential causes.

**Diagnostics:** FOU etiologies are partly related to geography, and thus locale or travel history should factor into a practitioner's diagnostic approach. A patient's lifestyle may also provide clues regarding exposure to certain etiologic agents. Therefore, conducting a thorough history can unveil important pieces of the diagnostic puzzle. Physical examination is especially important and should include an inspection of all accessible lymph nodes, palpation and movement of the joints,



**PATIENT**

Phoebe Kupka

a fundic examination, a neurological evaluation, spinal and limb palpation and range of motion tests, and a rectal examination.

**SPECIES**

Canine

A minimum database should include a CBC reviewed by a clinical pathologist, as well as a biochemical profile and urinalysis. Retroviral testing should also be considered in cats. In areas where tick-borne disease is prevalent, in-house testing should be performed early. Advanced laboratory work can include: urine culture, blood culture, and infectious disease panels (PCR and/or serology). In dogs, one may screen for the following infectious agents: *Ehrlichia* spp., *Borrelia burgdorferi*, Rock Mountain Spotted Fever, *Bartonella* spp. (culture and PCR), and *Leptospira* spp. in cases of hepatic or renal involvement. In cats, one should evaluate for FeLV, FIV, feline infectious peritonitis (FIP) virus, toxoplasmosis, *Hemoplasma* spp. (*Mycoplasma*), and *Bartonella* spp. (culture and PCR). Testing for *Ehrlichia* spp., *Rickettsia* spp., and *Anaplasma phagocytophilum* can also be considered. A fungal assay is indicated if the patient lives in or has had exposure to a region with a higher incidence of fungal disease. Other infectious disease tests may be performed depending on the geographical location of the pet. Screening for *Brucella* should be done in breeding dogs. Immune-mediated disease screening can include a Coomb's test, a slide agglutination test (if the patient is anemic), and an antinuclear antibody (ANA) test. Immune disease is often a diagnosis of exclusion.

**BREED**

Great Pyrenes

**SEX**

Spayed female

**AGE**

12 years

**WEIGHT**

50 lbs

Imaging should include thoracic radiographs, abdominal ultrasound, and/or abdominal radiographs. Ultrasound can be very useful for assessing evidence of cholangiohepatitis, pyelonephritis, chronic urinary tract infection, abscess formation, peritonitis, and neoplasia; it also permits an examination of the intra-abdominal lymph nodes. An echocardiogram can offer assessment for vegetative endocarditis, whereas spinal radiographs offer assessment for discospondylitis. In cases where all other testing has proven negative and the patient has not responded to broad-spectrum antibiotics and supportive care, arthrocentesis should be considered to evaluate for septic joint disease, immune-mediated polyarthritis, and infectious disease. Finally, one can consider assessing the cerebrospinal fluid for meningoencephalitis, GME, and meningitis/arteritis. A bone marrow exam should be performed if blood dyscrasias are noted on the CBC.

**INTERPRETED BY**

Eric Lindquist, DMV  
DABVP, Cert. IVUSS

**IMAGING PERFORMED BY**

Dr. Rupley

**HOSPITAL NAME**

All Pets Medical Center

**REFERRING VET**

Dr. Rupley

Treatment: Treatment of the fever depends entirely on the underlying cause. Ideally, a thorough diagnostic plan will yield a diagnosis that will guide the appropriate therapeutic course. However, if an exhaustive approach has not produced a definitive diagnosis and there is no response to broad-spectrum antibiotics, trial therapy with immunosuppressive agents such as prednisolone can be considered to treat presumed immune-mediated diseases. Given the potential for negative sequelae should an underlying infection be present, one must be certain that the investigation is thorough and monitor the patient's response carefully.

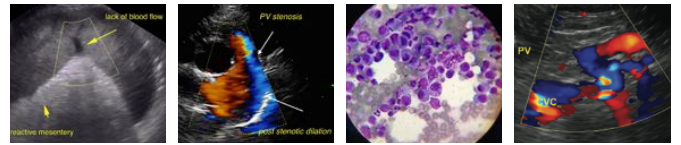
**INVOICE**

42213

Conclusion: If a documented fever has not responded to antibiotics, antipyretics, or general nursing care, it is important to obtain a diagnosis to guide more specific treatment. A systematic physical examination and thorough history-taking will help inform further diagnostics in addition to what is revealed by the minimum database.

**DATE**

1/18/23



**PATIENT**

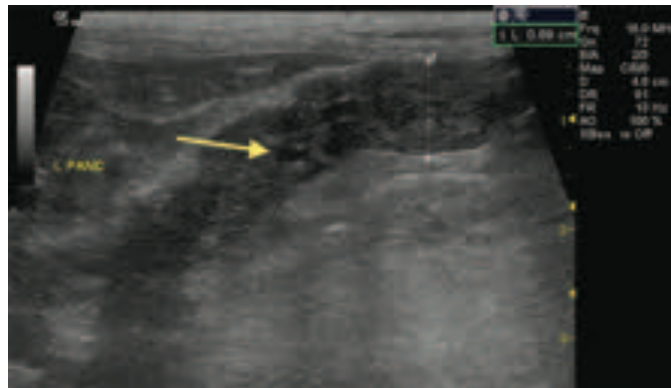
Phoebe Kupka

**SPECIES**

Canine

**BREED**

Great Pyrenes



Long axis of the left pancreatic limb (between calipers) in a cat with pancreatitis after undergoing a renal transplant. Note the decrease in echogenicity and mild loss of regular echotexture of the swollen and irregularly contoured pancreas. Also note the mild dilation of the pancreatic duct (arrow). Focal peritonitis is evident by increased echogenicity and loss of the linear echotexture of the surrounding mesentery.

**SEX**

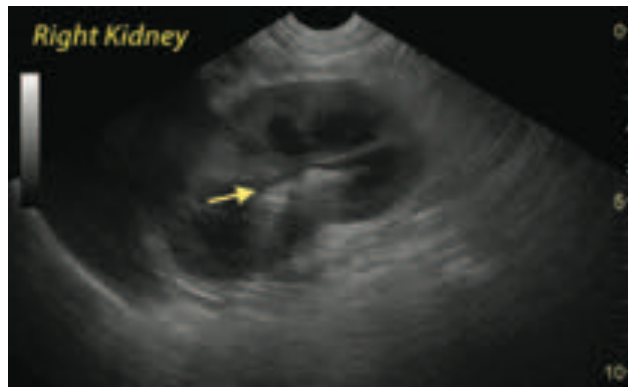Spayed female

**AGE**

12 years

**WEIGHT**

50 lbs



Long axis of the right kidney in a dog with pyelonephritis. Note the increased echogenicity and irregular outline of the renal crest and diverticuli and the mild dilation of the renal pelvis (arrow).

**INTERPRETED BY**

Eric Lindquist, DMV  
DABVP, Cert. IVUSS

**IMAGING PERFORMED BY**

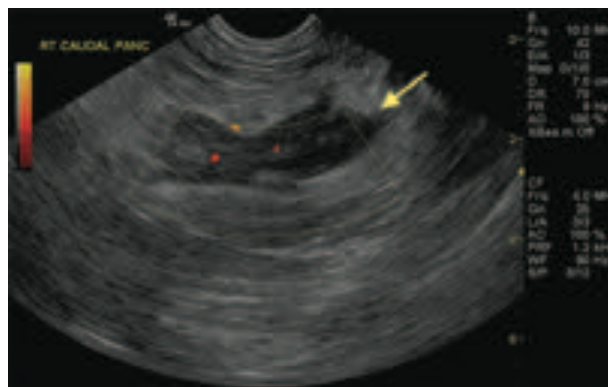
Dr. Rupley

**HOSPITAL NAME**

All Pets Medical Center

**REFERRING VET**

Dr. Rupley



Long axis of the right pancreatic limb in a dog with acute pancreatitis. The swollen hypoechoic pancreas is embedded in hyperechoic mesenteric fat (arrow). Note the regional differences in blood flow intensity within the parenchyma as demonstrated by Power Doppler interrogation compatible with multifocal disruption of vascularization as a sequela of the severe inflammation.

**INVOICE**

42213

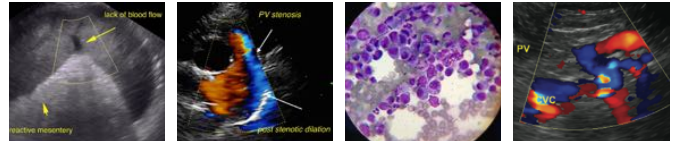
**DATE**

1/18/23

References:

Bennet D. Diagnosis of pyrexia of unknown origin. *In Practice* 1995;17(10):470-81.

Dunn KJ, Dunn JK. Diagnostic investigations in 101 dogs with pyrexia of unknown origin. *J Sm Anim Pract* 1998;39(12):574-80.



**PATIENT**

Phoebe Kupka

Flood J. The diagnostic approach to fever of unknown origin in cats. *Compend Contin Educ Vet* 2009;31(1):26-31.

**SPECIES**

Canine

Flood J. The diagnostic approach to fever of unknown origin in dogs. *Compend Contin Educ Vet* 2009;31(1):14-21.

**BREED**

Great Pyrenes

Lappin MR. The role of blood borne pathogens in feline fever of unknown origin. Proceedings from the American College of Veterinary Internal Medicine, Denver, CO, June 15-18, 2011.

**SEX**

Spayed female

Lunn KF. Fever of unknown origin: a systematic approach to diagnosis. *Compend Contin Educ Vet* 2001;23(11):976-92.

Lunn KF. Fever of unknown origin: appropriate choice of diagnostic tests. Proceedings from the American College of Veterinary Internal Medicine, Minneapolis, MN, June 9-12, 2004.

**AGE**

12 years

**WEIGHT**

50 lbs

**INTERPRETED BY**

Eric Lindquist, DMV  
DABVP, Cert. IVUSS

**IMAGING  
PERFORMED BY**

Dr. Rupley

**HOSPITAL NAME**

All Pets Medical Center

**REFERRING VET**

Dr. Rupley

**INVOICE**

42213

**DATE**

1/18/23