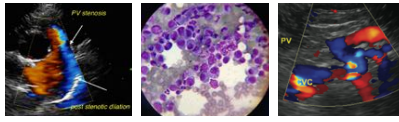


IMAGING PERFORMED BY

IntraPet.com



Clinical Sonography & Telecytology

EDUCATIONAL TELECONSULTATION SERVICES™

1-800-838-4268 info@sonopath.com SonoPath.com

**DATE**

1/18/23

**PRESENTING CLINICAL SIGNS**

Hx since a puppy before spay of urinary accidents sometimes even after had just been outside, licking vulva, vulvar discharge. Did not respond to antibiotic therapy at previous vet. Previous diagnostics done at previous vet normal. Pe largely WNL

**PATIENT**

Mia Booth

Current Medications: None at this time.

Lab Results: blood chem and cbc largely wnl, negative urine culture, normal UA

Date of Previous IntraPet Ultrasound: No previous.

Sedation: IV Dex Domitor.

Stat Report: Not requested.

Imaging Performed By: Rachel Brillhart, RDMS.

**SPECIES**

Canine

**BREED**

Beagle Mix

**ULTRASONOGRAPHIC EXAMINATION OF THE ABDOMEN**

**Urinary System**

The **urinary bladder**, trigone, and pelvic urethra presented normal thicknesses and normal tone. The ureters were not visible which is normal. No uroliths or sediment were visualized and anechoic urine was present. No evidence of inflammatory or neoplastic changes was noted. Ureteral papillae were normal.

**SEX**

Spayed female

The uterus was uniform and measured 0.5 cm.

**AGE**

10/15/21

The **kidneys** revealed normal size and structure, corticomodullary definition and ratio for this age. The cortices presented largely uniform texture with normal echogenic relationship to liver and spleen. Medullary structure differed distinctly from the cortex and no evidence of pelvic dilation was present. The capsules were acceptably uniform without significant irregularities. The left kidney measured 4.11 cm. The right kidney measured 4.0 cm.

**WEIGHT**

23.4 lbs

**ULTRASONOGRAPHIC FINDINGS**

Normal urinary tract.

**INTERPRETED BY**

Eric Lindquist, DMV  
DABVP, Cert. IVUSS

**INTERPRETATION OF THE FINDINGS & FURTHER RECOMMENDATIONS**

There is no evidence of pathology.

**HOSPITAL NAME**

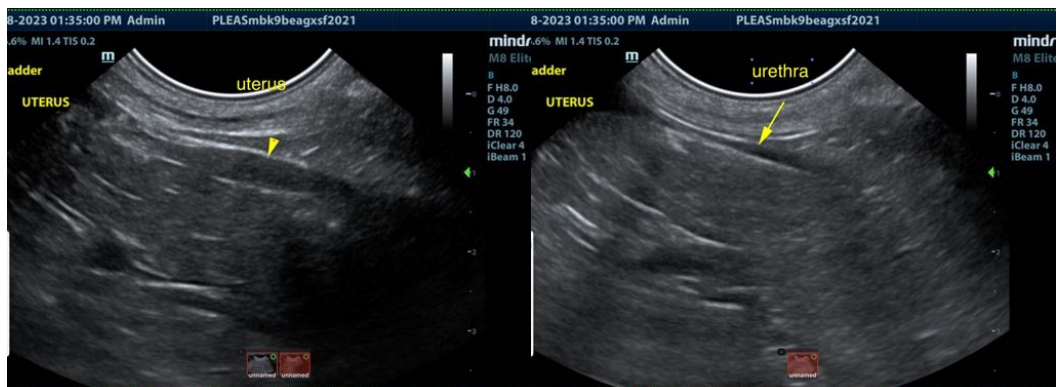
Pleasantville AH

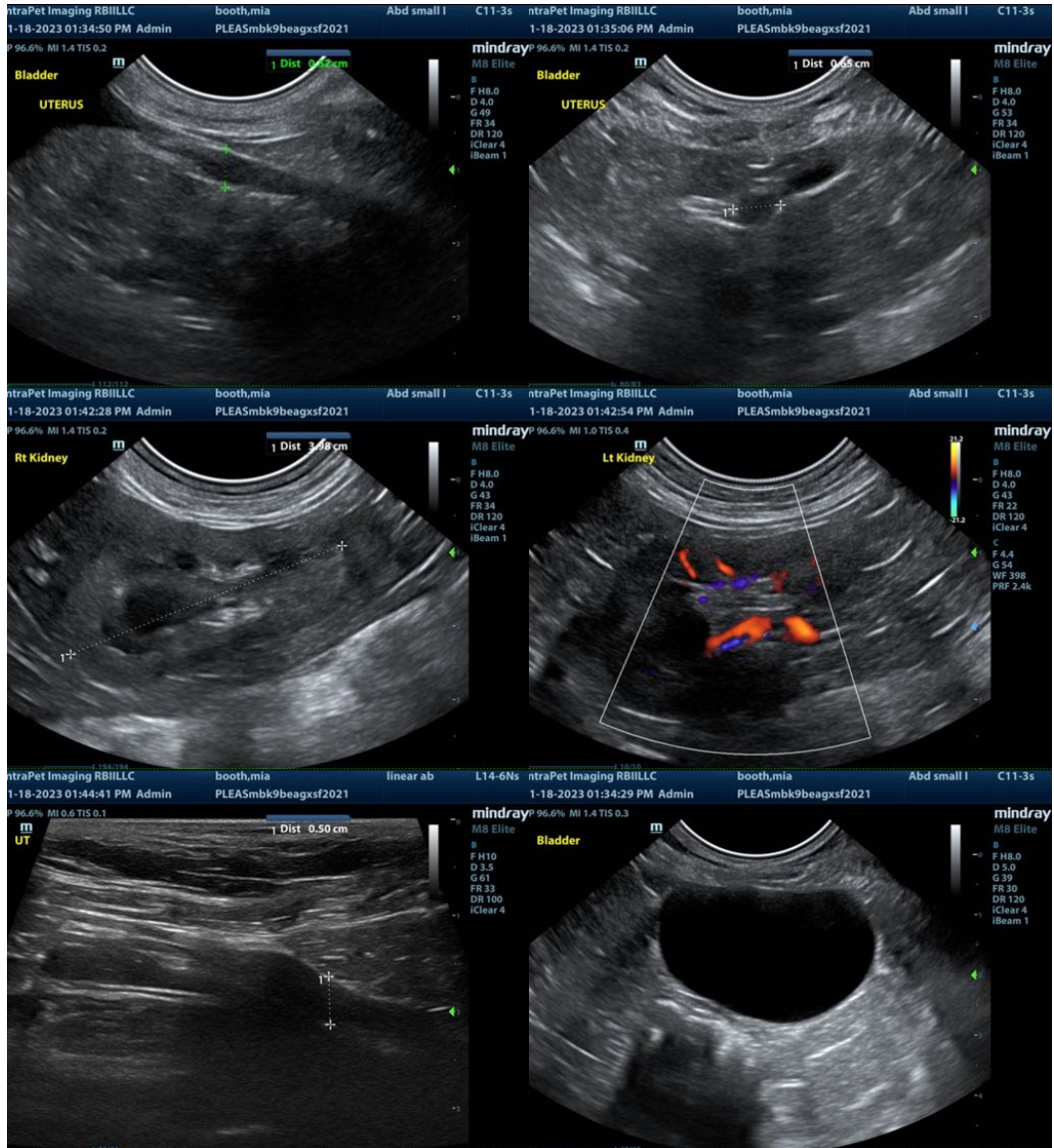
**REFERRING VET**

Dr. Gounaris

**INVOICE**

42233





The information and recommendations provided are based on the images presented by the referring veterinarian. No evaluation can be communicated regarding pathology that was not visible in the image/video clips provided.

Thank you for this referral. If the clinical or image interpretation does not parallel your findings or if I can be of any further assistance please contact me.

**Eric Lindquist, DMV, DABVP, Cert. IVUSS, CEO of SonoPath.com**  
 Eric.Lindquist@SonoPath.com