



PATIENT

Honey Buterbaugh

SPECIES

Canine

BREED

Poodle Mix

SEX

Spayed female

AGE

9 years

WEIGHT

26.4 lbs

PRESENTING CLINICAL SIGNS

History: History of oxalate crystalluria, on cd diet with persistent hematuria and crystals with pH 6.5. Radiographs revealed "subtle multifocal mineral opaque cystic calculi", scan obtained same day to confirm/evaluate.

Abnormal PE/Chem/CBC/UA Results: Normal other than crystalluria.

ULTRASONOGRAPHIC EXAMINATION OF THE ABDOMEN

Urinary System

The **urinary bladder**, trigone, and pelvic urethra presented normal thicknesses and normal tone. The ureters were not visible which is normal. No uroliths or sediment were visualized and anechoic urine was present. No evidence of inflammatory or neoplastic changes was noted. Ureteral papillae were normal.

ULTRASONOGRAPHIC FINDINGS

Normal urinary bladder and pelvic urethra.

INTERPRETATION OF THE FINDINGS & FURTHER RECOMMENDATIONS

There was no evidence of pathology.

INTERPRETED BY

Eric Lindquist, DMV
DABVP, Cert. IVUSS

IMAGING PERFORMED BY

Dr. Lincoski

HOSPITAL NAME

University Drive VH

REFERRING VET

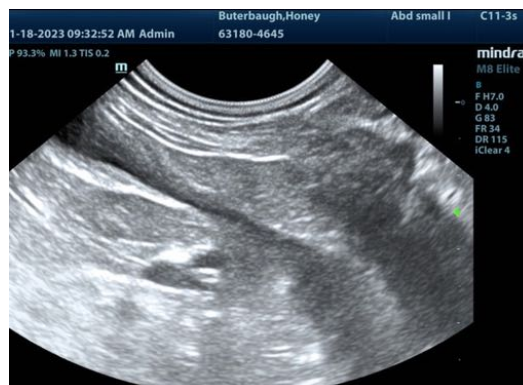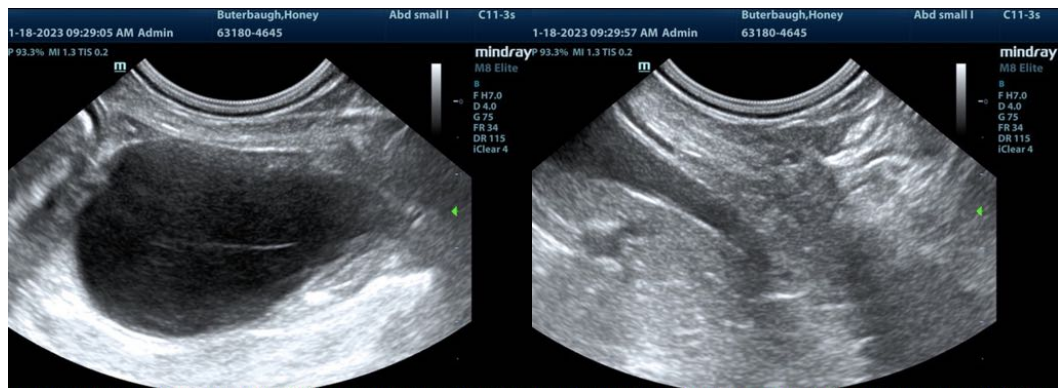
Dr. Lincoski

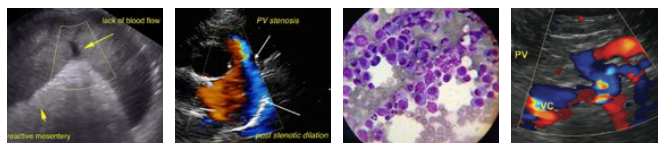
INVOICE

42231

DATE

1/18/23





PATIENT

Honey Buterbaugh

The information and recommendations provided are based on the images presented by the referring veterinarian/sonographer. No evaluation can be communicated regarding pathology that was not visible in the image/video clips provided.

SPECIES

Canine

Thank you for this referral. If the clinical or image interpretation does not parallel your findings or if I can be of any further assistance please contact me.

BREED

Poodle Mix

Eric Lindquist, DMV, DABVP, Cert. IVUSS, CEO of SonoPath.com
info@SonoPath.com

SEX

Spayed female

AGE

9 years

WEIGHT

26.4 lbs

INTERPRETED BY

Eric Lindquist, DMV
DABVP, Cert. IVUSS

**IMAGING
PERFORMED BY**

Dr. Lincoski

HOSPITAL NAME

University Drive VH

REFERRING VET

Dr. Lincoski

INVOICE

42231

DATE

1/18/23