



PATIENT

Gunner Bridge

PRESENTING CLINICAL SIGNS

History: not E/D shaking, lethargic

SPECIES

Canine

ULTRASONOGRAPHIC EXAMINATION OF THE ABDOMEN

Urinary System

BREED

Weimaraner

The **urinary bladder**, trigone, and pelvic urethra presented normal thicknesses and normal tone. The ureters were not visible which is normal. No uroliths or sediment were visualized and anechoic urine was present. No evidence of inflammatory or neoplastic changes was noted. Ureteral papillae were normal.

SEX

Neutered male

The **kidneys** revealed normal size and structure, corticomedullary definition and ratio for this age. The cortices presented largely uniform texture with normal echogenic relationship to liver and spleen. Medullary structure differed distinctly from the cortex and no evidence of pelvic dilation was present. The capsules were acceptably uniform without significant irregularities. The left kidney measured 7.06 cm. The right kidney measured 5.64 cm.

AGE

2 years

WEIGHT

79 lbs

Adrenal Glands

The regions of the **adrenal glands** were imaged with no evidence of pathology.

INTERPRETED BY

Eric Lindquist, DMV
DABVP, Cert. IVUSS

Spleen

The **spleen** presented a smooth homogeneous parenchyma hyperechoic to liver and renal cortical parenchyma. The capsule was smooth without noticeable expansion or deviation from within the spleen or adjacent pathology. The splenic vasculature demonstrated normal volume without signs of congestion or thrombosis. No sonographic evidence of acute or chronic inflammatory, neoplastic, or infarctual changes was noted.

IMAGING PERFORMED BY

Jenn

HOSPITAL NAME

Rockaway

Liver

The **liver** images submitted revealed subjectively normal liver size, contour, and structure. Parenchymal echogenicity was naturally coarse and hypoechoic to the spleen. Vascular and biliary tracts were of normal volume with no evidence of congestion. The gallbladder presented acceptably thin walls with primarily anechoic content. The cystic and common bile ducts were normal. No pathological hepatic lymphadenopathy was evident. No overt structural evidence of inflammatory, infiltrative or regenerative pathology was evident.

REFERRING VET

Dr. Maniar

INVOICE

42203

Gastrointestinal

Examination of the **gastrointestinal tract** revealed a stomach and intestine of normal wall thickness, acceptable curvilinear mural detail, and peristaltic activity. A minor amount of gastric stasis was noted. This is consistent with ileus. Small and large intestine demonstrated normal luminal chyme and stool

DATE

1/17/23



PATIENT

consistency respectively. No obstructive or overt infiltrative disease was noted. No associated abnormal lymphatic activity was noted.

Gunner Bridge

SPECIES

Pancreas

Canine

The base and limbs of the **pancreas** were observed to be largely isoechoic to surrounding omental fat. Pancreatic duct and capsular contour were acceptably normal and parenchyma respected normal curvilinear patterns. No overt evidence of active inflammatory or neoplastic disease was noted.

BREED

Weimaraner

ULTRASONOGRAPHIC EXAMINATION OF THE HEART

SEX

Neutered male

The echocardiogram in this patient demonstrated normal **left atrial** size based on 3 separate methods of LA evaluation. The cranial and caudal **mitral** valve leaflets presented normal linear structure, extension in systole, and union in diastole with normal kinesis. The **left ventricle** presented normal thicknesses with linear contour and was not dilated nor restricted. The **myocardium** presented normal echogenicity without subjective evidence of significant fibrotic or ischemic disease. **Contractility** of the ventricular walls was adequate and in normal range for this patient evidenced by the fractional shortening measurement and subjective evaluation of the different regions of the myocardium. The **left ventricular outflow** tract demonstrated normal laminar flow and subjective structural integrity. The **right atrium** and auricle revealed normal size, structure and content. No evidence of masses was noted. **Tricuspid** valvular assessment demonstrated adequate linear morphology and kinesis. The **right ventricle** was of normal size (1/3 diameter of LV), chordae structure, myocardial echogenicity and thickness. **Pulmonary outflow** tract assessment revealed normal valve structure, laminar flow, and diameter (approx. 1:1 pa/ao ratio). No visible **pericardial** or free pleura fluid was noted. The cranial **mediastinum and pericardial and extra-cardiac regions** were free of masses in the visible window.

AGE

2 years

WEIGHT

79 lbs

INTERPRETED BY

Eric Lindquist, DMV
DABVP, Cert. IVUSS

IMAGING PERFORMED BY

Jenn

HOSPITAL NAME

Rockaway

REFERRING VET

Dr. Maniar

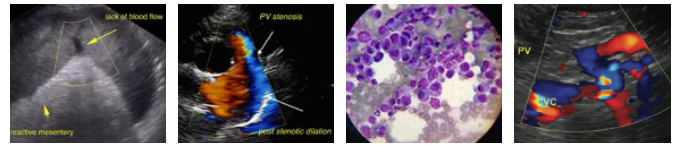
INVOICE

42203

DATE

1/17/23

CANINE	MR	TR	LA/AO	LA/AO	FS	EF	EPSS
CARDIAC PARAMETERS	VMAX (m/s)	VMAX (m/s)	(Boon method)	(Heart Base;)	(%)	(%)	(cm)
NORMAL PARAMETER	4.5-5.5	<2.7	1.3	<1.6	28-40	40-100	<0.6
PATIENT			1.0	1.21	27	53	NM
CANINE	HR	AV	PV	BODY WEIGHT	LA	LVIDd	LVIDs
CARDIAC PARAMETERS	(BPM)	VMAX (m/s)	MAX (m/s)		2D short axis Base view (cm)	Avg; 2D and m-mode short axis (cm)	Avg; 2D and m-mode short axis (cm)
NORMAL PARAMETER	50-100	0.7-1.7	0.7-1.6	BELOW	BELOW	BELOW	BELOW
PATIENT	141	NM	0.9	79 lbs	3.5 max	4.1	



PATIENT

Gunner Bridge

SPECIES

Canine

BREED

Weimaraner

SEX

Neutered male

AGE

2 years

WEIGHT

79 lbs

ULTRASONOGRAPHIC FINDINGS

Normal echocardiogram, no evidence of pathology.

Structurally unremarkable abdomen with minor gastric stasis.

INTERPRETATION OF THE FINDINGS & FURTHER RECOMMENDATIONS

There was no evidence of pathology. Screening for Addison's, assessment for thoracic CNS and orthopedic disease is all indicated as well as assessment of CBC, chem and UA for any metabolic abnormalities.

INTERPRETED BY

Eric Lindquist, DMV
DABVP, Cert. IVUSS

IMAGING PERFORMED BY

Jenn

HOSPITAL NAME

Rockaway

REFERRING VET

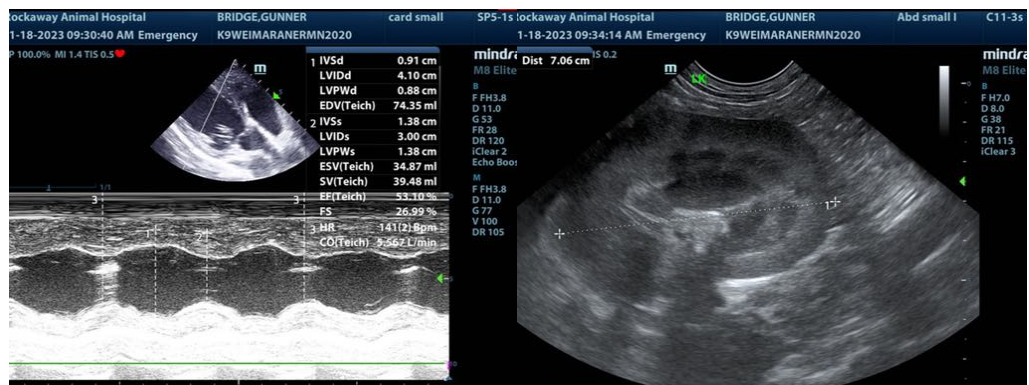
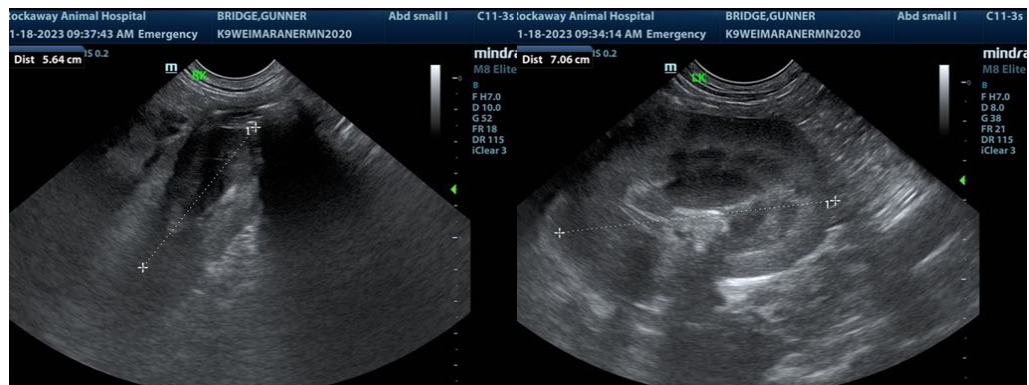
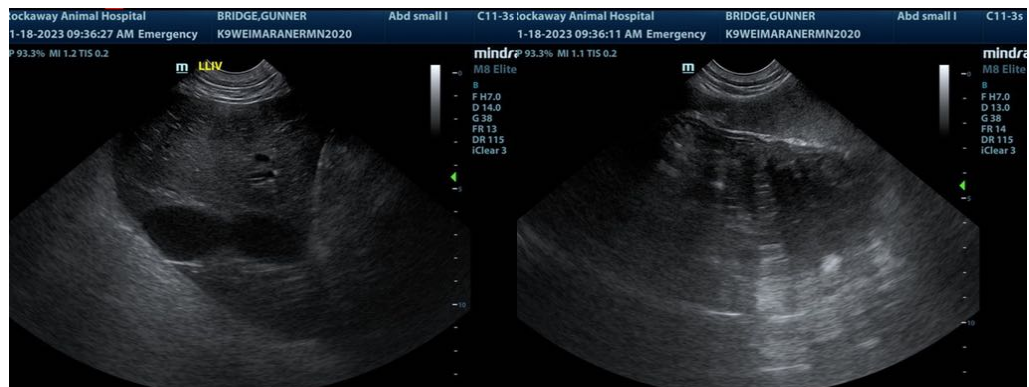
Dr. Maniar

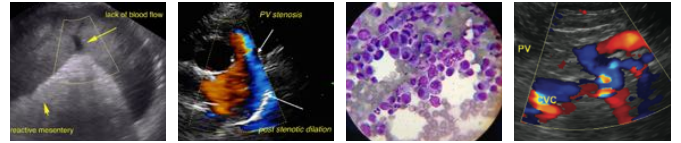
INVOICE

42203

DATE

1/17/23





PATIENT

Gunner Bridge

SPECIES

Canine

BREED

Weimaraner

SEX

Neutered male

AGE

2 years

WEIGHT

79 lbs

INTERPRETED BY

Eric Lindquist, DMV
DABVP, Cert. IVUSS

**IMAGING
PERFORMED BY**

Jenn

HOSPITAL NAME

Rockaway

REFERRING VET

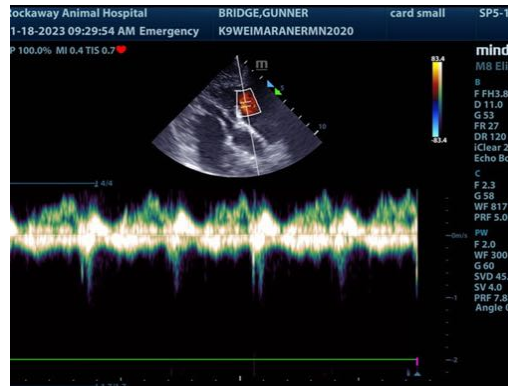
Dr. Maniar

INVOICE

42203

DATE

1/17/23



The information and recommendations provided are based on the images presented by the referring veterinarian/sonographer. No evaluation can be communicated regarding pathology that was not visible in the image/video clips provided.

Thank you for this referral. If the clinical or image interpretation does not parallel your findings or if I can be of any further assistance please contact me.

Eric Lindquist, DMV, DABVP, Cert. IVUSS, CEO of SonoPath.com
info@SonoPath.com