

**PATIENT**

Tako Kas

**SPECIES**

Canine

**BREED**

Shepherd Mix

**SEX**

Neutered male

**AGE**

7 years

**WEIGHT**

61.3 lbs

**INTERPRETED BY**

Eric Lindquist, DMV  
DABVP, Cert. IVUSS

**IMAGING PERFORMED BY**

Kelly Vazquez, CVT

**HOSPITAL NAME**

Summit Dog and Cat  
Hospital

**REFERRING VET**

Dr. Lepkowski

**INVOICE**

95348

**DATE**

1/18/22

**PRESENTING CLINICAL SIGNS**

Elevated liver enzymes. Current meds: Mometamax.  
Abnormal PE/Chem/CBC/UA Results: ALT 248, Alk. Phos. 1,936, T. bili 0.6, glucose 66, cholesterol 382, triglycerides 1,217.

**ULTRASONOGRAPHIC EXAMINATION OF THE ABDOMEN**  
*Urinary System*

The **urinary bladder**, trigone, and pelvic urethra presented normal thicknesses and normal tone. The ureters were not visible which is normal. No uroliths or sediment were visualized and anechoic urine was present. No evidence of inflammatory or neoplastic changes was noted. Ureteral papillae were normal.

The **kidneys** revealed normal size and structure, corticomedullary definition and ratio for this age. The cortices presented largely uniform texture with normal echogenic relationship to liver and spleen. Medullary structure differed distinctly from the cortex and no evidence of pelvic dilation was present. The capsules were acceptably uniform without significant irregularities. The left kidney measured 6.67 cm. The right kidney measured 5.85 cm.

*Adrenal Glands*

Both **adrenal glands** were visualized and recognized as having normal shape, size, position and echogenicity for this breed. The phrenic vasculature, glandular echogenicity and detail were unremarkable. Capsule, cortex, and medullary definition were normal for this age patient. The right adrenal gland measured 1.5 x 0.55 cm at the caudal pole and 0.52 cm at the cranial pole.

*Spleen*

The **spleen** presented a smooth homogeneous parenchyma hyperechoic to liver and renal cortical parenchyma. The capsule was smooth without noticeable expansion or deviation from within the spleen or adjacent pathology. The splenic vasculature demonstrated normal volume without signs of congestion or thrombosis. No sonographic evidence of acute or chronic inflammatory, neoplastic, or infarctual changes was noted.

*Liver*

The **liver** presented heterogenous parenchyma with increased portal markings and coarse architecture. Slight undulating capsular contour was noted. The gallbladder and common bile duct were unremarkable. This is consistent with chronic inflammatory hepatopathy.

*Gastrointestinal*

Examination of the **gastrointestinal tract** revealed a stomach and intestine free of stasis, of normal wall thickness, acceptable curvilinear mural detail, and peristaltic activity. Small and large intestine



**PATIENT**

demonstrated normal luminal chyme and stool consistency respectively. No obstructive or overt infiltrative disease was noted. No associated abnormal lymphatic activity was noted.

Tako Kas

**SPECIES**

**Pancreas**

Canine

The base and limbs of the **pancreas** were observed to be largely isoechoic to surrounding omental fat. Pancreatic duct and capsular contour were acceptably normal and parenchyma respected normal curvilinear patterns. No overt evidence of active inflammatory or neoplastic disease was noted.

**BREED**

Shepherd Mix

**ULTRASONOGRAPHIC FINDINGS**

**SEX**

Non-specific, mild, chronic inflammatory hepatopathy.

Neutered male

**INTERPRETATION OF THE FINDINGS & FURTHER RECOMMENDATIONS**

**AGE**

FNA of the liver can be considered for further definition of inflammatory cell type. Leptospirosis titers are warranted to rule out occult infection. There is no evidence or suspicion of neoplasia.

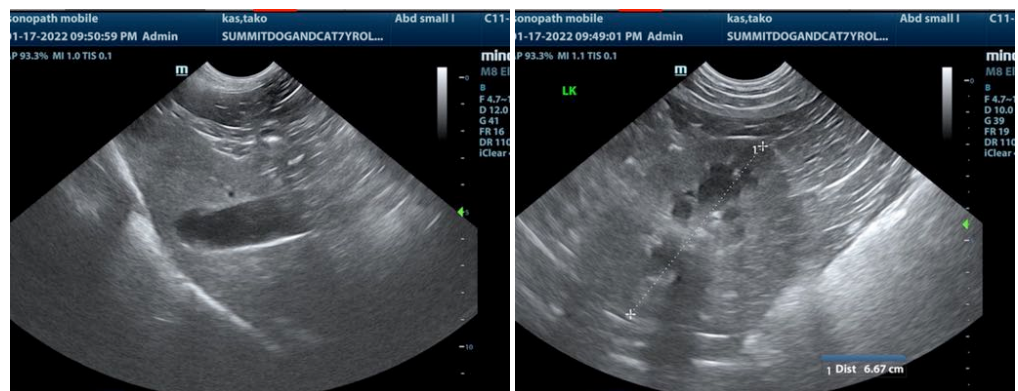
7 years

**WEIGHT**

61.3 lbs

**INTERPRETED BY**

Eric Lindquist, DMV  
DABVP, Cert. IVUSS

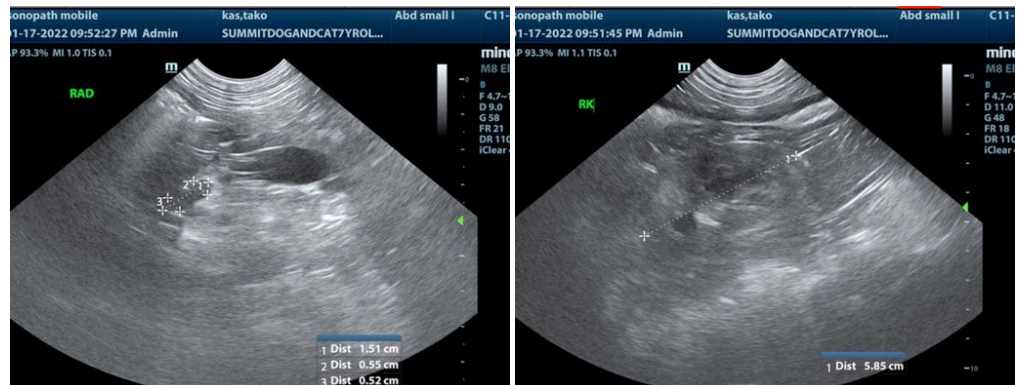


**IMAGING PERFORMED BY**

Kelly Vazquez, CVT

**HOSPITAL NAME**

Summit Dog and Cat  
Hospital



**REFERRING VET**

Dr. Lepkowski

**INVOICE**

95348

**DATE**

1/18/22



**PATIENT**

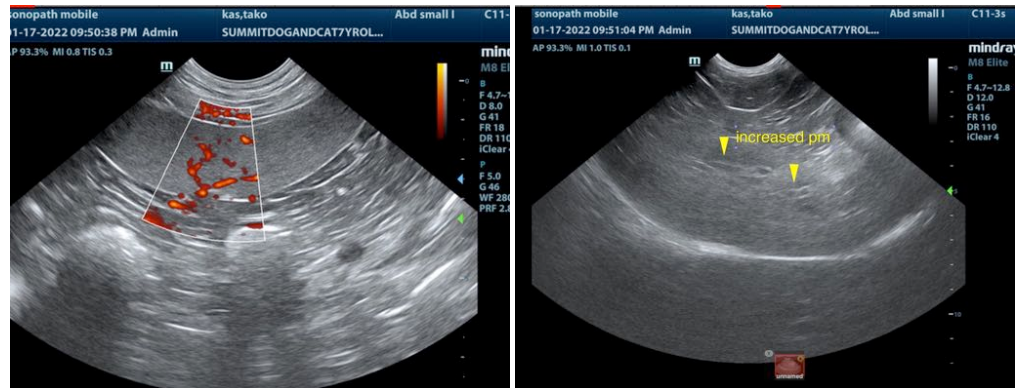
Tako Kas

**SPECIES**

Canine

**BREED**

Shepherd Mix



**SEX**

Neutered male

**AGE**

7 years

**WEIGHT**

61.3 lbs

**INTERPRETED BY**

Eric Lindquist, DMV  
DABVP, Cert. IVUSS

**IMAGING PERFORMED BY**

Kelly Vazquez, CVT

**HOSPITAL NAME**

Summit Dog and Cat  
Hospital

**REFERRING VET**

Dr. Lepkowski

**INVOICE**

95348

**DATE**

1/18/22

The information and recommendations provided are based on the images presented by the referring veterinarian. No evaluation can be communicated regarding pathology that was not visible in the image/video clips provided.

Thank you for this referral. If the clinical or image interpretation does not parallel your findings or if I can be of any further assistance please contact me.

**Eric Lindquist, DMV, DABVP, Cert. IVUSS, CEO of SonoPath.com**  
info@SonoPath.com