

PATIENT

Maggie DePeri

PRESENTING CLINICAL SIGNS

Anorexia.

Increased liver enzymes, increased WBC, decreased TP

SPECIES

Canine

ULTRASONOGRAPHIC EXAMINATION OF THE ABDOMEN

BREED

Beagle Mix

Urinary System

The **urinary bladder**, trigone, and pelvic urethra presented normal thicknesses and normal tone. The ureters were not visible which is normal. No uroliths or sediment were visualized and anechoic urine was present. No evidence of inflammatory or neoplastic changes was noted. Ureteral papillae were normal.

SEX

Spayed Female

AGE

12 ½ years

The **kidneys** revealed largely normal size and structure, corticomedullary definition and ratio (cortex 1/3 of medulla) were essentially maintained with some age-related loss of curvilinear patterns regarding the capsule and C/M junction. The cortices presented largely uniform texture with some increased echogenicity expected for this age patient. Medullary structure differed distinctly from that of the cortex and no evidence of pelvic dilation was present. The left kidney measured 4.73 cm. The right kidney measured 4.0 cm.

INTERPRETED BY

Eric Lindquist, DMV
DABVP, Cert. IVUSS

Adrenal Glands

Both **adrenal glands** were visualized and recognized as having normal shape, size, position and echogenicity for this breed. The phrenic vasculature, glandular echogenicity and detail were unremarkable. Capsule, cortex, and medullary definition were normal for this age patient. The left adrenal gland measured 1.97 x 0.64 cm. The right adrenal gland measured 1.57 x 0.56 cm at the cranial pole and 0.4 cm at the caudal pole.

IMAGING PERFORMED BY

Eric Lindquist, DMV
DABVP, Cert. IVUSS

HOSPITAL NAME

Companion AH

Spleen

The **spleen** presented a smooth homogeneous parenchyma hyperechoic to liver and renal cortical parenchyma. The capsule was smooth without noticeable expansion or deviation from within the spleen or adjacent pathology. The splenic vasculature demonstrated normal volume without signs of congestion or thrombosis. No sonographic evidence of acute or chronic inflammatory, neoplastic, or infarctual changes was noted.

REFERRING VET

Dr. Wolf

INVOICE

95320

Liver

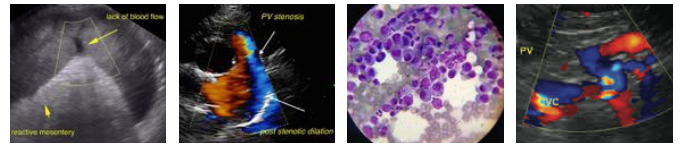
The **liver** revealed mildly increased portal markings and coarse architecture. Hepatic vein dilation and gallbladder edema was noted.

DATE

1/18/22

Gastrointestinal

Examination of the **gastrointestinal tract** revealed a stomach and intestine free of stasis, of normal wall thickness, acceptable curvilinear mural detail, and peristaltic activity. Small and large intestine



PATIENT

Maggie DePeri

demonstrated normal luminal chyme and stool consistency respectively. No obstructive or overt infiltrative disease was noted. No associated abnormal lymphatic activity was noted.

SPECIES

Canine

Pancreas

The base and limbs of the **pancreas** were observed to be largely isoechoic to surrounding omental fat. Pancreatic duct and capsular contour were acceptably normal and parenchyma respected normal curvilinear patterns. No overt evidence of active inflammatory or neoplastic disease was noted.

BREED

Beagle Mix

Free Abdomen

SEX

Spayed Female

There was a trace amount of ascites owing to passive congestion.

AGE

12 ½ years

ULTRASONOGRAPHIC EXAMINATION OF THE HEART

The echocardiogram in this patient revealed a 3.5 x 2.5 cm transmural right auricular/right ventricular free wall mass with pericardial effusion that measured 1.5 cm. Mild tamponade effect was noted upon the right atrium. This obstructed inflow. The mitral valve was slightly vegetative. Extracardiac space revealed multi-focal lung consolidations up to 3.0 x 2.0 cm. Pleural effusion was noted. This is strongly suggestive for thoracic spread.

INTERPRETED BY

Eric Lindquist, DMV
DABVP, Cert. IVUSS

IMAGING PERFORMED BY

Eric Lindquist, DMV
DABVP, Cert. IVUSS

HOSPITAL NAME

Companion AH

REFERRING VET

Dr. Wolf

INVOICE

95320

DATE

1/18/22

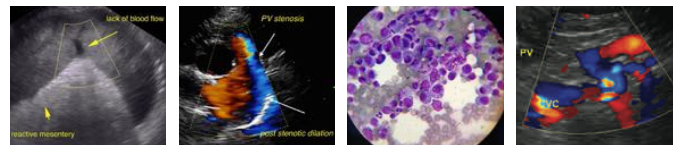
CANINE	MR	TR	LA/AO	LA/AO	FS	EF	EPSS
CARDIAC PARAMETERS	VMAX (m/s)	VMAX (m/s)	(Boon method)	(Heart Base; Swe)	(%)	(%)	(cm)
NORMAL PARAMETER	4.5-5.5	<2.7	1.3	<1.6	28-40	40-100	<0.6
PATIENT			NM	1.4	65	94	NM
CANINE	HR	AV	PV	BODY WEIGHT	LA	LVIDd	LVIDs
CARDIAC PARAMETERS	(BPM)	VMAX (m/s)	MAX (m/s)	(kg)	2D short axis Base view (cm)	Avg; 2D and m-mode short axis (cm)	Avg; 2D and m-mode short axis (cm)
NORMAL PARAMETER	50-100	0.7-1.7	0.7-1.6				
PATIENT					3.0 max	1.92	

ULTRASONOGRAPHIC FINDINGS

Passive congestion pattern with minor remodeling.

Otherwise, geriatric abdominal changes.

Right auricular/right ventricular free wall mass.



PATIENT

Maggie DePeri

SPECIES

Canine

BREED

Beagle Mix

SEX

Spayed Female

AGE

12 ½ years

INTERPRETED BY

Eric Lindquist, DMV
DABVP, Cert. IVUSS

IMAGING PERFORMED BY

Eric Lindquist, DMV
DABVP, Cert. IVUSS

HOSPITAL NAME

Companion AH

REFERRING VET

Dr. Wolf

INVOICE

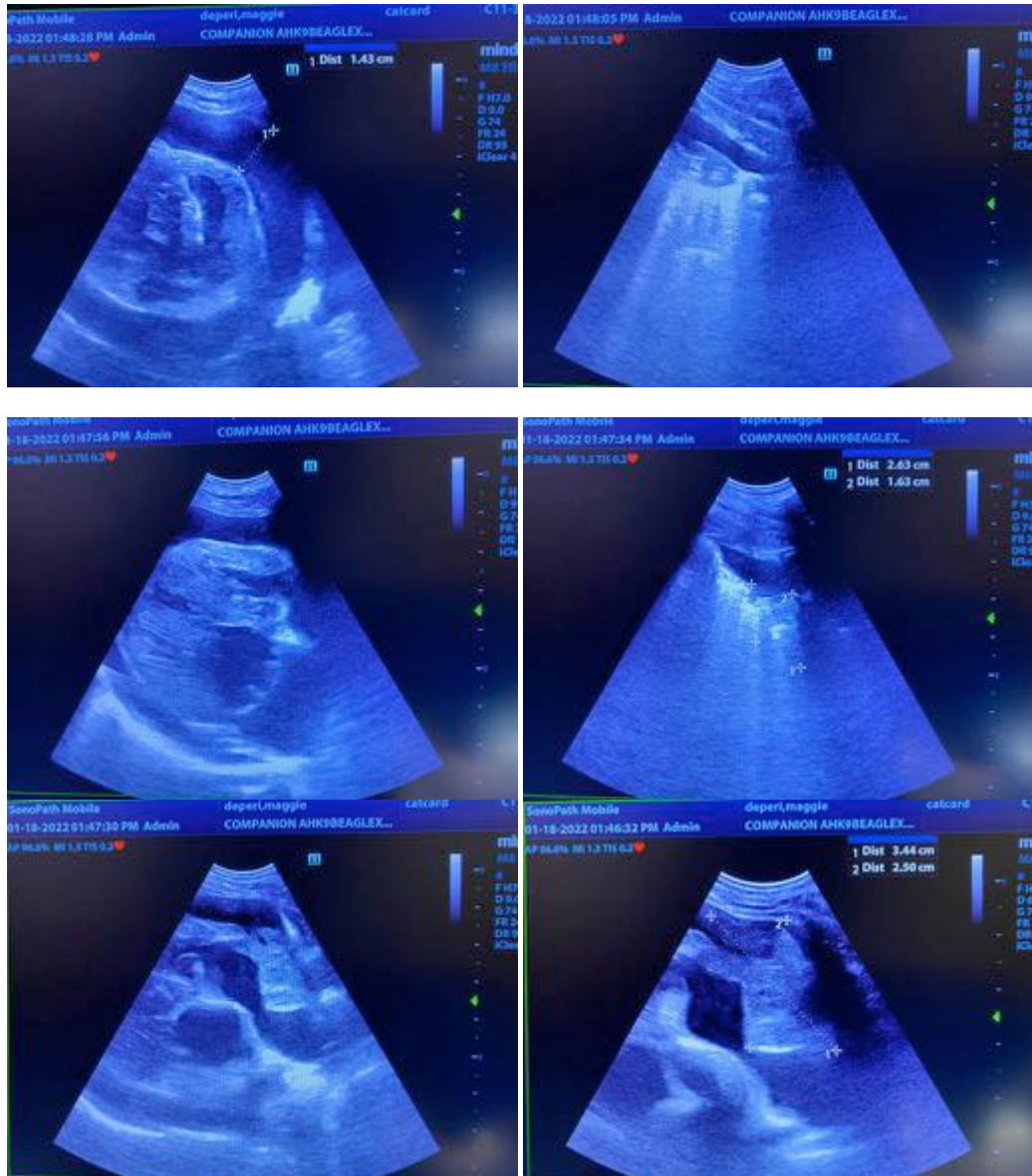
95320

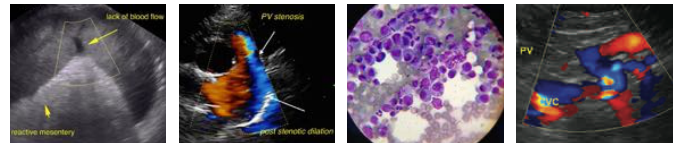
DATE

1/18/22

INTERPRETATION OF THE FINDINGS & FURTHER RECOMMENDATIONS

This is consistent with hemangiosarcoma secondary to pericardial effusion, pleural effusion and lung consolidation with secondary passive congestion.





PATIENT

Maggie DePeri

SPECIES

Canine

BREED

Beagle Mix

SEX

Spayed Female

AGE

12 ½ years

INTERPRETED BY

Eric Lindquist, DMV
DABVP, Cert. IVUS

IMAGING PERFORMED BY

Eric Lindquist, DMV
DABVP, Cert. IVUS

HOSPITAL NAME

Companion AH

REFERRING VET

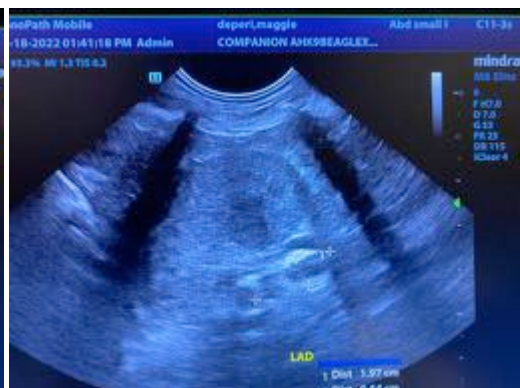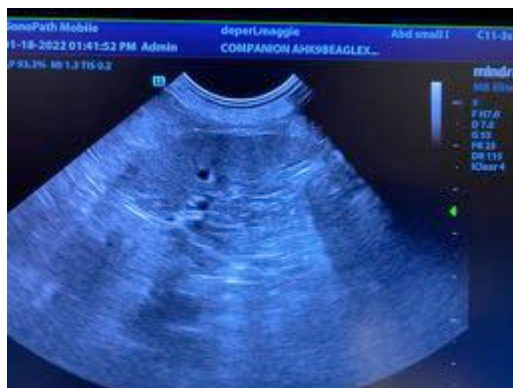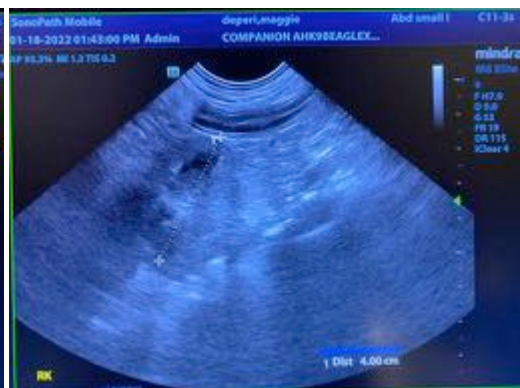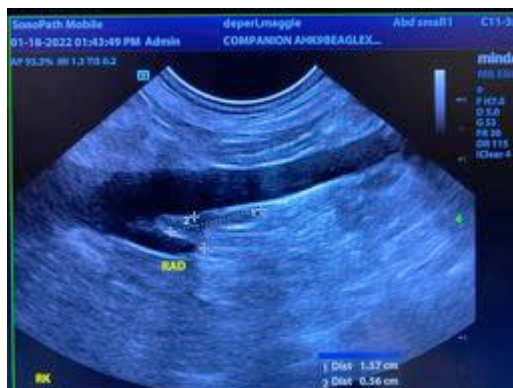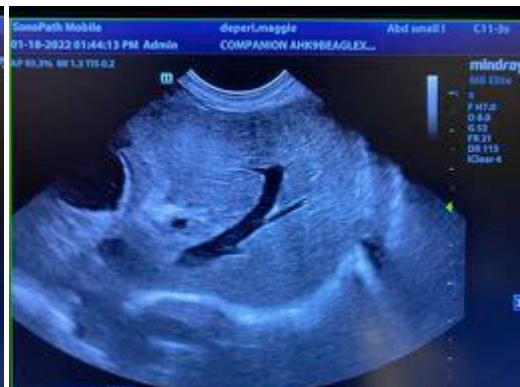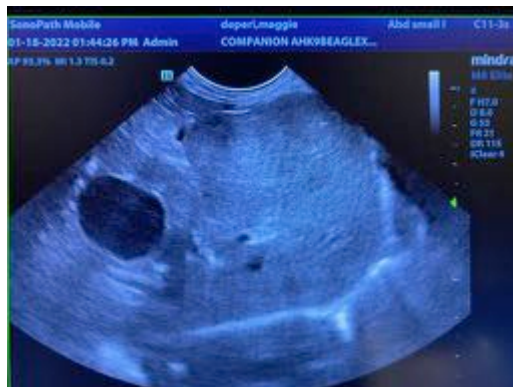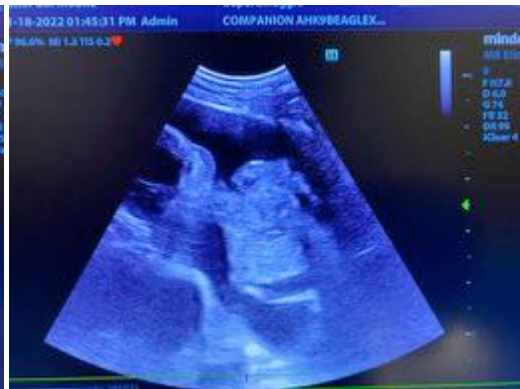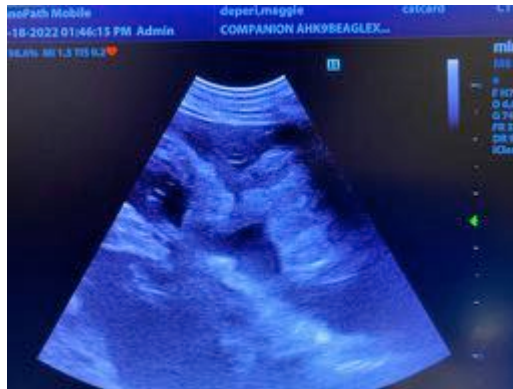Dr. Wolf

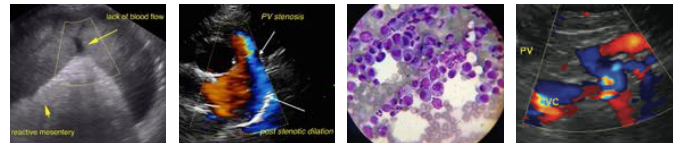
INVOICE

95320

DATE

1/18/22





PATIENT

Maggie DePeri

SPECIES

Canine

BREED

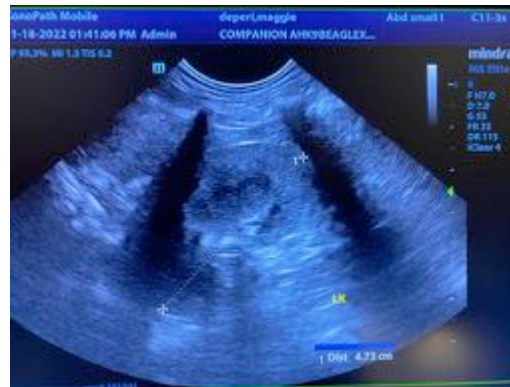Beagle Mix

SEX

Spayed Female

AGE

12 ½ years



The information and recommendations provided are based on the images presented by the referring veterinarian. No evaluation can be communicated regarding pathology that was not visible in the image/video clips provided.

Thank you for this referral. If the clinical or image interpretation does not parallel your findings or if I can be of any further assistance please contact me.

Eric Lindquist, DMV, DABVP, Cert. IVUSS, CEO of SonoPath.com
Info@SonoPath.com

INTERPRETED BY

Eric Lindquist, DMV
DABVP, Cert. IVUSS

Pericardial Effusion and Cardiac Neoplasia

<http://www.sonopath.com/CardiacNeoplasiaEffusion>

IMAGING PERFORMED BY

Eric Lindquist, DMV
DABVP, Cert. IVUSS

HOSPITAL NAME

Companion AH

REFERRING VET

Dr. Wolf

INVOICE

95320

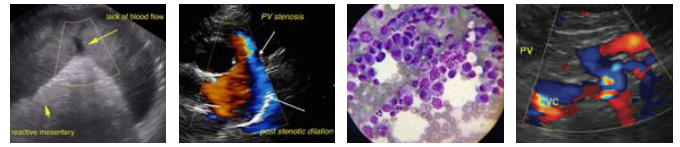
DATE

1/18/22

Description: The pericardium is a fibrous sac that encloses the heart and the great vessels—aorta, pulmonary artery, proximal pulmonary veins, and vena cava—located at the heart’s base. It is attached caudally to the diaphragm and under normal circumstances contains 1-15 mL of fluid. The latter is comprised of phospholipids that lubricate the heart and allow it to expand and contract without generating friction. The pericardium also fixes the heart, prevents excess motion, and links the diastolic distensibility of the ventricles, thus limiting the degree to which either the left or the right ventricle will distend during diastole. When there are acute changes in venous return (i.e., during exercise), the pericardium plays a critical role in limiting ventricular filling. In cases of chronic cardiac enlargement, the pericardium also becomes distended, and its ability to limit ventricular filling, especially when the heart is at rest, becomes compromised. Pericardial tamponade occurs when there is a rapid accumulation of fluid and the pressure inside the pericardium increases significantly. With tamponade, ventricular filling is restricted and cardiac output is decreased. The right atrium and ventricle are the most vulnerable to this condition as these compartments have thinner walls and a lower pressure.

Etiology: Causes of pericardial effusion include:

- Neoplasia



PATIENT

Maggie DePeri

- Right atrial (RA) hemangiosarcoma
- Heart base (aortic body) tumors
- Mesothelioma
- Rhabdomyosarcoma
- Ectopic thyroid carcinoma
- Metastatic neoplasia

SPECIES

Canine

- Idiopathic
- Congestive heart failure
- Peritoneal-pericardial diaphragmatic hernia
- Pericardial cyst
- Hypoalbuminemia
- Infectious pericarditis (bacterial, *Coccidioides immitus*)
- Feline infectious peritonitis
- Left atrial tear secondary to valvular disease
- Coagulopathy

BREED

Beagle Mix

SEX

Spayed Female

AGE

12 ½ years

The majority of neoplastic masses consist of hemangiosarcoma and heart-based tumors (chemodectomas or ectopic thyroid adenocarcinoma). Idiopathic pericardial effusion is a diagnosis of exclusion; the effusion is typically hemorrhagic. Approximately 50% of dogs will be cured with a single pericardiocentesis, while some dogs will require multiple pericardiocenteses as well as surgery. A peritoneal-pericardial diaphragmatic hernia is a congenital hernia seen in dogs and cats in which the abdominal contents (i.e., liver, small intestine, spleen, stomach) herniate into the pericardial sac. Constrictive pericarditis is an uncommon condition in which a non-distensible, thickened, fibrotic pericardium develops over time.

INTERPRETED BY

Eric Lindquist, DMV
DABVP, Cert. IVUSS

IMAGING PERFORMED BY

Eric Lindquist, DMV
DABVP, Cert. IVUSS

Clinical Signs: One will observe the following clinical signs, which often present in combination: ascites, lethargy, exercise intolerance, pale mucous membranes, weak pulses, *pulsus paradoxus*, and respiratory distress.

HOSPITAL NAME

Companion AH

Diagnosics: Survey radiographs will reveal hepatomegaly, cardiomegaly (generalized or sectorial globoid), and small pulmonary vessels. Pulmonary edema is typically not found, although one may discover concurrent pulmonary metastatic disease. An ECG will show electrical alternans or small complexes, but often the changes are very subtle and difficult to detect.

REFERRING VET

Dr. Wolf

INVOICE

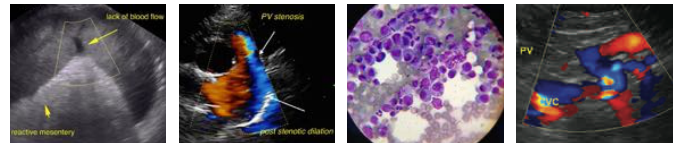
95320

Echocardiography is usually considered the gold standard for diagnosing pericardial effusion. Findings include:

DATE

1/18/22

- Anechoic space between the heart and the pericardium.
- Abnormal side-to-side cardiac motion.
- Decreased chamber size (right ventricle [RV] and left ventricle [LV]).
- Presence of a pericardial or cardiac mass.
- Tamponade with early diastolic RA and RV collapse.



PATIENT

Maggie DePeri

Cytology is helpful in the diagnosis of lymphoma, septic pericarditis, and idiopathic effusion, but not in cases of neoplasia.

SPECIES

Canine

According to a study that found troponin I levels to be higher in dogs with neoplastic pericardial effusion, the cardiac troponin I assay can be helpful in the diagnosis hemangiosarcoma.

BREED

Beagle Mix

Prognosis:

SEX

Spayed Female

- Cardiac hemangiosarcoma: < 8 months with surgical debulking and chemotherapy.
- Chemodectoma (aortic derived): MST 730 days post pericardectomy.
- Idiopathic: 50% complete resolution post cardiocentesis; curative with pericardectomy, which can be done via thoracotomy, or thoracoscopy, or using a balloon to tear the pericardium.
- Mesothelioma: Poor.
- Restrictive pericarditis: Poor, especially when the pericardium has not been surgical stripped.

AGE

12 ½ years

References:

INTERPRETED BY

Eric Lindquist, DMV
DABVP, Cert. IVUSS

Cagle LA, Epstein SE, Owens SD, et al. Diagnostic yield of cytology analysis of pericardial effusion in dogs. *J Vet Int Med* 2014;28:66-71.

IMAGING PERFORMED BY

Eric Lindquist, DMV
DABVP, Cert. IVUSS

Feigenbaum H. Pericardial disease. In: Feigenbaum H, ed. *Echocardiography, 5th ed.* Philadelphia, PA: Lippincott, Williams & Wilkins; 1994:556-588.

HOSPITAL NAME

Companion AH

Jackson J, Richter KP, Launer DP. Thorascopic partial pericardectomy in 13 dogs. *J Vet Int Med* 1999;13:529-33.

REFERRING VET

Dr. Wolf

Johnson MS, Martin M, Binns S. A retrospective study of clinical findings, treatment and outcome in 143 dogs with pericardial effusion. *J Small Anim Prac* 2004;45:546-52.

INVOICE

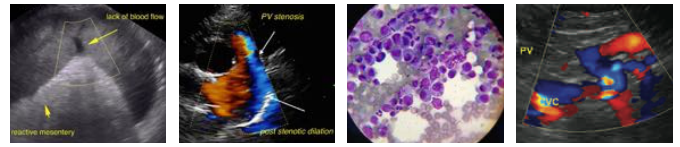
95320

Kienle RD, Thomas WP. Echocardiography. In: Nyland TG and Mattoon JS, eds. *Small Animal Diagnostic Ultrasound, 2nd ed.* Philadelphia, PA: WB Saunders; 2000:354-423.

DATE

1/18/22

Miller MW, Sisson DD. Pericardial disorders. In: Ettinger SJ and Feldman EC, eds. *Textbook of Veterinary Internal Medicine, 5th ed.* Philadelphia, PA: WB Saunders; 2000:923-36.



PATIENT

Maggie DePeri

Rajagopalan V, Jesty SA, Craig LE, et al. Comparison of presumptive echocardiographic and definitive diagnoses of cardiac tumors in dogs. *J Vet Int Med* 2013;27:1092-96.

SPECIES

Canine

Shaw SP, Rozanski EA, Ruhs JE. Cardiac troponins I and T in dogs with pericardial effusion. *J Vet Int Med* 2004;18:322-24.

BREED

Beagle Mix

Sidley JA, Atkins CE, Keene BW, et al. Percutaneous balloon pericardiectomy as a treatment for recurrent pericardial effusion in 6 dogs. *J Vet Intern Med* 2002;16:541.

SEX

Spayed Female

Sisson D, Thomas WP. Pericardial disease and cardiac tumors. In: Fox PR, Sisson D, Moise NS, eds. *Textbook of Canine and Feline Cardiology, 2nd ed.* Philadelphia, PA: WB Saunders; 1999:679-701.

AGE

12 ½ years

Sisson D, Thomas WP, Reed J, et al. Intrapericardial cysts in the dog. *J Vet Int Med* 1993;7:364-69.

INTERPRETED BY

Eric Lindquist, DMV
DABVP, Cert. IVUSS

**IMAGING
PERFORMED BY**

Eric Lindquist, DMV
DABVP, Cert. IVUSS

HOSPITAL NAME

Companion AH

REFERRING VET

Dr. Wolf

INVOICE

95320

DATE

1/18/22