

**PATIENT**

Gucci Metcalf

**SPECIES**

Canine

**BREED**

Boxer

**SEX**

Spayed Female

**AGE**

5 years

**WEIGHT**

34.9 kg

**INTERPRETED BY**

Eric Lindquist, DMV  
DABVP, Cert. IVUSS

**IMAGING PERFORMED BY**

Dr. Markland

**HOSPITAL NAME**

Island Mobile Paws VS

**REFERRING VET**

Central Island VEH

**INVOICE**

95342

**DATE**

1/18/22

**PRESENTING CLINICAL SIGNS**

Inappetent for three days. Seems painful around rear limbs. Mucoïd diarrhea. CBC/Chem/UA showed very high Ca with increased SDMA, Urea, and Creatinine and low usg. Ionized Ca also high. See attached radiographs. FNA samples of the spleen are pending.

Abnormal PE/Chem/CBC/UA Results: 1/17/22: SDMA=21 (0-14) Creatinine=226 (44-159) Urea=14.6 (2.5-9.6) ALT=138 (10-125) Calcium > 4.0 (1.98-3.0) ionized Ca=1.97 (1.25-1.50) usg=1.020

**ULTRASONOGRAPHIC EXAMINATION OF THE ABDOMEN**

**Urinary System**

The **urinary bladder**, trigone, and pelvic urethra presented normal thicknesses and normal tone. The ureters were not visible which is normal. No uroliths or sediment were visualized and anechoic urine was present. No evidence of inflammatory or neoplastic changes was noted. Ureteral papillae were normal.

The **kidneys** revealed multi-focal, hypoechoic target lesions. This is strongly suggestive for metastatic disease. Irregular contour was noted to the right kidney. Corticomedullary definition and renal pelvises were otherwise unremarkable. The right kidney measured 6.63 cm. The left kidney measured 7.1 cm.

**Adrenal Glands**

Both **adrenal glands** were visualized and recognized as having normal shape, size, position and echogenicity for this breed. The phrenic vasculature, glandular echogenicity and detail were unremarkable. Capsule, cortex, and medullary definition were normal for this age patient. The left adrenal gland measured 2.74 x 0.61 cm at the caudal pole and 0.49 cm at the cranial pole.

**Spleen**

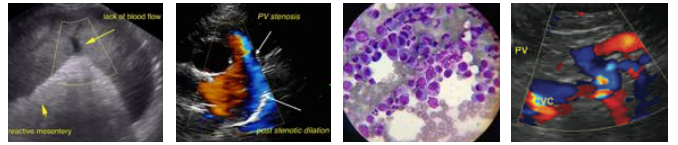
The **spleen** was mildly enlarged with subtle micronodular changes. The splenic vascularity was normal. A more prominent splenic nodule was noted and measured 0.7 cm at the caudal pole.

**Liver**

The **liver** images submitted revealed subjectively normal liver size, contour, and structure. Parenchymal echogenicity was naturally coarse and hypoechoic to the spleen. Vascular and biliary tracts were of normal volume with no evidence of congestion. The gallbladder presented acceptably thin walls with primarily anechoic content. The cystic and common bile ducts were normal. No pathological hepatic lymphadenopathy was evident. No overt structural evidence of inflammatory, infiltrative or regenerative pathology was evident.

**Gastrointestinal**

Examination of the **gastrointestinal tract** revealed a stomach and intestine free of stasis, of normal wall thickness, acceptable curvilinear mural detail, and peristaltic activity. Small and large intestine



**PATIENT**

Gucci Metcalf

demonstrated normal luminal chyme and stool consistency respectively. No obstructive or overt infiltrative disease was noted. No associated abnormal lymphatic activity was noted.

**SPECIES**

Canine

**Pancreas**

The base and limbs of the **pancreas** were observed to be largely isoechoic to surrounding omental fat. Pancreatic duct and capsular contour were acceptably normal and parenchyma respected normal curvilinear patterns. No overt evidence of active inflammatory or neoplastic disease was noted.

**BREED**

Boxer

**Free Abdomen**

**SEX**

Spayed Female

The sublumbar lymph nodes were enlarged and measured up to 1.2 cm in width. A cranial mediastinal mass was noted. The mass is of lymph node origin and measured 8.2 cm.

**AGE**

5 years

**Heart**

Rapid view of the heart revealed no evidence of pathology. The contractility and size was normal.

**WEIGHT**

34.9 kg

**ULTRASONOGRAPHIC FINDINGS**

Multi-centric lymphadenopathy.

Cranial mediastinal lymph node mass.

**INTERPRETED BY**

Eric Lindquist, DMV  
DABVP, Cert. IVUSS

**INTERPRETATION OF THE FINDINGS & FURTHER RECOMMENDATIONS**

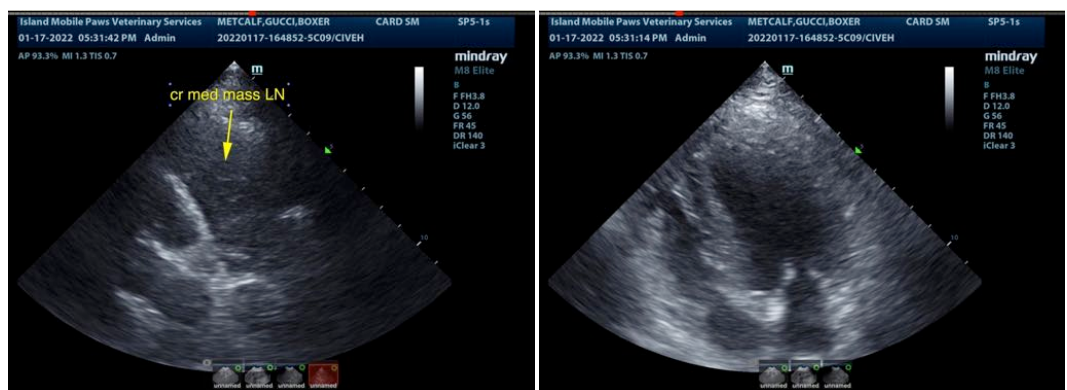
Ultrasound-guided FNA of the cranial mediastinal mass is recommended. Multi-centric round cell neoplasia/lymphoma is suspected involving the lymph nodes, probable spleen, probable renal cortices and cranial mediastinum.

**IMAGING PERFORMED BY**

Dr. Markland

**HOSPITAL NAME**

Island Mobile Paws VS



**REFERRING VET**

Central Island VEH

**INVOICE**

95342

**DATE**

1/18/22



**PATIENT**

Gucci Metcalf

**SPECIES**

Canine

**BREED**

Boxer

**SEX**

Spayed Female

**AGE**

5 years

**WEIGHT**

34.9 kg

**INTERPRETED BY**

Eric Lindquist, DMV  
DABVP, Cert. IVUS

**IMAGING PERFORMED BY**

Dr. Markland

**HOSPITAL NAME**

Island Mobile Paws VS

**REFERRING VET**

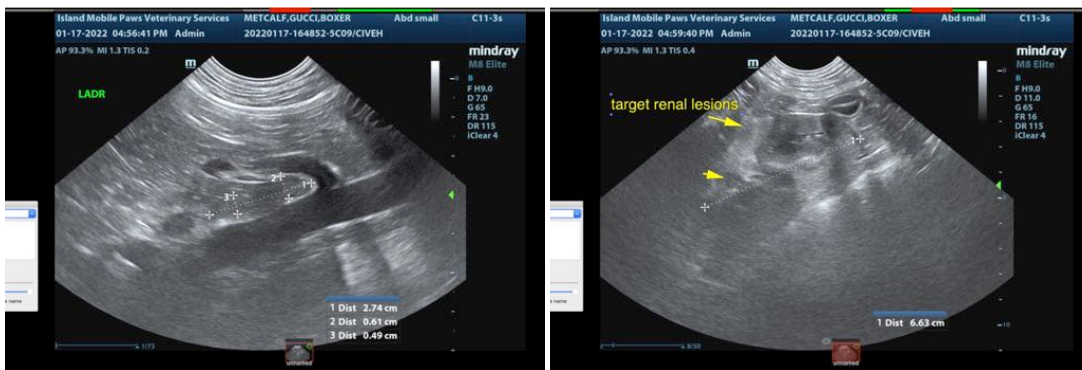
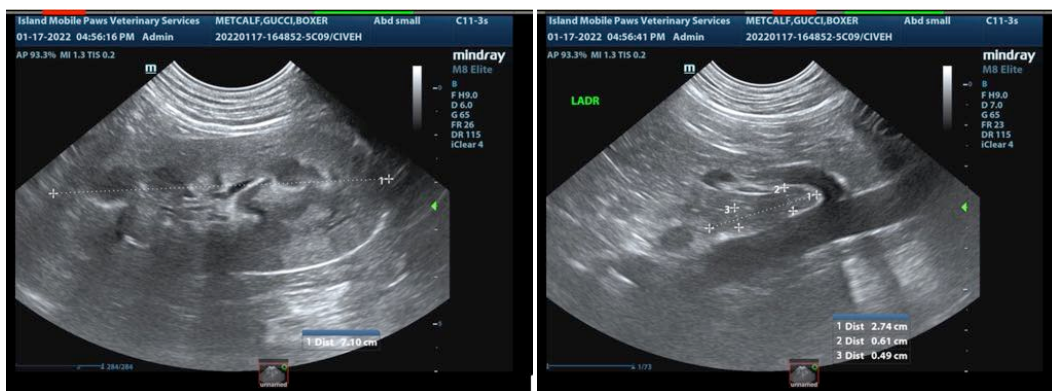
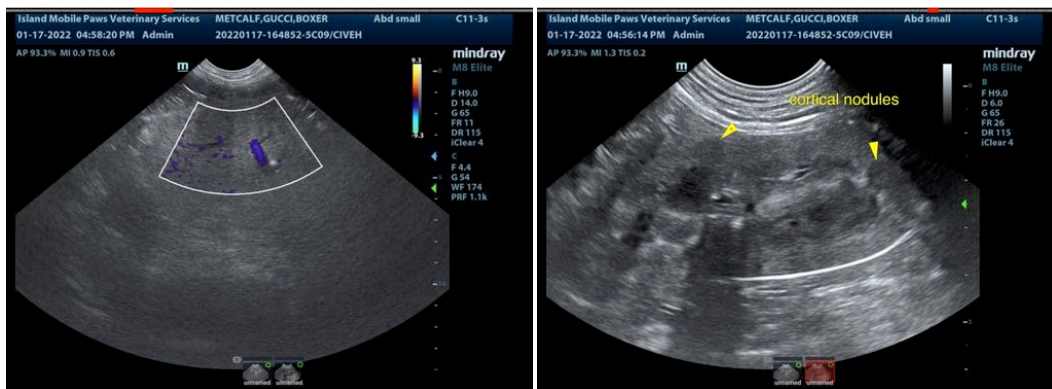
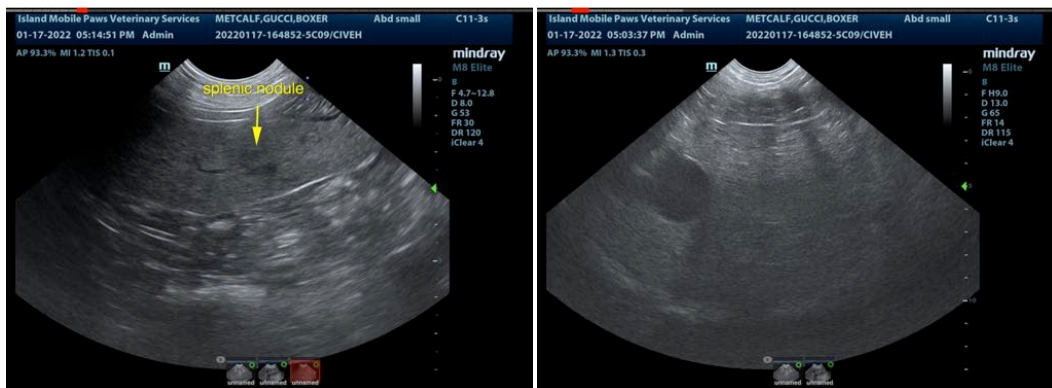
Central Island VEH

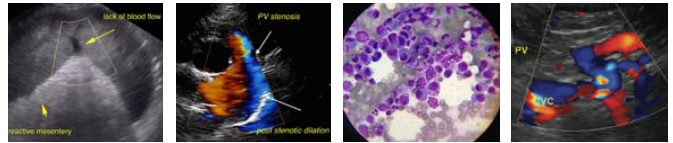
**INVOICE**

95342

**DATE**

1/18/22





**PATIENT**

Gucci Metcalf

**SPECIES**

Canine

**BREED**

Boxer

**SEX**

Spayed Female

**AGE**

5 years

**WEIGHT**

34.9 kg

**INTERPRETED BY**

Eric Lindquist, DMV  
DABVP, Cert. IVUSS

**IMAGING PERFORMED BY**

Dr. Markland

**HOSPITAL NAME**

Island Mobile Paws VS

**REFERRING VET**

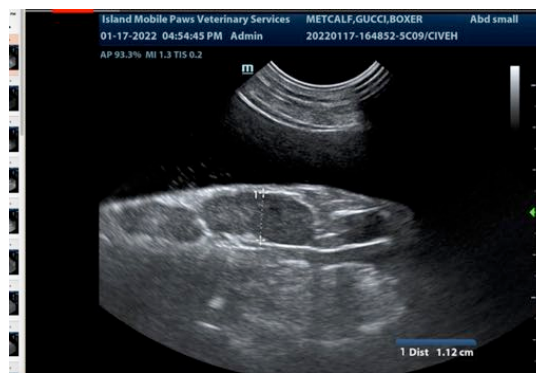
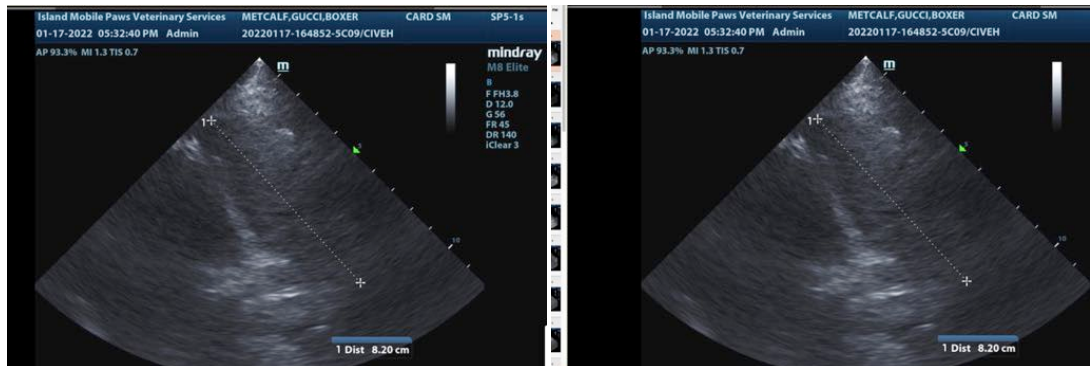
Central Island VEH

**INVOICE**

95342

**DATE**


1/18/22



The information and recommendations provided are based on the images presented by the referring veterinarian. No evaluation can be communicated regarding pathology that was not visible in the image/video clips provided.

Thank you for this referral. If the clinical or image interpretation does not parallel your findings or if I can be of any further assistance please contact me.

Eric Lindquist, DMV, DABVP, Cert. IVUSS, CEO of SonoPath.com  
[info@SonoPath.com](mailto:info@SonoPath.com)



The following is an applicable excerpt from the *Curbside Guide to Diagnosis & Treatment of Sonographic Disease* offered by [SonoPath.com](http://SonoPath.com) Lindquist, Frank, Lobetti, and Modler.

An essential quick guide for every general practitioner and sonographer.

<https://sonopath.com/products/curbside-guide-editing-due-release-12012015>

**CANINE HYPERCALCEMIA**

<http://www.sonopath.com/CanineHypercalcemia>



**PATIENT**

Gucci Metcalf

**SPECIES**

Canine

**BREED**

Boxer

**SEX**

Spayed Female

**AGE**

5 years

**WEIGHT**

34.9 kg

**INTERPRETED BY**

Eric Lindquist, DMV  
DABVP, Cert. IVUSS

**IMAGING PERFORMED BY**

Dr. Markland

**HOSPITAL NAME**

Island Mobile Paws VS

**REFERRING VET**

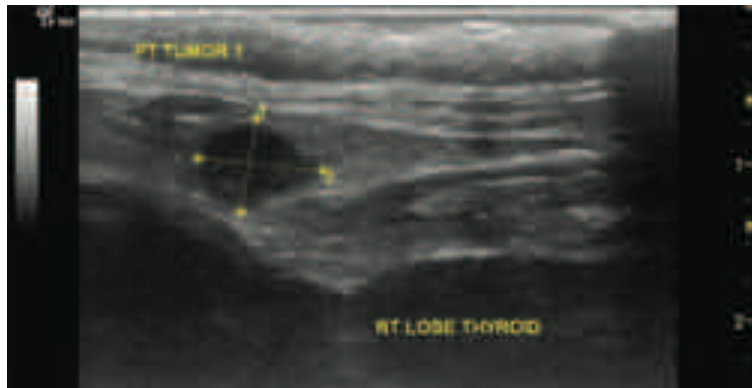
Central Island VEH

**INVOICE**

95342

**DATE**

1/18/22



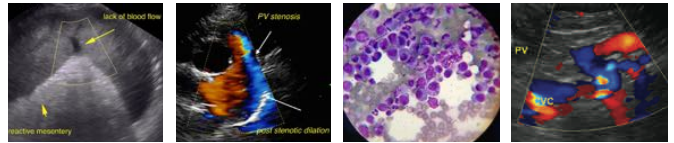
Long axis of the right thyroid lobe in a dog with a parathyroid adenoma. The right internal parathyroid gland (between calipers) shows severe uniform enlargement of more than 7mm.

**Description:** Hypercalcemia is defined as either a persistently elevated total calcium serum (> 12 mg/dl) or ionized calcium (> 1.45 mmol/l) concentration. Clinical signs are often absent with mild hypercalcemia (< 13 mg/dl). In fact, hypercalcemia is often only discovered when serum biochemistry is done for unrelated reasons. Clinical signs are usually mild when the serum calcium concentration is less than 14 mg/dl; however, signs become more readily apparent when the concentration exceeds 15 mg/dl. Life-threatening cardiac arrhythmias can develop when the serum calcium exceeds 18 mg/dl.

Common etiologies of hypercalcemia include humoral hypercalcemia of malignancy (HHM), hypoadrenocorticism, chronic kidney disease (CKD), hypervitaminosis D, and primary hyperparathyroidism. Less common etiologies include bone neoplasia, osteomyelitis, hypertrophic osteodystrophy, granulomatous disease, calcium supplementation, and oral phosphate binders.

**Clinical Signs:** Common clinical signs include polyuria, polydipsia, lethargy, inappetence, and weakness. With chronic hypercalcemia, calcium oxalate and calcium phosphate uroliths can form, resulting in clinical signs suggestive of lower urinary tract disease. Systemic signs of illness are suggestive of HHM.

**Diagnostics:** One important etiology of hypercalcemia is laboratory error; therefore, hypercalcemia should always be confirmed before embarking on any further diagnostic evaluation. Results of a CBC, serum biochemistry panel, and urinalysis, in conjunction with a patient history and findings from a physical examination, can often provide enough information to arrive at a diagnosis. The appendicular skeleton, peripheral lymph nodes, abdominal cavity, and rectum should all be carefully palpated for masses, lymphadenopathy, hepatomegaly, splenomegaly, and/or pain in the long bones. The following diagnostic tests are helpful for identifying an underlying malignancy: thoracic and abdominal radiographs; abdominal ultrasound; cytological evaluation of aspirates of the liver, spleen, lymph nodes, and bone marrow; determination of serum ionized calcium, parathyroid hormone (PTH), and parathyroid hormone-related protein concentration (PTHrP); and ultrasound of the neck. Ascertaining the concentrations of serum ionized calcium, PTH, and PTHrP helps differentiate primary hyperparathyroidism from HHM. The finding of one or more enlarged parathyroid glands upon conducting an ultrasound of the neck supports a diagnosis of primary hyperparathyroidism.



**PATIENT**

Gucci Metcalf

Hypoadrenocorticism-induced hypercalcemia usually occurs in conjunction with hyponatremia, hyperkalemia, and prerenal azotemia. With HHM and primary hyperparathyroidism, serum phosphorus concentration is often in the low to low-normal reference range. If the serum phosphorus concentration is high but kidney function is normal, hypervitaminosis D or osteolysis should be suspected.

**SPECIES**

Canine

It can be difficult to determine whether kidney failure is primary or secondary to hypercalcemia when hyperphosphatemia and hypercalcemia coexist with azotemia. Serum ionized calcium concentrations are typically normal or decreased in cases of renal failure and increased in cases of hypercalcemia caused by other disorders.

**BREED**

Boxer

**SEX**

Spayed Female

Sternal and hilar lymphadenopathy is common with lymphoma-induced hypercalcemia and can be readily identified on thoracic radiographs. In cases of multiple myeloma, discrete lytic lesions in the vertebrae or long bones, hyperproteinemia, proteinuria, and plasma cell infiltration in the bone marrow may be present. Cytological evaluation of the peripheral lymph nodes, bone marrow, and spleen can be helpful in identifying lymphoma.

**AGE**

5 years

Increased serum ionized calcium concentrations, detectable serum PTHrP concentrations, and non-detectable serum PTH concentrations are all diagnostic for HHM. Lymphoma is the most common etiology of HHM, but other tumors, such as apocrine gland adenocarcinoma and various carcinomas (e.g. mammary gland, squamous cell, bronchogenic), can all give rise to hypercalcemia. Increased serum ionized calcium, normal to increased serum PTH, and non-detectable PTHrP concentrations are diagnostic of primary hyperparathyroidism.

**WEIGHT**

34.9 kg

**INTERPRETED BY**

Eric Lindquist, DMV  
DABVP, Cert. IVUSS

**Differentials for Hypercalcemia: "HARD IONS"**

**IMAGING PERFORMED BY**

Dr. Markland

Hyperparathyroid

Addison's

Renal

**HOSPITAL NAME**

Island Mobile Paws VS

D-toxicity

Idiopathic

**REFERRING VET**

Central Island VEH

Osteolytic

Neoplastic

Spurious

**INVOICE**

95342

**PTH tumor:** Elevated total and ionized Ca, low PTHrP, and normal/high PTH. Keeshonds, German Shepherds, and Golden Retrievers are all predisposed.

**DATE**

1/18/22

**Addison's disease:** Elevated total and normal ionized Ca, elevated BUN, hypoalbuminemia and hyperkalemia.



**PATIENT**

Gucci Metcalf

**Renal failure:** Elevated to normal total Ca, low ionized Ca, low PTHrP, elevated PTH, azotemia, and low urine specific gravity.

**Vitamin D toxicity:** Elevated total and ionized Ca, low PTHrP, and normal/low PTH.

**SPECIES**

Canine

**Hypercalcemia of malignancy (HHM):** Elevated total and ionized Ca, high PTHrP, and low PTH.

**Granulomatous disease:** Elevated total and ionized Ca, low PTHrP, and low PTH.

**BREED**

Boxer

**Renal failure:** Elevated to normal total Ca, low ionized Ca, low PTHrP, elevated PTH, azotemia, and low urine specific gravity.

**SEX**

Spayed Female

**Treatment:** Therapies for hypercalcemia are aimed at correcting the underlying etiology; however, because prolonged hypercalcemia can result in kidney damage, the use of fluid therapy, furosemide, and possibly prednisone is indicated in all cases to reduce serum calcium levels. Suggested dosages include saline (0.9% 120-180 ml/kg day IV), furosemide (1-4 mg/kg PO TID), and prednisone (0.25 mg/kg PO Q24hr).

**AGE**

5 years

**WEIGHT**

34.9 kg

**INTERPRETED BY**

Eric Lindquist, DMV  
DABVP, Cert. IVUSS

**IMAGING PERFORMED BY**

Dr. Markland

**HOSPITAL NAME**

Island Mobile Paws VS

**REFERRING VET**

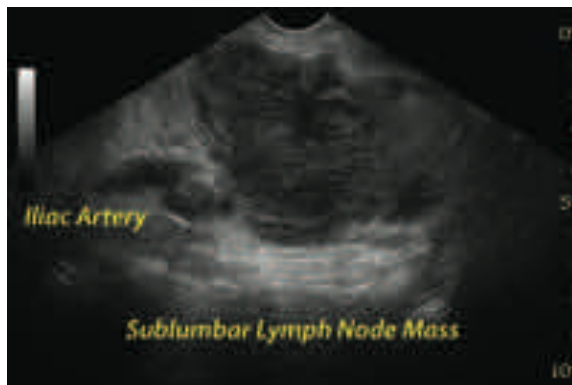
Central Island VEH

**INVOICE**

95342

**DATE**

1/18/22



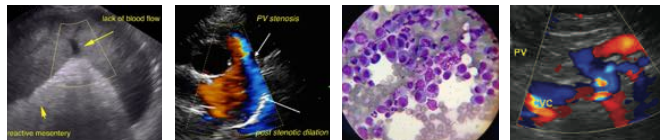
Long axis of the left hypogastric lymph node in a hypercalcemic dog with lymphoma and hypercalcemia of malignancy. The lymph node is severely enlarged and rounded with a short-to-long-axis ratio > 0.5 indicating malignant infiltration. The regular echoarchitecture is lost, the hilus is not recognized, lymph node parenchyma is hypochoic and heterogenous. Also note the mass effect on the external iliac artery. In light of hypercalcemia, lymphadenopathy in this region could also be owing to anal gland adenocarcinoma which can also be imaged sonographically.

**References:**

Chew DJ, Schenck PA, Jaeger JQ. Clinical disorders of hypercalcemia and hypocalcemia in dogs and cats. Proceedings from the American College of Veterinary Internal Medicine, Charlotte, NC, June 4-7, 2003.

Feldman EC. Disorders of the parathyroid glands. In: Ettinger SJ, Feldman EC, ed. *Textbook of Veterinary Internal Medicine, 7th ed.* St. Louis, MO: Saunders Elsevier; 2010:1722-50.

Peterson ME. Hypercalcemia in dogs & cats: differential diagnosis & treatment. Proceedings from the Western Veterinary Conference, Las Vegas, NV, February 19-23, 2012.



**PATIENT**

Gucci Metcalf

**SPECIES**

Canine

**BREED**

Boxer

**SEX**

Spayed Female

**AGE**

5 years

**WEIGHT**

34.9 kg

**INTERPRETED BY**

Eric Lindquist, DMV  
DABVP, Cert. IVUSS

**IMAGING  
PERFORMED BY**

Dr. Markland

**HOSPITAL NAME**

Island Mobile Paws VS

**REFERRING VET**

Central Island VEH

**INVOICE**

95342

**DATE**

1/18/22