



PATIENT PRESENTING CLINICAL SIGNS

Captain Luckner Heart murmur grade IV/VI, abnormal, getting louder. No current meds reported. Needs dental.

SPECIES ULTRASONOGRAPHIC EXAMINATION OF THE HEART

Canine

BREED

Cavalier King Charles

SEX

Neutered male

AGE

4 years

WEIGHT

19.7 lbs

INTERPRETED BY

Eric Lindquist, DMV
DABVP, Cert. IVUSS

IMAGING PERFORMED BY

Kelly Vazquez, CVT

HOSPITAL NAME

Summit Dog and Cat
Hospital

REFERRING VET

Dr. Lepkowski

The echocardiogram in this patient demonstrated normal **left atrial** size based on 3 different LA measurement methods. Chamber volumes and echogenicity were normal. The cranial and caudal **mitral** valve leaflets presented vegetative thickening consistent with endocardiosis. Doppler indicated measurable insufficiency. The **left ventricle** presented thicknesses with linear contour and was not dilated nor restricted. The **myocardium** presented normal echogenicity without subjective evidence of significant fibrotic or ischemic disease. **Contractility** of the ventricular walls was adequate and in normal range for this patient evidenced by the fractional shortening measurement and subjective evaluation of the different regions of the myocardium. The **left ventricular outflow** tract demonstrated normal laminar flow and subjective structural integrity. The **right atrium** and auricle revealed normal size, structure and content. No evidence of masses was noted or chamber overload. **Tricuspid** valvular assessment demonstrated adequate linear morphology. The **right ventricle** was of normal size (1/3 diameter of LV), chordae structure, myocardial echogenicity and thickness. **Pulmonic** tract assessment revealed normal valve structure, laminar flow, and diameter (approx. 1:1 pa/ao ratio). No visible **pericardial** or free pleura fluid was noted. No echographically detectable evidence of infiltrative disease was visible. The cranial **mediastinum and pericardial regions** were free of masses in the visible window.

CANINE CARDIAC PARAMETERS	MR VMAX (m/s)	TR VMAX (m/s)	LA/AO (Boon method)	LA/AO (Heart Base; Swe)	FS (%)	EF (%)	EPSS (cm)
NORMAL PARAMETER	4.5-5.5	<2.7	1.3	<1.6	28-40	40-100	<0.6
PATIENT	6.0		1.2	1.2	30	60	NM
CANINE CARDIAC PARAMETERS	HR (BPM)	AV VMAX (m/s)	PV MAX (m/s)	BODY WEIGHT	LA 2D short axis Base view (cm)	LVIDd Avg; 2D and m- mode short axis (cm)	LVIDs Avg; 2D and m- mode short axis (cm)
NORMAL PARAMETER	50-100	0.7-1.7	0.7-1.6				
PATIENT	140	1.51	0.94	19.7 lbs	2.29 max	2.72	

INVOICE

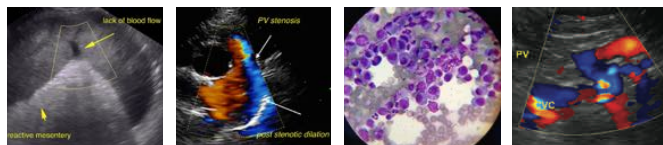
95346

DATE

1/18/22

ULTRASONOGRAPHIC FINDINGS

Stage B1 valvular disease.



PATIENT

Captain Luckner

SPECIES

Canine

BREED

Cavalier King Charles

SEX

Neutered male

AGE

4 years

WEIGHT

19.7 lbs

INTERPRETED BY

Eric Lindquist, DMV
DABVP, Cert. IVUSS

IMAGING PERFORMED BY

Kelly Vazquez, CVT

HOSPITAL NAME

Summit Dog and Cat
Hospital

REFERRING VET

Dr. Lepkowski

INVOICE

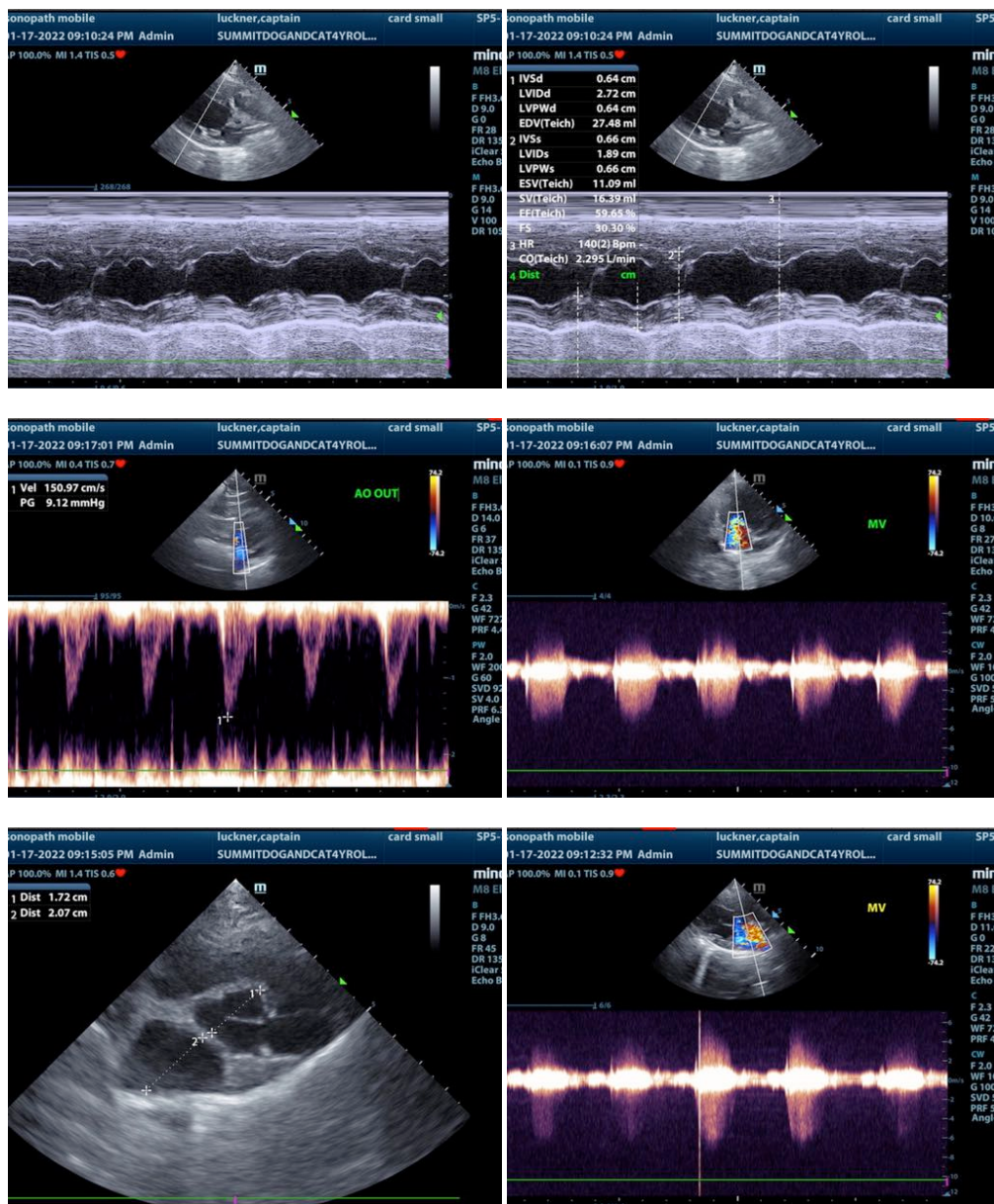
95346

DATE

1/18/22

INTERPRETATION OF THE FINDINGS & FURTHER RECOMMENDATIONS

B1: The heart is stable without clinical disease. No overt contraindication for anesthesia of brief to moderate duration. I suggest Torbutrol premed, Propofol induction, Isoflurane maintenance or similar protocol if anesthesia is desired. Blood pressure recommended if not already performed and target white coat negative systolic pressure of < 160 mmHg. If higher than this ACE-inhibitor is suggested to reach this level. Recheck echocardiogram is recommended in 6 months, earlier if murmur grade increases or clinical signs initiate.





PATIENT

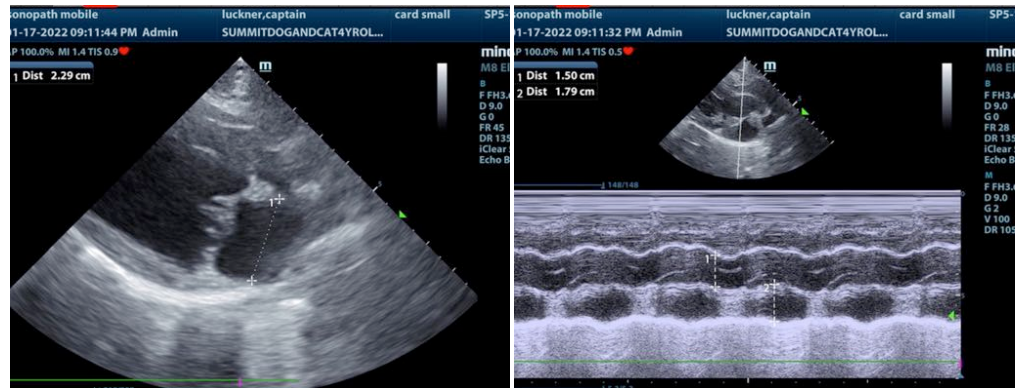
Captain Luckner

SPECIES

Canine

BREED

Cavalier King Charles



SEX

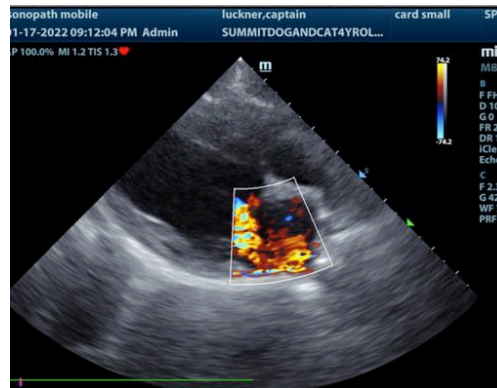
Neutered male

AGE

4 years

WEIGHT

19.7 lbs



INTERPRETED BY

Eric Lindquist, DMV
DABVP, Cert. IVUSS

The information and recommendations provided are based on the images presented by the referring veterinarian. No evaluation can be communicated regarding pathology that was not visible in the image/video clips provided.

Thank you for this referral. If the clinical or image interpretation does not parallel your findings or if I can be of any further assistance please contact me.

IMAGING PERFORMED BY

Kelly Vazquez, CVT

Eric Lindquist, DMV, DABVP, Cert. IVUSS, CEO of SonoPath.com
info@SonoPath.com

HOSPITAL NAME

Summit Dog and Cat
Hospital

REFERRING VET

Dr. Lepkowski

INVOICE

95346

DATE

1/18/22