



**DATE PRESENTING CLINICAL SIGNS**

01/17/26

**PATIENT**

Penelope Schrader

**SPECIES**

Canine

**BREED**

Weimaraner

**SEX**

Spayed Female

**AGE**

01/16/17

**WEIGHT**

24.6 kg

**INTERPRETED BY**

Eric Lindquist, DMV,  
DABVP(CFM), Cert.  
IVUSS

**HOSPITAL NAME**

Mason Dixon Animal  
Emergency

**REFERRING VET**

Dr. McCarty

**INVOICE**

13202

Patient History: Inappetence  
Gastroenteritis r/o FBO vs neoplasia vs Addison's vs other Heart murmur (Hx)  
Cleft palate/lip (Hx)  
Mydriasis (Hx)  
rotary nystagmus (Hx)

Current Medications: N/A.  
Labwork Results: Labwork submitted.  
Date of Previous IntraPet Ultrasound: No previous.  
Sedation: Propofol.  
Stat Report: DVM requested.  
Imaging Performed by: Andi Parkinson, BS, RDMS.

**ULTRASONOGRAPHIC EXAMINATION OF THE ABDOMEN**

**Urinary System**

The **urinary bladder**, trigone, and pelvic urethra presented normal thicknesses and normal tone. The ureters were not visible which is normal. No uroliths or sediment were visualized, and anechoic urine was present. No evidence of inflammatory or neoplastic changes were noted. Ureteral papillae were normal.

The **kidneys** revealed normal size and structure, corticomedullary definition and ratio for this age. The cortices presented largely uniform texture with normal echogenic relationship to liver and spleen. Medullary structure differed distinctly from the cortex and no evidence of pelvic dilation was present. The capsules were acceptably uniform without significant irregularities. The left kidney measured 7.0 cm in length. The right kidney measured 6.44 cm in length.

**Adrenal Glands**

Both **adrenal glands** were visualized and recognized as having normal shape, size, position and echogenicity for this breed. The phrenic vasculature, glandular echogenicity and detail were unremarkable. Capsule, cortex, and medullary definition were normal for this age patient. The left adrenal gland measured 2.03 cm x 0.60 cm width at the cranial pole and 0.75 cm width at the caudal pole. The right adrenal gland measured 2.42 cm x 0.71 cm width at the caudal pole and 0.83 cm width at the cranial pole.

**Spleen**

The **spleen** presented a smooth homogeneous parenchyma hyperechoic to liver and renal cortical parenchyma. The capsule was smooth without noticeable expansion or deviation from within the spleen or adjacent pathology. The splenic vasculature demonstrated normal volume without signs of congestion or thrombosis. No sonographic evidence of acute or chronic inflammatory, neoplastic, or infarctual changes were noted.

**Liver**

The **liver** images submitted revealed subjectively normal liver size, contour, and structure. Parenchymal echogenicity was naturally coarse and hypoechoic to the spleen. Vascular and biliary tracts were of normal volume with no evidence of congestion. The gallbladder presented acceptably thin walls with primarily

anechoic content. The cystic and common bile ducts were normal. No pathological hepatic lymphadenopathy was evident. No overt structural evidence of inflammatory, infiltrative or regenerative pathology was evident.

### ***Gastrointestinal***

The **gastrointestinal tract** revealed a linear foreign body initiating in the pylorus with gastric stasis continuing into the small intestine. The colon was unremarkable. No free fluid was noted at the time of the sonogram, however, the foreign body is fixed in the pylorus and with accordion pleating in the distal small intestine.

### ***Pancreas***

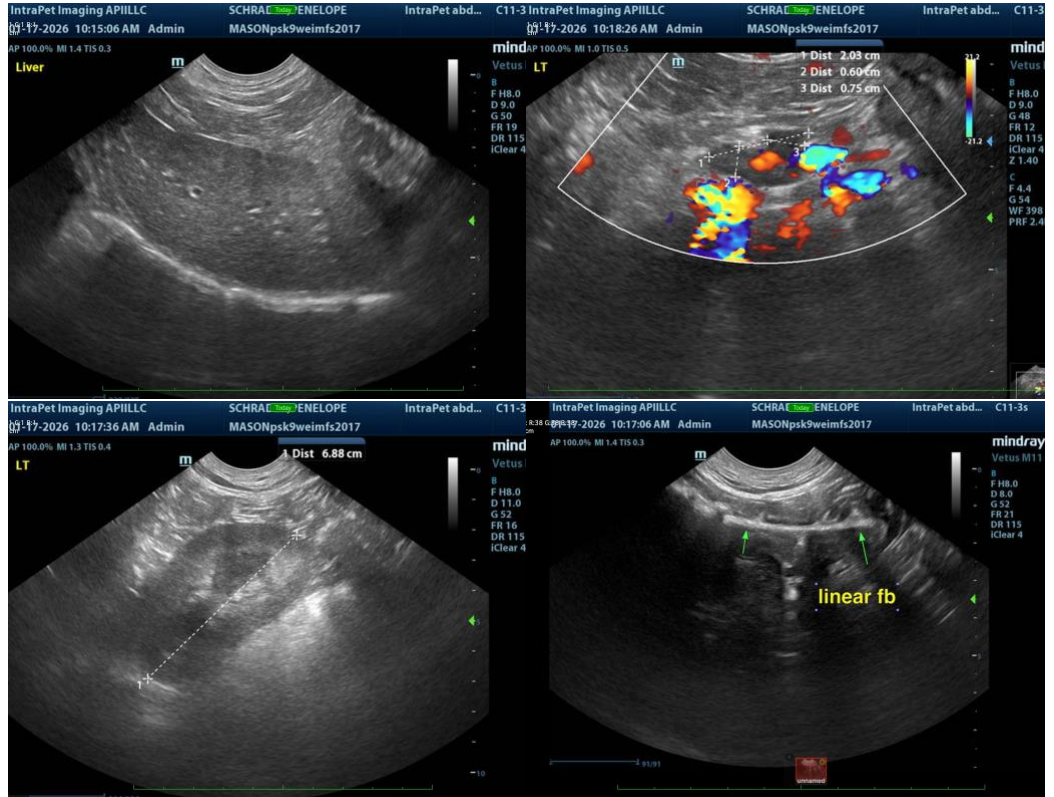
The base and limbs of the **pancreas** were observed to be largely isoechoic to surrounding omental fat. Pancreatic duct and capsular contour were acceptably normal and parenchyma respected normal curvilinear patterns. No overt evidence of active inflammatory or neoplastic disease was noted.

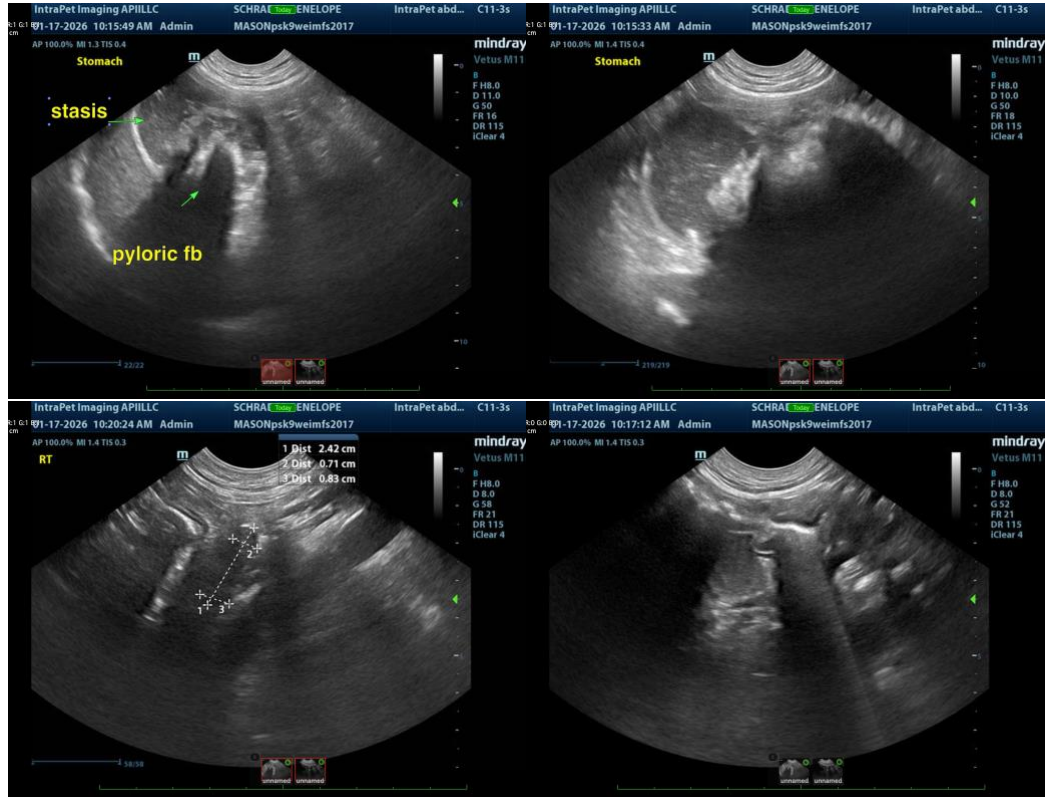
### **ULTRASONOGRAPHIC FINDINGS**

- Gastrointestinal linear foreign body with accordion pleating.

### **INTERPRETATION OF THE FINDINGS & FURTHER RECOMMENDATIONS**

Immediate exploratory surgery is indicated with gastrotomy/enterotomy and GI biopsies to rule out underlying disease.





The information and recommendations provided are based on the images presented by the referring veterinarian/sonographer. No evaluation can be communicated regarding pathology that was not visible in the image/video clips provided.

Thank you for this referral. If the clinical or image interpretation does not parallel your findings or if I can be of any further assistance, please contact me.

Eric Lindquist, DMV, DABVP(CFM), Cert. IVUSS,

CEO, Owner, Founder -- SonoPath.com

[info@SonoPath.com](mailto:info@SonoPath.com)