

**PATIENT**

Bobo Spear

**SPECIES**

Canine

**BREED**

Beagle

**SEX**

Neutered Male

**AGE**

12 Years 5 Months

**WEIGHT**

51.2 Pounds

**INTERPRETED BY**

Eric Lindquist, DMV,  
 DABVP (Canine & Feline), Cert. IVUSS

**IMAGING PERFORMED BY**

Kathleen Byrnes

**HOSPITAL NAME**

AH of Boone

**REFERRING VET**

Dr. Watson

**INVOICE**

35475

**DATE**

1/17/26

**PRESENTING CLINICAL SIGNS**

History: P presented for thyroid US due to history of PU/PD and a 1 cm nodule felt on the right side of neck. LDDST came back could be supportive of Cushing's dz. rdvm concerned for parathyroid nodule.

**ULTRASONOGRAPHIC EXAMINATION OF THE THYROID**

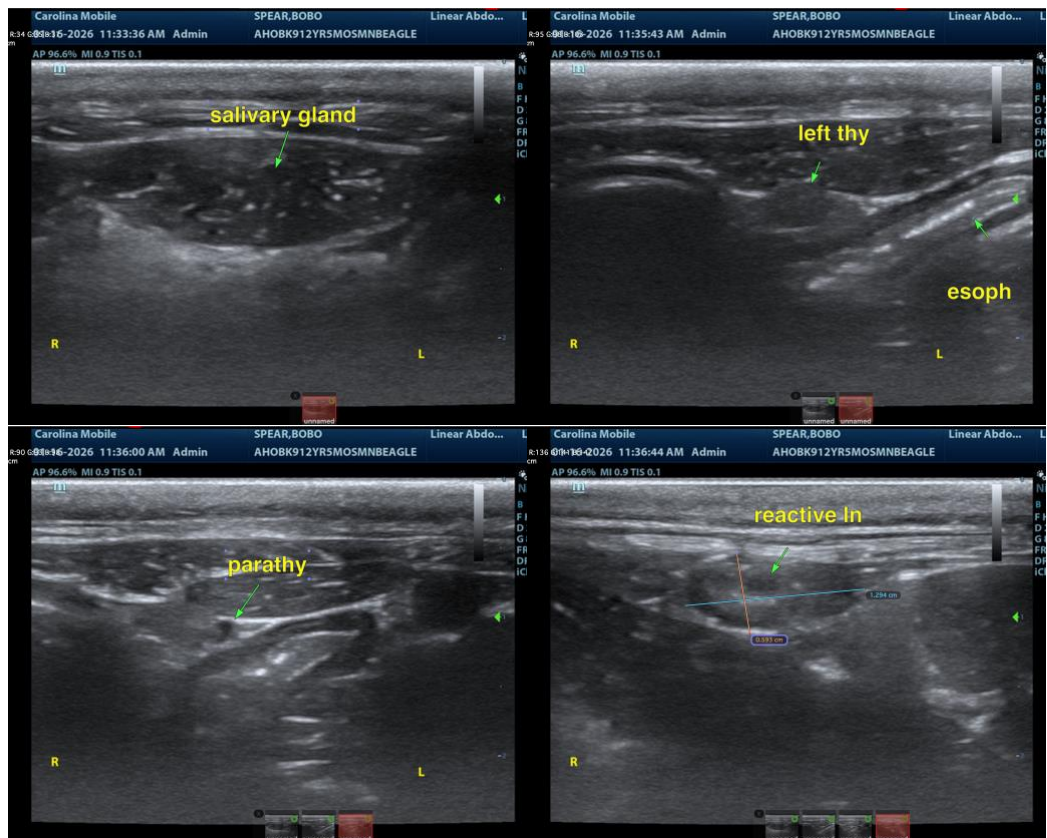
The thyroid and parathyroid, and salivary glands were all imaged, as well as the trachea and esophagus in this patient. None of which presented any pathology. Uniform parenchyma was noted. The region of the right thyroid lobe revealed right retropharyngeal lymph node enlargement, measuring 1.3 cm x 0.6 cm, consistent with reactive lymph node and potential for low grade chronic lymphadenitis. Length to width ratio was maintained. The left and right thyroid lobes were unremarkable, measuring approximately 6.0 mm in width. The visible parathyroids were unremarkable.

**ULTRASONOGRAPHIC FINDINGS**

- Right retropharyngeal lymph node enlargement, reactive pattern.

**INTERPRETATION OF THE FINDINGS & FURTHER RECOMMENDATIONS**

No other evidence of pathology.





**PATIENT**

Bobo Spear

**SPECIES**

Canine

**BREED**

Beagle

**SEX**

Neutered Male

**AGE**

12 Years 5 Months

**WEIGHT**

51.2 Pounds

**INTERPRETED BY**

Eric Lindquist, DMV,  
DABVP (Canine &  
Feline), Cert. IVUSS

**IMAGING  
PERFORMED BY**

Kathleen Byrnes

**HOSPITAL NAME**

AH of Boone

**REFERRING VET**

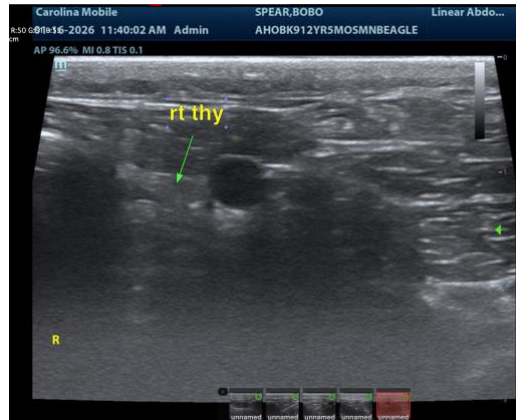
Dr. Watson

**INVOICE**

35475

**DATE**

1/17/26



**The information and recommendations provided are based on the images presented by the referring veterinarian/sonographer. No evaluation can be communicated regarding pathology that was not visible in the image/video clips provided.**

Thank you for this referral. If the clinical or image interpretation does not parallel your findings or if I can be of any further assistance please contact me.

**Eric Lindquist**, DMV, DABVP, Cert. IVUSS, CEO of SonoPath.com

[info@SonoPath.com](mailto:info@SonoPath.com)