



**PATIENT**

Winston Gomes

**PRESENTING CLINICAL SIGNS**

History: no clinical symptoms . elevated alp - 616 with concentrated urine (1.045) .p is on zonoisamid due to seizures.

**SPECIES**

Canine

**ULTRASONOGRAPHIC EXAMINATION OF THE ABDOMEN**

**Urinary System**

**BREED**

Boston Terrier

The **urinary bladder**, trigone, and pelvic urethra presented normal thicknesses and normal tone. The ureters were not visible which is normal. No uroliths or sediment were visualized and anechoic urine was present. No evidence of inflammatory or neoplastic changes was noted. Ureteral papillae were normal.

**SEX**

Neutered male

The prostate was slightly heterogenous and mildly enlarged at 1.9 cm in width.

**AGE**

8 years

The **kidneys** revealed largely normal size and structure, corticomedullary definition and ratio (cortex 1/3 of medulla) were essentially maintained with some age-related loss of curvilinear patterns regarding the capsule and C/M junction. The cortices presented largely uniform texture with some increased echogenicity expected for his age patient. Medullary structure differed distinctly from that of the cortex and no evidence of pelvic dilation was present. The kidneys each measured 4.0 cm.

**WEIGHT**

28 lbs

**Adrenal Glands**

The **adrenal glands** were not visualized.

**INTERPRETED BY**

Eric Lindquist, DMV  
DABVP, Cert. IVUSS

**Spleen**

The **spleen** presented a smooth homogeneous parenchyma hyperechoic to liver and renal cortical parenchyma. The capsule was smooth without noticeable expansion or deviation from within the spleen or adjacent pathology. The splenic vasculature demonstrated normal volume without signs of congestion or thrombosis. No sonographic evidence of acute or chronic inflammatory, neoplastic, or infarctual changes was noted.

**IMAGING PERFORMED BY**

Dr. Han

**HOSPITAL NAME**

Tenafly VC

**Liver**

The **liver** presented heterogenous parenchyma with increased portal markings and coarse architecture. Slight undulating capsular contour was noted. The gallbladder and common bile duct were unremarkable. This is consistent with chronic inflammatory hepatopathy.

**REFERRING VET**

Dr. Han

**Gastrointestinal**

**INVOICE**

42202

A minor amount of non-shadowing, non-obstructive ingesta was noted in the stomach. Transit of chyme into the small intestine was normal. Curvilinear patterns were maintained throughout the GI tract. No evidence of pathology. Small and large intestine demonstrated normal luminal chyme and stool consistency respectively. No obstructive or overt infiltrative disease was noted. No associated abnormal lymphatic activity was noted.

**DATE**

1/17/23



**PATIENT**

Winston Gomes

**SPECIES**

Canine

**BREED**

Boston Terrier

**SEX**

Neutered male

**AGE**

8 years

**WEIGHT**

28 lbs

**INTERPRETED BY**

Eric Lindquist, DMV  
DABVP, Cert. IVUSS

**IMAGING PERFORMED BY**

Dr. Han

**HOSPITAL NAME**

Tenafly VC

**REFERRING VET**

Dr. Han

**INVOICE**

42202

**DATE**

1/17/23

**Pancreas**

The base and limbs of the **pancreas** were observed to be largely isoechoic to surrounding omental fat. Pancreatic duct and capsular contour were acceptably normal and parenchyma respected normal curvilinear patterns. No overt evidence of active inflammatory or neoplastic disease was noted.

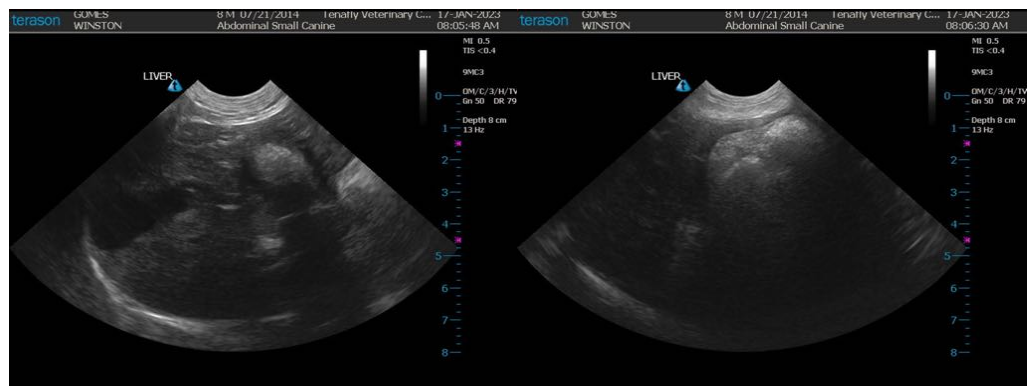
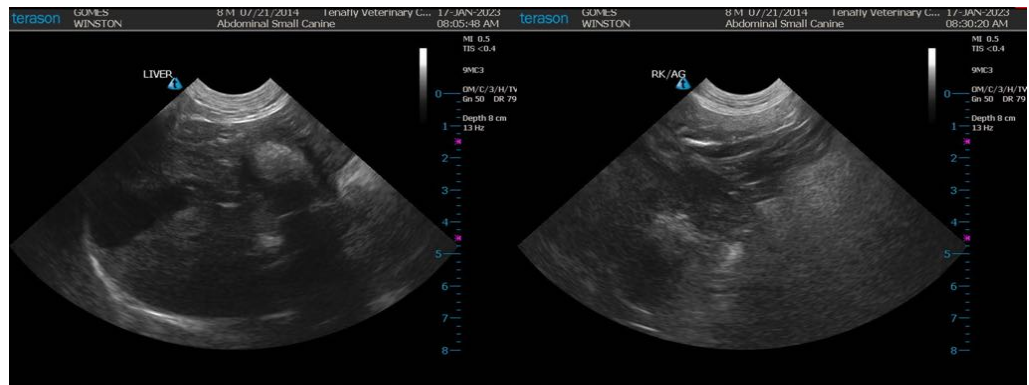
**ULTRASONOGRAPHIC FINDINGS**

Geriatric abdomen with hepatic remodeling.

Slightly enlarged prostate.

**INTERPRETATION OF THE FINDINGS & FURTHER RECOMMENDATIONS**

Bile acid profile is indicated given the patient's history. If any straining to urinate is present then FNA is indicated. There is no overt evidence of retained testicle.





**PATIENT**

Winston Gomes

**SPECIES**

Canine

**BREED**

Boston Terrier

**SEX**

Neutered male

**AGE**

8 years

**WEIGHT**

28 lbs

**INTERPRETED BY**

Eric Lindquist, DMV  
DABVP, Cert. IVUSS

**IMAGING PERFORMED BY**

Dr. Han

**HOSPITAL NAME**

Tenafly VC

**REFERRING VET**

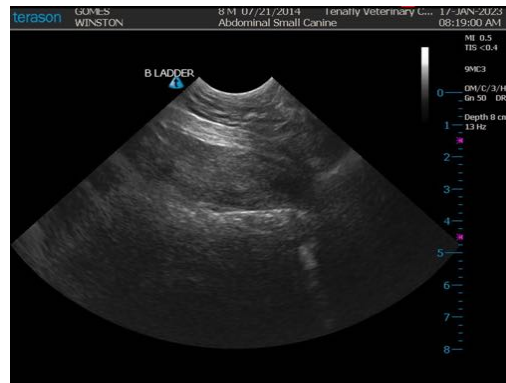
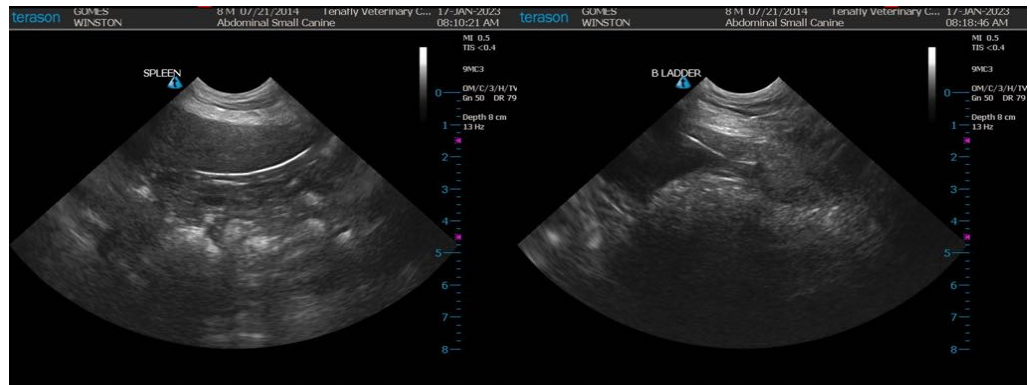
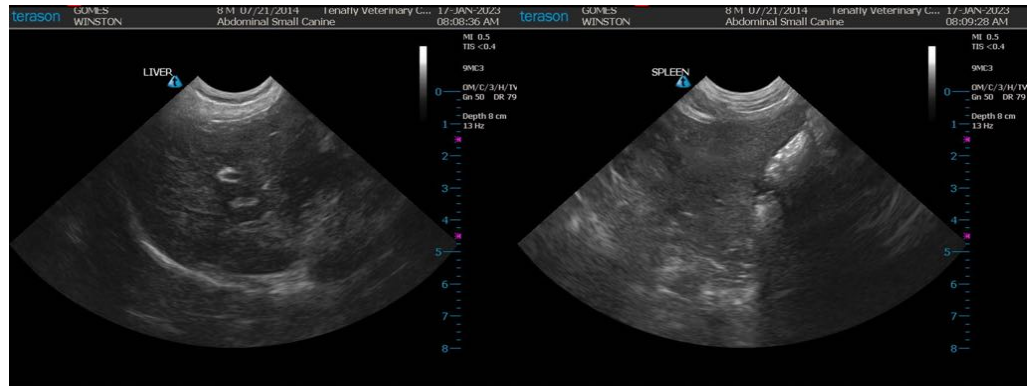
Dr. Han

**INVOICE**

42202

**DATE**

1/17/23



The information and recommendations provided are based on the images presented by the referring veterinarian/sonographer. No evaluation can be communicated regarding pathology that was not visible in the image/video clips provided.

Thank you for this referral. If the clinical or image interpretation does not parallel your findings or if I can be of any further assistance please contact me.

**Eric Lindquist, DMV, DABVP, Cert. IVUSS, CEO of SonoPath.com**  
info@SonoPath.com